



## Ultrasound Assessment of Normal Portal Vein Diameter in Ethiopians Done at Tikur Anbessa Specialized Hospital.

Y. Hawaz, D. Admassie, T. Kebede

Department of Radiology, School of Medicine, Addis Ababa University (AAU) – Ethiopia.

**Correspondence to:** Dr. Yohannes Hawaz, Email: <yhawaz@yahoo.com>

**Background:** Portal hypertension occurs when the portal venous pressure exceeds 10mm Hg. Whatever the primary cause, the consequences of portal hypertension are similar. Liver cirrhosis is the commonest cause of portal hypertension. Because of its accessibility, lack of ionizing radiation and rapid assessment, sonography plays a major role in the assessment of portal hypertension. Even if the additional use of color and spectral Doppler improves the assessment of patients suspected of having portal hypertension, gray scale assessment of portal vein diameter is corner stone in the initial evaluation. Knowing the normal portal venous dimension in a specified population is so crucial.

**Methods:** This is a prospective cross-sectional study done at Tikur Anbessa Specialized Hospital to sonographically determine the normal portal vein diameter. Data was collected from 502 patients on consecutive bases from May – September 2010. This includes 190 males and 312 females.

**Results:** The mean portal vein diameter was  $7.9 \pm 2\text{mm}$  with an increase in diameter with increase in age of the subject. Our study also revealed 21.5% increase in portal vein diameter with the phases of inspiration.

**Conclusion:** This study has comparable results with studies done elsewhere so that it can be used as a baseline for future population based studies and clinical decision making.

### Introduction

Portal hypertension is defined as an increase in portal venous pressure which results in impendence of blood flow through the vein into the hepatic circulation. It exists when the portal venous pressure is above 10mmHg or the hepatic venous gradient is more than 5 mmHg<sup>1</sup>. Subsequently there is development of portosystemic collateral shunts which diverts blood away from the liver. Cirrhosis is the most common cause of portal hypertension but it can also be present in the absence of cirrhosis, a condition referred to as "noncirrhotic portal hypertension". As a general rule, the clinical consequences of portal hypertension are similar regardless of the cause or site of obstruction; these are the formation of gastro-esophageal varices, ascites, and splenomegaly.

Sonography, in addition of being nonionizing, its accessibility, noninvasiveness, portable nature, reliability, low cost and also its ability of rapidly accomplishment<sup>2</sup>, makes it a good diagnostic tool which plays a great role in the diagnosis and follow up of patients with portal HTN. It can also suggest the possible cause too. Even if duplex sonography assessment of the portal vein has the added advantage of assessing also the flow rate<sup>3,4</sup>, gray scale measurement of the portal vein diameter is the corner stone and also has a reasonable accuracy in diagnosing patients suspected of having portal hypertension<sup>5,6</sup>. In countries like ours where there is no local standards for most of the measurements made during sonography, this will serve as a baseline for local reference use of portal vein diameter measurement. Dilatation of portal vein or increase in diameter of portal vein was also the only criteria by gray scale ultrasound to detect portal hypertension but it was found to be less sensitive and specific than diagnosis of portal hypertension by caliber change with respiration<sup>7</sup>.

### Subjects and Methods

A cross-sectional prospective study conducted in Tikur Anbessa Specialized Hospital, Addis Ababa, from May- Sept 2010. The study subjects were all Ethiopian patients with no age restriction who came to the radiology department of the hospital. Data was collected by consecutive method during

the period allocated. Source populations included all patients who were sent to the department of radiology for abdominal ultrasound examinations during the study period (May- Sept 2010). Patients who had fasted for at least six hours and those who were cooperative were included in the study. Patients having the clinical diagnosis or sonographic features suggesting of presence of hepatobiliary disease, those having hepatobiliary surgery or recent surgery for other reasons were excluded from the study. This includes a total of 502 study subjects.

A radiologist obtained measurements using an Aloka SSD 3.5MHZ convex probe. Before specific measurement of the portal vein diameter was performed, routine scanning was done to check for the sonographic exclusion criterias. The patient was scanned in supine and right anterior oblique position with the transducer in the oblique position in the RUQ of the abdomen. Measurement of the portal vein diameter was taken in quiet respiration at the hilum of the liver just before bifurcation into right and left. The diameter was taken by putting the two cursors in the internal wall of the portal vein; the wall of the portal vein was excluded from the measurement. Supervision was made during the data collection by the principal investigators to assure the data quality.

We first did a routine scan of the patient and if no exclusion criteria we took the portal vein measurement. The collected data were checked for completeness and cleaned. Statistical Package for Social Sciences for window (SPSS) version 16 was used to enter and analyze the data. The mean portal vein diameter was calculated and the portal vein diameter was cross tabulated with the age of the patient.

Permission to conduct the research was given from the department of radiology. Code number rather than patients name was used for data collection. Patients were scanned to get the routine sonographic examination service, and as part of the scanning process portal vein measurements were made.

## Results

A total of 502 patients were included in the study and out of these 312 (62.2%) were females and the rest 190 (37.8%) were males. Patients' ages ranged between 5 to 85years with a mean of  $39.6 \pm 1.5$  years. The mean portal vein diameter during quiet respiration was  $7.9 \pm 2$ mm. The mean increase in diameter with inspiration being 21.5% (Table 2). The difference in the mean diameter in males and females is not statistically significant. The mean portal vein diameter increases with the age of the patient (Figure 1)

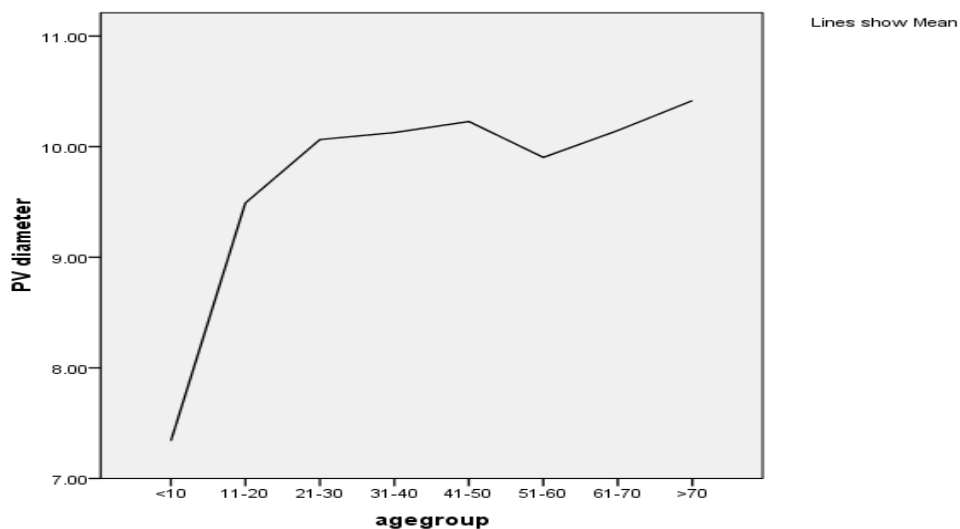


Figure 1. Mean Portal Vein Diameter vs Age of Study Subjects

**Table 1.** Age distribution of study subjects

		Frequency	Percent
Valid	<10	5	1.0
	11-20	39	7.8
	21-30	126	25.1
	31-40	129	25.7
	41-50	80	15.9
	51-60	78	15.5
	61-70	33	6.6
	>70	12	2.4
	Total	502	100.0

**Table 2:** Mean Portal Vein Diameter in Females and Males

Sex	No	Mean diameter	Mean increase in diameter during inspiration
Females	312	9.8cm	22.6%
Males	190	10.4cm	19.8%

### Discussion

Real time sonography is the most accurate and reliable method of assessing the portal vein diameter. With the introduction of color duplex imaging less emphasis was given on the gray scale PV diameter measurement. Even those earlier studies which dealt with PV diameter measurements come out with variable values<sup>7,8,9</sup> which necessitate the need for establishing a local standard values.

Our study revealed the mean portal vein diameter in our setting to be 10.0±1.8cm (range 8.2 to 11.8) with a 21.5% reduction with the phases of respiration. Since portal vein diameter measurement has different values and among different age groups too<sup>10,11</sup>, values which are done in local settings should be taken. Normally the PV diameter increases with inspiration. The increase in diameter in most studies is more than 20 %<sup>12,13,14</sup> also true in this study. With the development of portal HTN there is a progressive loss of variation with phases of respiration. The accuracy of diagnosing portal HTN if the increase in diameter is less than 20 % is 90%<sup>14</sup>.

This should also be utilized rather than using only an absolute diameter measurement because in the late phases of the portal hypertension, the diameter measurement may not be reliable due to the development of porto-systemic shunts which deflates the pressure in the portal vein. Even if there is an increase in size of the portal vein diameter with that of age<sup>15</sup> which is also true in this study, no statistically significant difference is seen in ours and in most other studies<sup>15,16</sup>.

This study, being the first of its type in the country, shows that the mean portal vein diameter in Ethiopian population to be comparable with other countries, but other population based studies should follow to determine the cut off value of the portal vein diameter to define portal hypertension.

## References

1. Hg (Ong JP, Sands M, Younossi ZM: Transjugular intrahepatic portosystemic shunts (TIPSS) a decade later. *J Clin Gastroenterol* 2000;30(1):14–28.
2. Meire EB, Dewbury KC, Cosgrove DO. Abdominal and General Ultrasound. Churchill Livingstone. Edinburgh. 1993: 1:311
3. D, Meire H, Dewbury K. Churchill Livingstone. Edinburgh. 1993: 1:311. Lotz R, Mildenerger P, Kreitner KF, Rambow A, Schiedermeier P, Staritz M. Duplex sonography of the portal vein. Procedure in healthy probands and patients with portal hypertension *Fortschr Med.* 1989, 20; 107(15):330-4.
4. Lomas D.J., Britton P.D., Summerton C.B. and Seymour C.A. Duplex Doppler measurements of the portal vein in portal hypertension *Clinical Radiology* Volume 48, Issue 5, November 1993, Pages 311-315 )
5. Goyal A. K., Pkharma D. S. and, Sharma S. K. Ultrasonic measurements of portal vasculature in diagnosis of portal hypertension. A controversial subject reviewed. *Journal of Ultrasound in Medicine*, 1990, Vol 9, Issue 1 45-48,
6. William G. Rector Jr., Jose C., Philip W. R, Matthew C. Utility and limitations of splanchnic venous ultrasonography in diagnosis of portal hypertension. *Journal of Clinical Ultrasound*, 1986 Volume 14, Issue 9, 689–696,
7. Bolondi L, Gandolfi L, Arienti V, et al. Ultrasonography in the diagnosis of portal hypertension: diminished response of portal vessels to respiration. *Radiology* 1982;142, 167-172.
8. Webb LJ, Berger LA, Sherlock S. Grey scale ultrasound of portal vein. *Lancet*, 1979; 2: 675-677.
9. Strohm VWD, Wher B. Korrelation zwischen Lebervenenverschlyubfrick und sonographisch bestimmtem Durchmesser von Pfortader und Milz bei Leberkranken. *Z Gastroentero!* 1979; 1 7:695-703
10. Scabel SI, Ritternberg GM, Javid LH, Cunningham J, Ross P. The bull's eye falciform ligament: a sonographic finding of portal hypertension. *Radiology.*1980; 136: 159-169.
11. Rumack CM, Wilson SR, Charboneau J: *Diagnostic Ultrasound*. 2nd ed. St. Louis, MO, Mosby Year Book, 1998.
12. Zwiebel WJ: Sonographic diagnosis of hepatic vascular disorders. *Semin Ultrasound CT MRI* 1995;16(1):34–48.
13. Al-Nakshabandi NA. The role of ultrasonography in portal hypertension. *Saudi J Gastroenterol* 2006;12:111-7
14. Bolondi L, Mazzotti A, Arienti V, et al. Ultrasonographic study of portal venous system in portal hypertension and after portosystemic shunt operations. *Surgery* 1984;95:261-9.
15. Anakwue AC, Anakwue RC, Ugwu AC, et al. Sonographic evaluation of normal portal Vein diameter in Nigerians. *European journal of scientific research.* 2009; 36 (1): 114-117.
16. Jeffrey Weinreb, Sheila Kumari, Gail Phillips, Rubem Pochaczsky. Portal vein measurements by real-time sonography. *AJR* 1982,139:497-49.