

Clinical Presentation and Diagnosis of Non-traumatic Sub-arachnoid Haemorrhage among Patients Treated at Kenyatta National Referral Hospital, Kenya.

V.D. Wekesa, N.J.M. Mwang'ombe, C.K. Musau, J.G. Kiboi
Neurological Unit, Department of surgery, University of Nairobi.
Corresponding to: V.D. Wekesa, Email: vwekesa09@gmail.com

Background: Subarachnoid haemorrhage (SAH) is a grave condition with high morbidity and mortality. This condition may easily be confused with other clinical conditions such as bacterial or viral meningitis. Diagnosis to date has depended on high index of suspicion. Misdiagnosis of SAH does not only delay definitive diagnosis, but it may be fatal due to complications like re-bleeding or vasospasm. This study was designed to describe the pattern of non-traumatic subarachnoid hemorrhage (SAH) at the Kenyatta National hospital (KNH).

Methods: A cross sectional analysis of consecutive patients who had SAH and admitted at the KNH between December 2010 and March 2011 was performed. A total of 55 patients with SAH were recruited in the study, with a male: female ratio of 1: 1.1.

Results: Headache was the commonest symptom (91%) in patients with SAH. Facial nerve palsy was the commonest of the cranial nerve palsies (75%) observed in these patients. Fifty one percent (51%) of the patients were known hypertensives prior to the SAH episode. Sixty six percent (66%) of patients presented with Glasgow Coma Scale (GCS) between 7 and 14. Thirty eight percent (38%) presented in World Federation of Neurosurgeons (WFNS) grade 1.

Conclusion: Non-contrast CT-scan was the investigation of choice for acute SAH. However in the absence of CT-scan, and where there was a strong clinical suspicion of SAH, lumbar puncture was a reliable test.

Introduction

Subarachnoid hemorrhage (SAH) is the extravasation of blood into the subarachnoid space¹. It is a devastating condition with high morbidity and mortality. This disorder is also associated with a significant burden on health care resources, mainly due to hospitalization². SAH, mainly aneurysmal, accounts for 3% of all strokes³. It contributes to about 5% of all stroke deaths and to over 25% of potential life years lost through stroke⁴. Great advances in the diagnosis of SAH were made in the twentieth century⁵. Advances in treatment and prevention of complications, however, have only resulted in modest improvement in overall outcome⁶. Non-aneurysmal SAH including the isolated perimesencephalic SAH occurs in about 20% of cases and carries a good prognosis with uncommon neurologic complications⁷. Diagnosis to date rests on high index of suspicion, as this condition can easily be confused with other clinical conditions such as bacterial or viral meningitis. This misdiagnosis will not only delay definitive diagnosis, but it may be fatal due to complications like re-bleeding or vasospasm.

This study was aimed at bringing out common and/or rare clinical patterns of presentation of patients with SAH. Describing the burden of disease and related patient variables in our set-up will provide useful data for other entry points into studying this condition. In describing associated risk factors such as smoking, alcohol, hypertension and familial predisposition, among others, clinicians will be armed with useful information in helping control the burden of disease.

Patients and Methods

This descriptive cross sectional study was conducted at Kenyatta National Teaching and Referral Hospital in Nairobi, Kenya between December 2010 and March 2011. The hospital has a well established neurosurgery unit under the departments of surgery and a neurology section within the department of medicine. The study population included patients admitted with confirmed diagnosis of non traumatic SAH, and had given a written informed consent. Data on causes, pattern, and socio-demographic characteristics was collected using

a questionnaire administered to patients who met the inclusion criteria. Data collected was entered and analyzed using Statistical Package for Social Sciences (SPSS) for Windows® version 16.0. Approval for the study was granted by University of Nairobi/ Kenyatta National Hospital Research and Ethics Committee.

Results

Clinical presentation

The commonest clinical presentation of patients with SAH was headache (91%) of which 67% were of sudden onset.

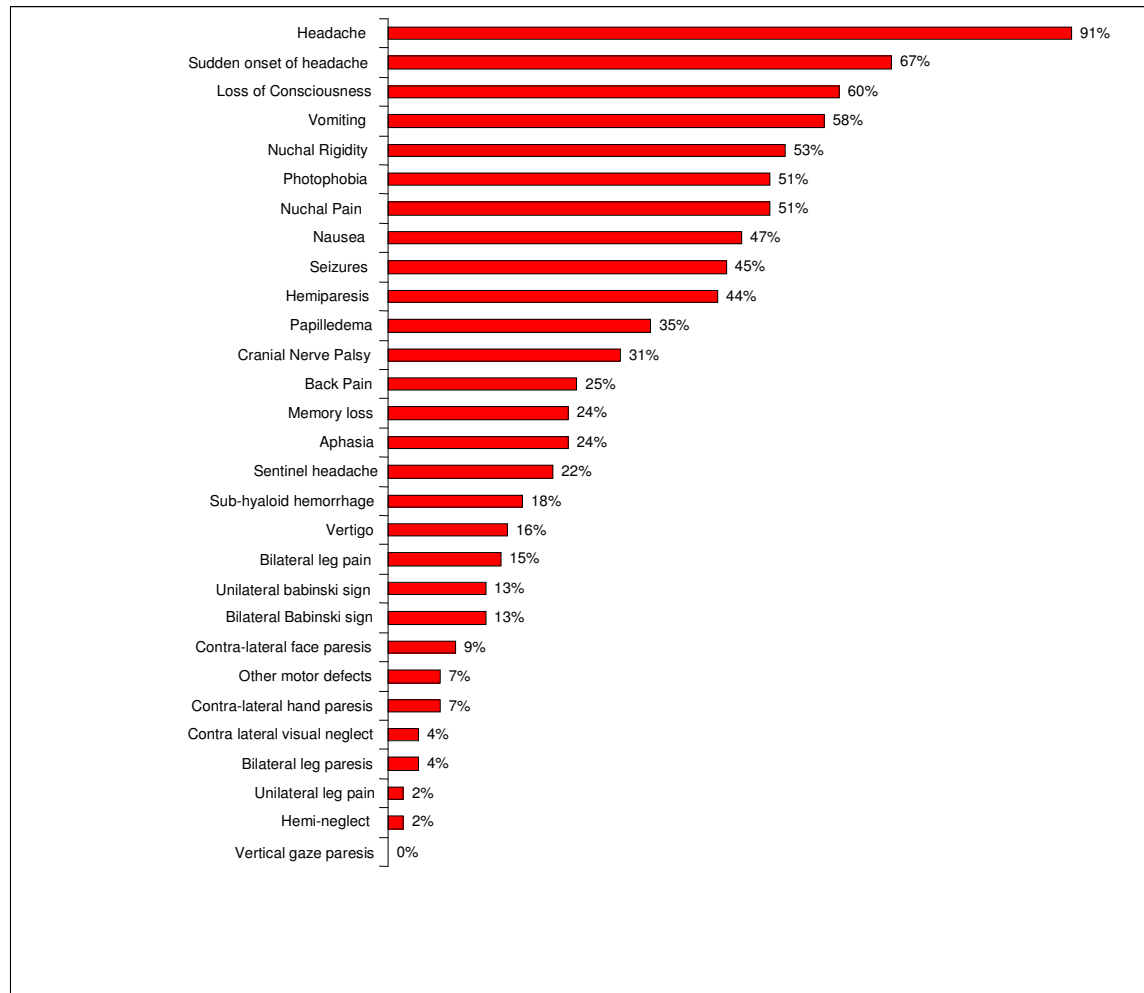


Figure 1. Bar graphs showing clinical presentation of patients with SAH

Loss of consciousness and vomiting were seen in 60% and 58% respectively (Figure 1). Other notable presenting complaints were nuchal rigidity (53%), photophobia (51%), nuchal pain (51%), nausea (47%), seizures (45%) and hemiparesis (44%). Contra-lateral visual neglect (4%), bilateral leg paresis (4%), unilateral leg pain (4%) and hemi-neglect (2%) were relatively uncommon forms of presentation. Vertical gaze paresis was however not seen in any patient. Hydrocephalus was seen as a co-existing condition in 13 % of patients in this study. Vertical gaze paresis was however not seen in any patient. Hydrocephalus was seen as a co-existing condition in 13 % of patients in this study. Cranial nerve palsy was seen in 16 (31%) of patients. Out of these 12 (75%) had seventh nerve palsy.

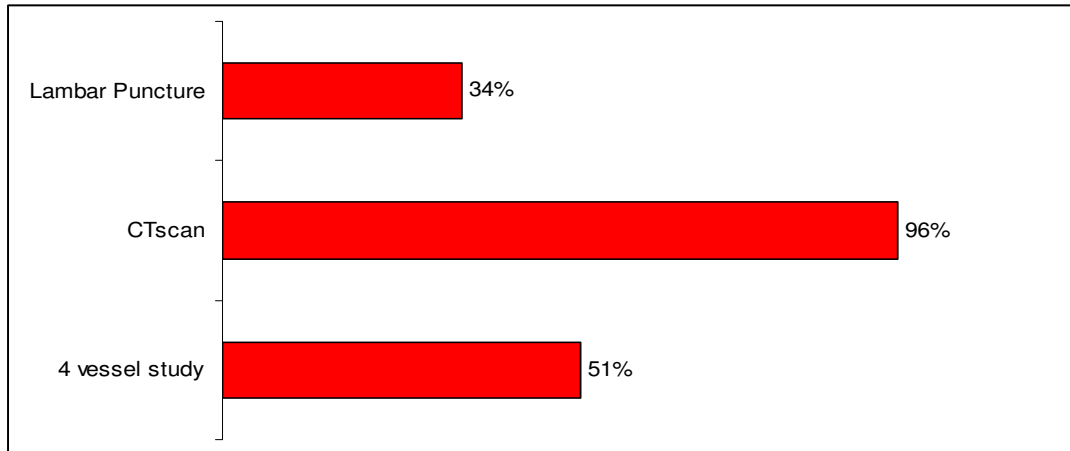


Figure 2. Investigations done on patients with SAH

Table 1. WFNS grading of patients admitted with SAH

	Number of patients	Percentage of patients
Grade 1	21	38%
Grade 2	6	11%
Grade 3	10	18%
Grade 4	13	24%
Grade 5	5	9%
Total	55	100%

Table 2. Fisher Grading Findings with the SAH Patients

	Number of patients	Percentage of patients
Grade 1	6	11%
Grade 2	14	25%
Grade 3	12	22%
Grade 4	23	42%
Total	55	100%

Table 3. GCS Grading Finding of the Patients with SAH

GCS score	Number of patients	Percentage of patients
15	16	29%
13-14	18	33%
7-12	18	33%
3-6	3	5%
Total	55	100%

Second, third, sixth and twelfth nerve palsies were only seen in 1 (6%) patient each. The majority of the SAH patients had a CT scan (96%) performed as a baseline investigation. Four vessel studies were done in 51% and 34% had lumbar punctures (Figure 2).

Grading of patients

Patients were graded according to the WFNS, Fisher and GCS scales. The results are shown on Tables 1, 2 and 3 respectively

Discussion

SAH is a devastating clinical condition with high morbidity and mortality. This study was designed with the aim of identifying important clinical characteristics and pattern of presentation, among patients with SAH admitted at the KNH. The commonest clinical presentation was headache, accounting for 91% of cases. Sixteen seven percent (67%) of patients described the headache as being of sudden onset. Twenty two percent (22%) of patients reported a history of sentinel headache. This findings contrast with the findings of Kumar et al⁸, who reported severe headache as accounting for 75% of cases. In his series, 56% of patients reported the headache as being of sudden onset. Jurgen et al⁹, reported sentinel headaches in 17.3% of patients in his series, which contrasts with the 22% observed in this study. Landtblom et al¹⁰ in his study only noted 4% of patients depicting true sentinel headache.

Loss of consciousness and vomiting were seen in 60% and 58% of patients respectively. Other notable presenting complaints included nuchal rigidity (53%), photophobia (51%), nuchal pain (51%), Seizures (45%), and hemiparesis (44%). Landtblom et al¹⁰ reported neck stiffness in 61% of patients, loss of consciousness in 17% of patients, this showed some contrast in the pattern of clinical presentation with the findings in our study. Hydrocephalus was noted in 13% of patients compared to 26% reported in a study by Martinez-Manas et al¹⁶. This finding is however in conformity with the documented findings of post SAH hydrocephalus, where the incidence ranges from 6% to 67%¹¹. Epileptic seizures were noted in 45% of cases, compared to 6-16% of cases in similar studies^{12,13,14}. Kyu-sun et al¹⁵ reported 15.2% of patients with seizures following SAH in his study.

Physical examination in SAH usually may reveal localizing signs which include the third nerve palsy or the sixth nerve palsy. In this series, 29% of patients had cranial nerve palsy, this is in contrast to a study by Albrecht et al¹⁶ in which 10% of patients had cranial nerve palsy. The commonest cranial nerve palsy in this series was the facial nerve palsy. This contrasted to the finding of Albrecht et al¹⁶, where oculomotor nerve palsy was the commonest.

Patients with SAH are usually on various medications depending on associated co-morbidities and/or risk factors to SAH. In this study, a clear majority of patients were on nimodipine, however, 29% of patients were not on any medications at the time of recruitment into the study. These were mainly WFNS grade 1 patients seen in A/E as referrals from satellite hospitals prior to initiation of treatment. Others had completed treatment for the previously misdiagnosed clinical condition, mostly bacterial meningitis.

In this study, 96% of patients had CT scan done on them, which was 100% diagnostic of SAH, 34% of patients had LP done on them, and was equally 100% diagnostic of SAH. Patients who had LP, were mainly patients who did not afford CT scan at admission, or had the procedure done at the referring health facility. Those who had positive CT scan findings did not have LP done them. A 4-vessel angiographic study was done which depicted aneurysms in 29% of patients, while AVMs were noted in 4% of patients.

Head CT scanning should be the first study performed in any patient with suspected SAH. The characteristic appearance of extravasated blood is hyper dense. All scans should be performed with thin cuts through the

base of the brain¹⁷. A good-quality head CT scan will reveal SAH in 100 percent of cases within 12 hours after the onset of symptoms and in more than 93 percent of cases within 24 hours¹⁸. Head CT scans also demonstrate intra-parenchymal hematomas, hydrocephalus and cerebral edema and can help predict the site of aneurysm rupture, particularly in patients with aneurysms in the anterior cerebral or anterior communicating arteries¹⁹. Head CT is also the most reliable test for predicting cerebral vasospasm and poor outcome²⁰. Because of rapid clearance of blood, delayed head CT scans may be normal despite a suggestive history, and sensitivity drops to 50 percent at seven days²¹.

Lumbar puncture(LP), should be performed in any patient with suspected SAH and negative or equivocal results on head CT scanning. Cerebrospinal fluid should be collected in four consecutive tubes, with the red-cell count determined in tubes 1 and 4. Findings consistent with SAH include an elevated opening pressure, an elevated red-cell count that does not diminish from tube 1 to tube 4 and xanthochromia, which may require more than 12 hours to develop. It should, however, be noted that at lumbar puncture (LP), it may be difficult to differentiate a traumatic tap from SAH. Three tube clearing does not work²². It is best to just consider the last tube as the true cell count. In a study of thunder clap headaches with proven SAH, 1 in 5 had a negative CT with a positive LP²³. In patients with either equivocal or diagnostic lumbar puncture, an imaging study, such as CT angiography of the head or cerebral angiography should be the next step. CT angiography was not used in this study mainly on account of cost to the patient. This however, also helps establish the cause of the SAH. Digital-subtraction cerebral angiography (utilized in this study), has been the gold standard for the detection of cerebral aneurysms, but CT angiography has gained popularity and is frequently used owing to its noninvasiveness and a sensitivity and specificity comparable to that of cerebral angiography²⁴.

Conclusion

The most common presenting symptom of spontaneous SAH is headache. Sudden onset headache is the single most important clinical feature of SAH, although a history of sentinel headache is equally important. Non-contrast CT-scan is the investigation of choice in acute SAH. In the absence of CT-scan, however, and where there is a strong clinical suspicion of SAH, lumbar puncture is the most reliable test. Four-vessel angiography (DSA) remains the gold standard in detection of cerebral aneurysms, in cases of confirmed spontaneous SAH. In all instances however, a high index of suspicion coupled with a careful history and a focused clinical assessment form the cornerstones in the diagnosis of SAH.

References

1. Kirk Patrick PJ, Subarachnoid hemorrhage and aneurysms: What neurologists need to know? *J. Neurol Neurosurg Psychiatry* 2002; 73: 28-33.
2. Roos YB, Dijkgraaf MGW, Albrecht KW et al. Direct costs of modern treatment of aneurysmal subarachnoid hemorrhage. *Stroke* 2002; 33:1595-1599.
3. Sudlow CL, Warlow CP. Comparable studies of the incidence of stroke and its pathological types: results from an international collaboration. *Stroke* 1997; 28:491-499.
4. Johnston SC, Selvin S, Gress DR. The burden, trends and demographics of mortality from subarachnoid hemorrhage. *Neurology* 1998a; 50:1413-1418.
5. Cushing H, Symonds CP. Contributions to the clinical study of cerebral aneurysms. *Guy's Hosp. Rep* 1923; 73:139-163.
6. Hop JW, Rinkel GJ, Algra A, Van Gijn J. Case fatality rates and functional outcome after subarachnoid hemorrhage: a systemic review. *Stroke* 1997; 28:660-664.
7. Adams HP Jr, Gordon DL. Non-aneurysmal subarachnoid hemorrhage. *Ann Neurol.* 1991; 29: 461-462.
8. S. Kumar, Goddeau, Jr, M.H. Selim et al. A traumatic convexal SAH. *Neurology* 2010; 74: 893-899.
9. Jurgen B, Andreas R, Andrea S et al. Sentinel headache and the risk of re-bleeding after Subarachnoid hemorrhage. *Stroke* 2006.
10. Landtblom A.M, Fridriksson S, Borvie J. et al. Sudden onset headache. A prospective study of features, incidence and causes. *Cephalgia*, 2002; 354-360.

11. Vale FL, Bradley EL, Fisher WSIII. The relationship of SAH and the need for post-operative shunting. *J Neurosurg.* 1997;86(3):462-466.
12. Sarner M, Rose FC. Clinical presentation of ruptured intracranial aneurysm. *J Neurol. Neurosurg psychiatry* 1967, 30:67-70.
13. Hart RG, Byer JA, Slaughter JR, et al. Occurrence and implications of seizures in SAH due to ruptured intracranial aneurysms. *Neurosurgery* 1981; 8:417-21.
14. Pinto AN, Canhao P, Ferro JM. Seizures at the onset of SAH. *J Neurol.* 1996; 243:161-164.
15. Jurgen B, Andreas R, Andrea S et al. Sentinel headache and the risk of re-bleeding after Subarachnoid hemorrhage. *Stroke* 2006.
16. Kyu-Sun, Hyoung-Joon C, Hyeong-Joong et al. Seizures and Epilepsy following Aneurysmal Subarachnoid Hemorrhage: Incidence and risk factors. *J Korean Neurosurg* 2009; 46(2):93-98.
17. Latchaw RE, Silva P, Falcone SF. The role of computed tomography following aneurysmal rupture. *Neuroimaging Clin N Am* 1997; 7: 693-708.
18. Sarnes TA, Storrow AB, Finkelstein JA, Magoon MR. Sensitivity of new generation computed tomography in SAH. *Acad Emerg Med* 1996;3: 16-20.
19. Van der jagt M, Hasan D, Bijvoet HW et al. Validity of prediction of the site of ruptured intracranial aneurysms with CT. *Neurology* 199;52: 34-39.
20. Adams HP Jr, Kassell NF, Torner JC, Haley EC Jr. Predicting cerebral ischemia after aneurysmal SAH: influences of clinical condition. CT results and antifibrinolytic therapy: A report of the co-operative aneurysm study. *Neurology* 1987; 37: 1586-1591.
21. Bambakidis NC, Selman WR. Subarachnoid hemorrhage. In: Suarez JI ed. *Critical Care neurology and neurosurgery.* Totowa, N.J.: Humana press, 2004:365-377.
22. Cressler DH, Mona A. M, David MY. Clearing of red blood cells in lumbar puncture does not rule out ruptured aneurysm in patients with suspected subarachnoid hemorrhage but negative head CT findings. *American Journal of Neuroradiology* 2005; 26: 820- 824.
23. Landtblom AM, Fridriksson, Hillman J et. Al. Sudden onset headache: a prospective study of features, incidence and causes. *J Neur Neurosurg Psych.* 1981: 22: 354-360.
24. Jayaraman MV, Mayo-smith WW, Tung GA et al. Detection of intracranial aneurysms: multidetector row CT angiography compared with digital subtraction angiography (DSA). *Radiology* 2004; 230:510-518.