

---

**Cerebral hydatidosis, a rare clinical entity in Ethiopian teaching hospitals: case series and literature review.**

G. Assefa<sup>1</sup>, H. Biluts<sup>2</sup>, M. Abebe<sup>2</sup>, M.H. Birahanu<sup>2</sup>

<sup>1</sup>Department of Radiology, <sup>2</sup>Department of Neurosurgery,  
Faculty of Medicine, Addis Ababa University, Ethiopia

**Correspondence to:** Getachew Assefa, MD. Department of Radiology, FOM, AAU, P.O.Box 9086, Addis Ababa, E-mail [g\\_asefa@yahoo.com](mailto:g_asefa@yahoo.com)

**Background:** Cerebral hydatidosis (CH) is a rare disease and unlike other body organs cerebral involvement is very uncommon and if it occurred it is often seen in pediatric patients. The aim of the study is to show the clinical and imaging features and neurosurgical outcome of CH in East African setup.

**Methods:** Chart and imaging (MRI, CT, US) review of four intra-operatively proven cerebral hydatidosis, three pediatric and one adult, patients was made.

**Results:** There were 3 pediatric cases between the age of 5 and 10 years, 2 female and 1 one male, and an adult, 29year, with cerebral hydatidosis. All of them presented with hemiparesis, nausea and vomiting and one of the pediatric patients presented in addition to the aforementioned with visual loss and seizure. All of the patients came from rural south Ethiopia (Arsi and Bale) except the adult patient but who used to live his childhood in same area came from an urban town (Dire Dawa), South East of the country. All had history of contact with pet animals (dogs). On imaging (CT and MRI) done with and without contrast there were solitary cerebral cysts with and without daughter cysts in each of the patients measuring between 6x5cm minimum and 11x11cm maximum. Two patients images showed post contrast rim enhancement with peri-lesional edema and likely to be infected cases, and the other two patients showed no enhancement and are likely to be non-infected. One of the pediatric patients had postoperative recurrence of hydatid and adjacent brain abscess and was re-operated and the cyst was removed and the abscess drained. All had uneventful postoperative recovery except one of the pediatric patient who had postoperative recurrence and brain abscess who had residual visual impairment and chronic seizure disorder.

**Conclusion:** Extra cerebral Hydatidosis is endemic and common in rural Ethiopian and East African settings and therefore clinicians and in particular radiologists should be aware of cerebral hydatidosis, especially in a pediatric population, if imaging reveals spherical brain cysts.

### Introduction

Hydatid disease is worldwide zoonosis by the larval stage of the echinococcus tapeworm. There are two types of echinococcus infections namely Echinococcus granulosis, the more common type and Echinococcus multilocularis (alveolaris) which is the less common type but more invasive mimicking malignancy. HD continues to be a significant health problem in underdeveloped world where animal husbandry is common but no veterinary control exists. HD is not uncommon and is endemic in Ethiopian setting posing significant health problem with significant clinical and surgical morbidity and mortality<sup>1-5</sup>. HD spares no body organs and affects from head to toe and accounts for 3-4% of intracranial lesions, and 2-3% of patients with HD have

intracranial Hydatid<sup>6,7</sup>. The majority of HD involving the lungs (8.5-43%) and the liver (50-77%)<sup>6-10</sup>.

CH is acquired in two different forms, a primary CH caused by embryos passing hepatic and pulmonary barriers. The primary intracranial cysts are the most common and are commonly solitary. Secondary cysts are usually multiple, which may follow embolization of ruptured traumatic or surgical cysts in other organs<sup>7,11</sup>. The treatment of cerebral Hydatid cysts is principally surgical. The primary goal of the operation is total cyst extirpation without rupture. We report four case series of surgically proven and exclusively primary CH in Ethiopian setting, which is the first of its kind with review of the literature.

### Patients and Methods

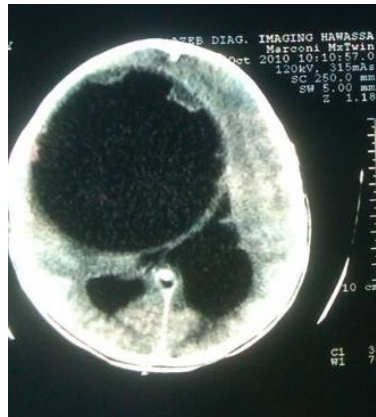
Four cases of CH were operated in Tikur Anbessa and Zewditu teaching hospitals between 2009 and 2011. Their age, sex, clinical presentation, domicile, surgical treatment the intra operative findings, the intra and postoperative complications and six months postoperative clinical follow-ups were recorded. Contact history with pets such as dogs if available was also recorded. All the MRI and CT brain performed with and without intravenous contrast media were reviewed. The size, location and contrast enhancement feature and compression effects of the cyst were recorded. Other imaging such ultrasound of visceral organs and chest x-ray and hematological results were also noted.

### Results

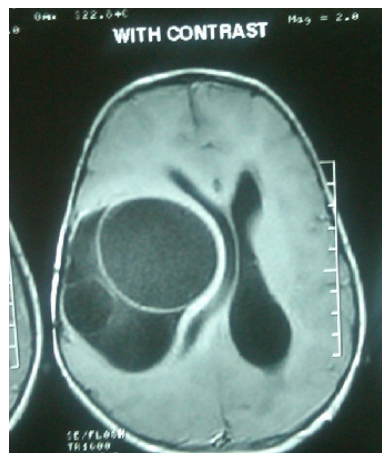
Four cases of cerebral hydatidosis (CH) were operated between 200-2001. Three of the patients were pediatric cases and included one male and two female children aged 8, 5 and 10 years respectively. The fourth case was a 29 years old male. All the three pediatric cases lived in rural South East of the country (Arsi, and Bale). The adult was raised in the same area but at the time of review was living in urban town, Dire Dawa. All had history of contact with pet animal (dogs). All of them presented with progressive hemiparesis, nausea and vomiting, and one of the pediatric patient presented with progressive visual impairment and seizure disorder.

Two of the pediatric patients had both MRI and CT of the brain and the others had only brain CT. All the MRI and the CT were performed pre and post contrast. On imaging all showed single big cerebral hemispheric cyst, with three cases showing daughter cysts (Figures 2,3,4) and one showing simple cyst with mural vesicle (Figure 1). The cysts measured 6x5cm at minimum and 11x11 cm maximum, all causing ipsilateral lateral ventricular compression or effacement and obstructive hydrocephalus and were located in the frontoparietal, parietal and tempoparietal and middle cerebral artery circulations. In two patients (Figures 3, 4) there is peri-cystic contrast enhancement on both MRI and CT with pericystic vasogenic edema. And the other two showed a hypodense layered cyst wall or hypointense rim on both T1 and T2 weighted pre and post contrast images. One had eosinophilia of 10% otherwise all had normal CXR and abdominal ultrasound and CBC. The mode of treatment for all cerebral hydatidosis were craniotomy (three Frontal craniotomies and one temporal craniotomy) with the goal

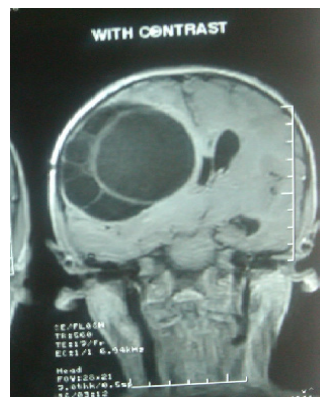being complete removal without rupture. The hydatid cysts were removed unruptured in three of the cases.



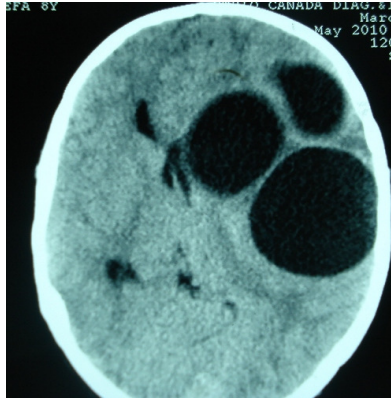
**Figure 1. Case 1: a 5yr old female axial pre-contrast CT showing Rt. fronto-parietal big cyst with mural vesicle, midline shift and Obstructive hydrocephalus.**



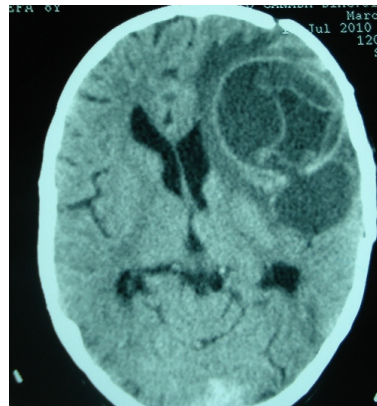
**Figure 2A. Case 2, a 10yr old female MRI: T1W axial post contrast showing Rt. Parietal cyst with daughter cysts, lateral ventricular compression, midline shift and obstructive hydrocephalus.**



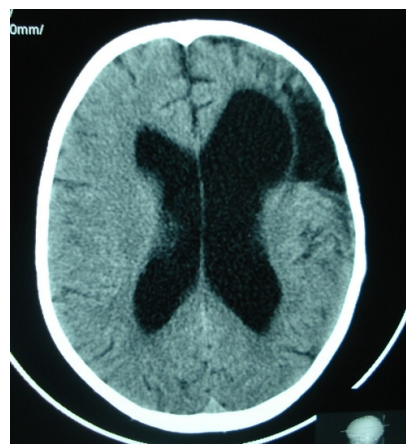
**Figure 2B. Case 2, a 10yr old female MRI T1W coronal post contrast image showing midline shift and ventricular compression by Rt. Parietal cyst showing no contrast enhancement.**



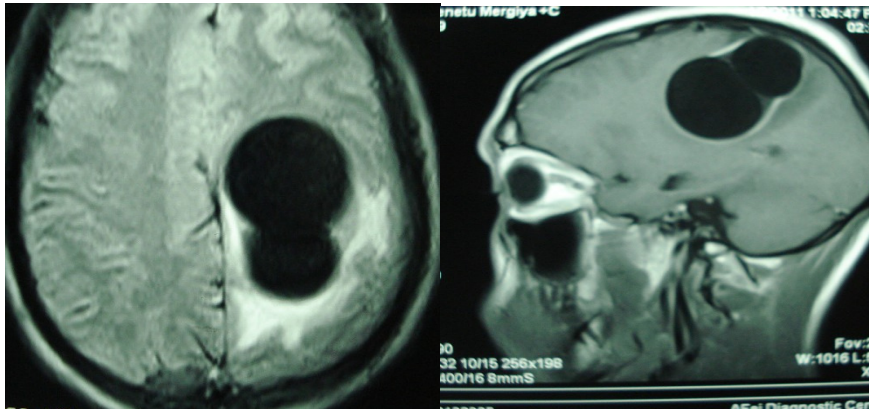
**Figure 3A. Case 3: 8yr old male axial pre-contrast CT showing Left fronto -parietal big cyst with daughter cysts, midline shift and ventricular compression**



**Figure 3B. Case 3, an 8yr old male axial post contrast CT showing post operative recurrence of post contrast rim enhancing left frontoparietal cyst with detached germinal membrane and retro cystic abscess with significant peri-cystic vasogenic edema.**



**Figure 3C. Case 3: 8yr old male axial pre Control CT after six months of the second operation showing left temporo-parietal cystic encephalomalacia and ex-vacuo ipsilateral lateral ventricular dilation.**



**Figure 4A and B. Case 4: a 29 year old male, axial MRI Fluid suppressed FLAIR and T1W sagittal post contrast sequence showing peri-cystic edema and rim enhancement**

All had uneventful post operative course except one of the pediatric patient who developed post operative recurrence of the cerebral hydatidosis at the same location and brain abscess and leptomenigitis (Figure. 3B). He was re-operated and the cyst was removed and the abscess was drained. Control CT scan after 8 months showed extensive tempoparietal gliosis with ex-vacuo ventriculomegaly (Figure 3C) otherwise no residual CH. Clinically has persistent residual poor vision and seizure and he is on pediatric neurology clinic follow-up.

### Discussion

Cerebral cystic echinococcosis commonly seen in children and young adults in 50-70% of the cases<sup>12-14</sup> and this is compatible with our findings, and are located in the supratentorial hemispheric region and are distributed within the territory of the middle cerebral artery and mainly in the parietal lobe and this is consistent with other reports<sup>12-15</sup>. CH are usually single and multiple cysts are rare and multiple cysts are often associated with other organs involvement<sup>15,17</sup>. Recurrent cysts due to rupture of the primary cyst during surgery is not uncommon and was seen in one of our patients who had an infected cyst which ruptured intra-operatively. Patients with CH may have HC in other organs, in recent studies hepatic, pulmonary and other locations were found in 10% of the cases<sup>18</sup> but none of our patients had extra cranial hydatid as abdominal ultrasound and CXR were normal. Both CT and MRI demonstrate a spherical and well defined, smooth, thin walled homogenous cystic lesion with fluid density similar to the CSF with or without septation or daughter cyst and/or calcification. On CT the cyst wall is isodense or hyperdense to the brain tissue. On MRI the cyst wall shows a rim of low signal intensity on both T1 and T2 images. Enhancement of the cyst wall and pericystic edema may be seen in both CT and MRI if there is super infection, rupture or leakage of the cyst<sup>7,15</sup> and this was seen in two of our patients. Postoperative recurrence of CH is not uncommon<sup>13,15,19</sup> and one of which had a recurrence and postoperative complication of brain abscess. However surrounding edema and rim enhancement is usually absent in untreated or non-complicated cases and this was seen in two of our patients. Displacement of the midline and compression of the ventricles are common because of the big size of the cyst at clinical presentations and this was seen in all of our patients.

The differential diagnosis of CH includes cystic lesions such as porencephalic cyst, arachnoid cyst and cystic tumors of the brain and pyogenic abscess. In contrast to Hydatid cysts porencephalic and arachnoid cysts are not spherical in shape and not surrounded entirely by brain substance. Arachnoid cysts are extra axial masses that may deform adjacent brain. Porencephalic cysts result from insults to normal brain tissue and are lined by gliotic white matter that could easily be demonstrated with MR. Cystic tumors could be differentiated by the enhancement of the mural nodule. Pyogenic abscesses show rim enhancement with surrounding extensive vasogenic edema. Cysticercosis is one of the differential diagnoses and epidemiology of the disease is helpful in the differential diagnosis and this is unlikely as it is not endemic in African setup. The clinical presentation of CH is nausea vomiting and hemi paresis with or without seizures and such presentation is almost seen in all of our patients. Complete removal of Hydatid cyst surgically through wide cranial opening (craniotomy) was the main modality of management of cerebral hydatidosis in our case series consistent with the primary goal of the operation, i.e. total extirpation of the cyst without rupture<sup>20-23</sup>.

### Conclusion

In a country where hepatic and thoracic hydatidosis are common clinical attention should be paid for CH, and patients with thoracic and abdominal hydatidosis should be screened for CH with CT and MRI before patients are symptomatic when the size of the cyst is big enough to compress vital structures and get complicated with associated clinical and neurosurgical morbidity and mortality. And cerebral hydatidosis should be included in the differential diagnosis of intracranial and cystic space occupying mass lesions, especially in the pediatric patients, if CT and/or MRI reveal such findings. Surgery is the main treatment. The goal of surgery is to remove the cysts in Toto without rupture

### References

1. Mekuria T. Human hydatidosis in Ethiopia. *Ethiop Med J.*1995; 23:81-7.
2. Fuller GK: Hydatid Disease Dassanetch of SouthWest Ethiopia. *Tran R Soc Trop Med Hyg.* 1976; 70:353-4.
3. Adem A, Hagos B, Dereje G. Experience of surgical therapy in 72 patients with hydatidosis over a 10 year period. *Ethiop Med J.* 2005; 43(1):1-8.
4. Hagos B, Mesfin M, Abebe B. Hydatid disease of the liver: A 12 year experience of surgical management. *East and Central African Journal of Surgery.* 2006; 11(2):54-60.
5. Mesfin M, Hagos B, Abebe B, Mulubirahan A. surgical management of 234 patients with hydatid disease: The Tikur Anbessa Hospital Experience. *Ethiop Med J.*2007;45(3): 257-265.
6. Polat P, Kantarci M, Alper F, Suma S, Koruyucu MB, Okur A. Hydatid Disease from Head to Toe. *Radiographics.*2003; 23:475-494.
7. Miabi Z, Hashemi H, Ghaffarpour M, Ghelichna H, Media R. *Acta Medica Iranica.*2005; 43(3):359-364.
8. Krajewski R, Stelmasiak Z. Cerebral hydatid cysts in children. *Childs Nerv Syst.* 1991 June; 7(3):154-155.

9. Boles DM. Cerebral echinococcosis. *Surg Neurol.* 1981 Oct;16(4):280-282.
10. Ersuhin Y, Matluer S, Guzelbag E. Intracranial hydatid in children. *Neurosurgery.* 1993 Aug; 33(2):219-224.
11. Turant M, Benl K, Eryilmaz M. Secondary multiple intracranial hydatid cysts caused by intracerebral embolism of cardiac echinococcosis: an exceptional case of hydatidosis. Case report. *J of Neurosurg.* 1997 Apr; 86(4):714-718.
12. Haliloglu M, Saatci I, Akhan O, Ozemen MN, Besim A. Spectrum of imaging findings in paediatric hydatid disease. *AJR.* 1997; 169:1627-31.
13. Lunardi P, Missori P, Di Lorenzo N, Fortuna A. Cerebral hydatidosis in childhood: a retrospective survey with emphasis on long-term followup. *Neurosurgery* 1991; 29:515-18.
14. El-Shaman O, Amer T, El-Atta MA. Magnetic Resonance imaging of simple and infected hydatid cysts of the brain. *Magn Reson Imaging.* 2001; 19:965-74.
15. Bukte Y, Kemanoglu S, Nazaroglu H, Ozkan U, Cerviz A, Simsek M. Cerebral hydatid disease: CT and MRI findings. *Swiss MED WKLY.* 2004; 134:459-467.
16. Vaquero J, Jimenez C, Martinez R. Growth of hydatid cyst evaluated by CT scanning after presumed cerebral hydatid embolism. Case report. *J Neurosurg.* 1982; 57:837-8.
17. Demir K, Karsi AF, Kaya T, Devrimici E, Alkan K. Cerebral hydatid cysts: CT findings. *Neuroradiology.* 1991; 33:22-4.
18. Singounas EG, Leventis AS, Sakas DE, Hadley DM, Lampadrios DA, Karvounis PC, et al. Successful treatment of intracerebral hydatid cysts with albendazole: Case report and review of the literature. *Neurosurgery* 1992; 31:171-4.
19. Erashin Y, Mutluer S, Guzelbag E. Intracranial hydatid cysts in children. *Neurosurgery* 1993; 33: 219-24.
20. Y. Izci, Y. Tuzun. H.I. Secer, E. Gonul. Cerebral hydatid cysts: technique and pitfalls and surgical management. *Neurosurg Focus* 24 (6):E15, 2008
21. Tuzun Y, Kadioglu HH, Izci Y, Suma S, Keles M, Aydin IH: The clinical, radiological and surgical aspects of cerebral hydatid cysts in children. *Pediatr Neurosurg* 40:155-160, 2004 13. Weaver KD
22. Altinörs N, Senveli E, Dönmez T, Baybek M, Kars Z, Sanli M: Management of problematic intracranial hydatid cysts. *Infection* 1995; 23:283-287.
23. Arana-Iniguez R, San Julian J: Hydatid cyst of the brain. *J Neurosurg* 1955; 12:323-335.