

Prevention of Recurrent Laryngeal Nerve Injury in Thyroid Surgery: Are Neuromonitoring Techniques Needed?

A.M. Nour, A.H.A. Al-Momen

Department of General Surgery, SSH, Al-Khobar, Kingdom of Saudi Arabia
Address correspondence and requests for reprints: Dr Ashraf Noureldin,
Associate professor and Consultant general surgeon, Saad Specialist
Hospital, Al-Khobar, KSA.

Correspondence to: Dr. A.A. Nour, Email: ashnour2000@yahoo.com

Background: Identification of the recurrent laryngeal nerve is the most essential in thyroid surgery. Positive identification of the nerve is essential for preservation of nerve integrity and function. Some authors recommend using of nerve monitoring techniques.

Methods: 359 thyroid surgeries with obligatory exposure of the RLN were reviewed. Meticulous dissection and exploration of the nerve was the main technique in our study.

Results: The nerve was identified in 97% of cases, Temporary RLN palsy was found in 6 patients and permanent palsy was found in 1 case. No neuromonitoring techniques were used.

Discussion: Our results and the literature review showed that the nerve can be clearly identified and protected in thyroid surgery without using any neuromonitoring techniques. In cases without identification, capsular dissection is the safest way to protect the nerve. Neuromonitoring techniques are time consuming, have never been a substitute to meticulous dissection and were never with better results than conventional meticulous dissection.

Introduction

Thyroid surgery continues to be the most common operation to be performed by endocrine surgeons and complications from thyroidectomy continue to fuel the debate about the best surgical technique. Injury to the recurrent laryngeal nerve (RLN) is a feared complication with associated morbidity¹ and is the most common source of litigation in patients who have undergone endocrine surgery². Positive identification of the RLN is essential for preservation of nerve integrity and function.

Many recent studies validated the importance of nerve identification during thyroidectomy to decrease the risk of injury³⁻¹⁵. Hermann et al³, in their review of 16,443 patients who underwent thyroidectomy, showed that the incidence of temporary and permanent RLN paralysis was significantly reduced if the nerve was identified. One study quoted an incidence of nerve paralysis three to four times greater in cases in which the recurrent nerve was not localized compared with cases in which it was¹⁶.

The RLN can be injured during thyroid surgery by compression, traction, stretching, entrapment in a ligature, hematoma, thermal injury, electrical injury, severing injury, and non-identification. Since the most frequent and most feared post-thyroidectomy complication is RLN injury, the routine exposure and protection of this important structure should become a standard procedure during thyroidectomy; therefore, an accurate knowledge of the anatomy of the RLN and its anatomical variations, in addition to meticulous dissection and operation by an experienced surgeon is fundamental in thyroid surgery.

Our objective is to perform careful identification, exposure and protection of the RLN in all our cases as an initial step in performing safe thyroid surgery and to prove that only its identification and protection, by experienced endocrine surgeons, allow prevention of iatrogenic injuries without the aid of any neuromonitoring techniques.

Patients and Methods

A prospective study of 359 patients who underwent thyroidectomy (total and hemithyroidectomies) in the period between January 2000 and December 2008 at three different regional hospitals by the

endocrine surgical teams. The charts were reviewed and each side of the thyroid gland was considered as a separate unit in the analysis of the results. The study was designed to determine the outcome after exposure and protection of the RLN without the use of any neuromonitoring techniques. Unilateral thyroidectomy was performed for 108 patients; total thyroidectomy was performed for 251 patients raising the number of RLN dissected to 502 (total number of RLN exposure is 610). All patients underwent laryngoscopic evaluation before surgery, immediately postoperatively on extubation by the anesthetist and the time of discharge by an experienced laryngoscopist if needed only. At preoperative laryngoscopic evaluation there was only one case of documented vocal cord palsy, which was excluded from the study due to infiltration by anaplastic carcinoma. Fine needle aspiration was done in patients according to the suspicion of being malignant or benign.

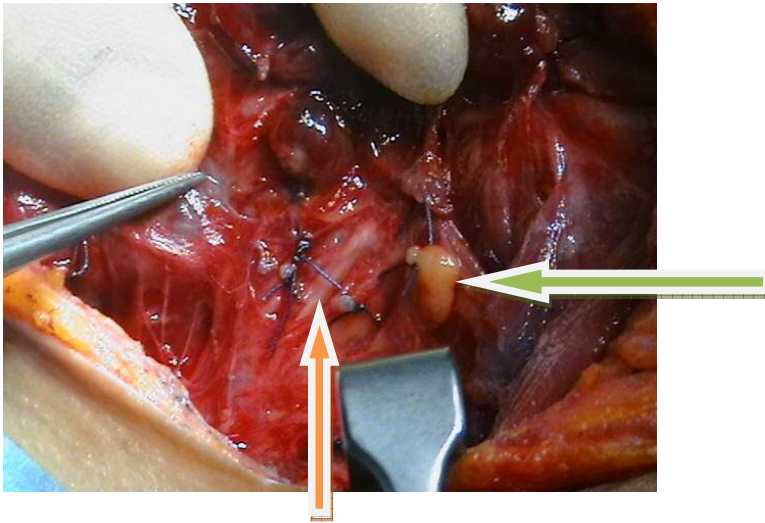


Figure 1. The recurrent laryngeal nerve (Orange arrow) identified intraoperatively and a preserved parathyroid gland (Green arrow).

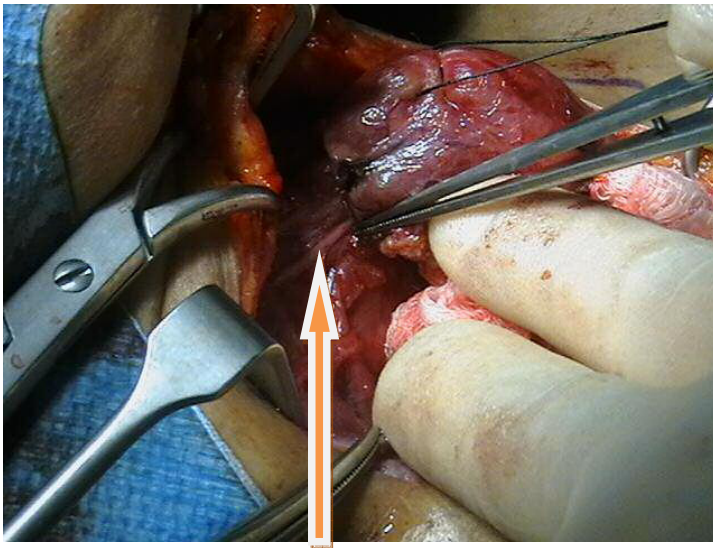


Figure 2. The recurrent laryngeal nerve identified intraoperatively.

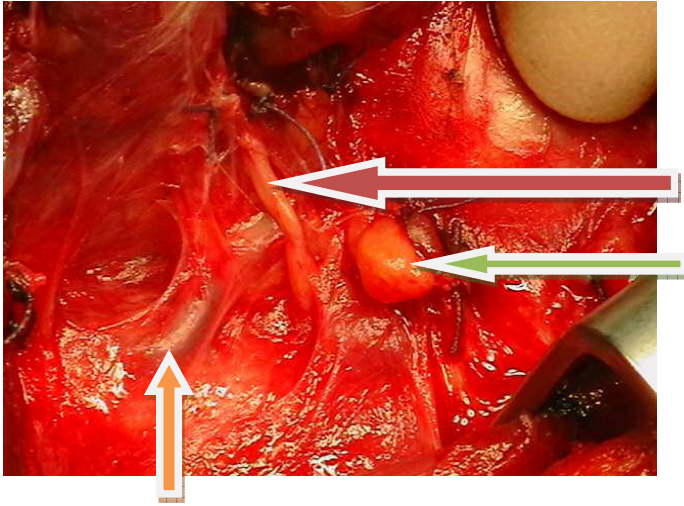


Figure 3. The Recurrent Laryngeal Nerve passing anterior to the inferior thyroid artery and a preserved parathyroid gland.

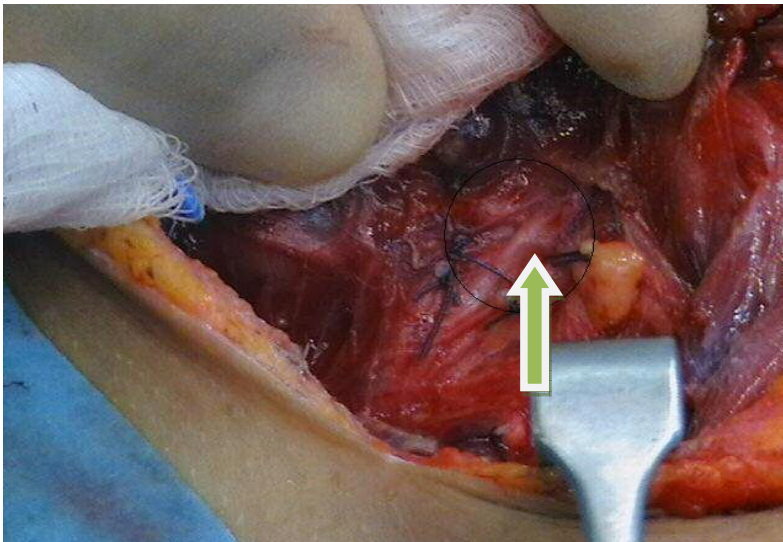


Figure 4. The recurrent laryngeal nerve bifurcated before entering the larynx (circle).

Table 1. Patients characteristics with complications

Number of patients	359
Mean age	43
Female to male	237:122
Temporary RLN injury	6
Permanent RLN injury	1
Temporary hypoparathyroidism	3
Permanent hypoparathyroidism	0
Hospitalization	1-4 days
Mortality rate	0
Hematoma	2

Wound infection	0
------------------------	---

Table 2. Final Pathology

Pathology	Number
Benign nodular goiter	173
Adenoma	22
Toxic goitre	36
Malignancy*	102
Recurrent goiter	10
Thyroiditis	16

* Thyroid cancer is the second most common cancer in Saudi Arabia and some Arabian Gulf countries. (17, 18)

Table 3. Details of patients with RLN palsy

Patient	Age/sex	Diagnosis	Risk group	Procedure	Palsy Duration
1	63/M	Anaplastic ca	High	Total	>12 months
2	28/F	Thyroiditis	High	Total	3 weeks
3	42/F	Recurrent	High	Hemi	9 weeks
4	46/M	Recurrent	High	Total	12 weeks
5	31/F	Benign	Low	Total	3 weeks
6	44/F	Benign	Low	Hemi	5 weeks
7	39/F	Toxic	Low	Total	4 months

Patients were also classified into low-risk and high-risk group according to the inbuilt risk of morbidity due to the nature of the procedure and the expected technical difficulty. The high-risk group included those who were for recurrent surgery, surgery for malignancy and patient with thyroiditis (157 patients). The low risk group included all other cases who undergone surgery for benign pathology (202 patients).

The RLN was routinely identified, exposed and protected.

Surgical exposure of the nerve

After exposing the gland, the middle thyroid vein was ligated and divided.. Thereafter, the superior pole vessels were ligated followed by inspection of the trachea-esophageal groove and pericapsular dissection to identify the RLN at the cricothyroid joint. The inferior thyroid artery was identified laterally and followed till its branches which are closely related to the RLN. The nerve was identified and protected till it entered the cricothyroid membrane.

Meticulous technique was used in addition to strict avoidance of vigorous dissection or electrocautery anywhere near the nerve. Complete exposure of the nerve was done in the area near the gland. Once the integrity of the RLN and the parathyroid glands had been ensured, the terminal branches of the inferior thyroid artery close to the thyroid capsule were ligated. Ligation of the main trunk of the inferior thyroid artery was always avoided and the gland was dissected sharply from the trachea at Berry's ligament.

If the RLN was not identified capsular dissection was performed with caution.

Results

The patients ranged in age from 25 to 77 years (mean 43 years), and there were 237 women and 122 men. Patient's characteristics are presented in table 2. The RLN was clearly identified in 593/610 sides of the gland (97.2%), 17 were not identified (Figures 1, 2, 3 and 4). Reviewing the operative reports, there were 2 cases of non-recurrent laryngeal nerve on the right side; the nerve passed directly from the Vagus nerve to the larynx by passing deep to the lateral thyroid lobes. Three nerves were located lateral to the trachea outside the tracheoesophageal groove and two were deep to the inferior thyroid artery. Postoperative complications included temporary RLN palsy in 6 patients (1.6%) whereas temporary hypoparathyroidism occurred in 3 patients (0.8%). Permanent RLN palsy occurred in 1 patient (0.3%). Wound hematoma developed in 2 patients. Neither wound infection nor mortality was noted. No respiratory distresses were noticed. The final pathology reports are shown in table 2.

All patients were subjected to flexible nasopharyngoscopy after surgery before discharge; all vocal folds were freely mobile except for 6 patients that showed palsy and the case with permanent palsy. For patients with documented cord palsy during postoperative laryngoscopy repeated examination were performed during the follow up at 1, 3, 6, 9 and 12 weeks then at 6, 9, 12 months after the operation until the recovery of vocal cord function. Vocal cord paralysis for more than 12 months after the thyroidectomy was considered a permanent palsy.

The rate of RLN palsy in the low risk group was 0.9 % (2/202), in the high risk group was 2.7% for temporary palsy (4/157) and 0.6% (1/157) for permanent palsy. Details of patients with RLN palsy are shown in table 3.

Discussion

Routine exposure of the RLN throughout its course has been shown to reduce the rate of recurrent laryngeal nerve injury (3). In our opinion, the only safeguard against RLN damage, when performing a thyroidectomy, consists of identifying rather than avoiding the nerve in addition to wise surgical technique to protect the nerve. It allows the surgeon to visualize and avoid injury to the RLN during thyroid resection. We consider it a routine component of every thyroidectomy. In our study the nerve was identified in 97% of cases, there were only 6 cases of temporary RLN palsy and one case of permanent RLN paralysis. In our thyroidectomies we were totally dependent on awareness of the anatomy, variations and abnormalities of the recurrent laryngeal nerve in addition to meticulous dissection and hemostatic techniques.

In this study no intraoperative nerve monitoring techniques were used this is in contrast to many other studies that recommended such techniques^{5,6,7,8,11,13}. The era of minimally invasive and videoscopic thyroidectomy is becoming more and more in use in which technical difficulties might prevent the use of neuromonitoring equipments and still multiple studies focus on the issue of intraoperative monitoring of RLN function. Intraoperative nerve monitoring has been described in the literature for nearly three decades, and has been advocated strongly in the last several years as a means to reduce the risk of nerve injury and to assist in positive nerve identification¹⁹.

Commonly used devices are EMG monitors that can detect spontaneous and evoked potentials. These devices require the placement of electrodes into, or in contact with the muscles that are innervated by the RLN.

In wire-hooked electromyography electrodes should be inserted endoscopically or through the cricothyroid membrane into the thyroarytenoid muscle or into the cricopharyngeus^{20,21,22}. This set-up requires precise placement of the endotracheal tube during intubation with the bare wires on the true vocal cords. Right- and left-sided coding should be done to take advantage of the anatomic configuration of the larynx. This setup requires the initial laryngoscopy to place and secure. Another method is the combination of electrical RLN stimulation with fiberoptic video laryngoscopy by way of laryngeal mask airway²³.

All of the above nerve monitoring techniques are time consuming, expensive and are with some drawbacks. It's noteworthy to mention the limitations of such techniques. For nerve integrity monitoring to be effective, the anesthetist must not use any long-acting paralytics, as they will invalidate any attempt at monitoring²⁴. Additionally, the experience of some researchers with nerve monitoring has been described as being "overly sensitive to manipulation of the surrounding soft tissue". These investigators have only recommended it as a "valuable tool for difficult thyroidectomies" or "repeat operations" or where there is "extensive local disease"²⁴.

In general, neuromonitoring is a poor aid for finding the RLN. To obtain a conclusive acoustic signal, the operator must be sure to expose the RLN to the neuromonitoring. Thus anatomic variations must still be anticipated and detected by the surgeon. Furthermore, to prevent a false-negative test, neuromonitoring must be performed at the end of the operation, as simple testing and further dissection cannot exclude a nerve lesion that occurs late during the operation. Technical pitfalls must also be considered. The electrode must be attached correctly and tested on the endotracheal tube before intubation; and the endotracheal tube must be placed with the electrode exactly at the level of the vocal cords.

With the neuromonitoring applied in some studies it is still impossible to dissect and monitor simultaneously. Thus continuous monitoring seems mandatory²⁵. Electro-physiologic RLN monitoring does not always translate into clinical postoperative vocal fold mobility as attested by two cases of permanent vocal fold paralysis that were monitored and had a positive electrophysiologic stimulation of the RLN at the conclusion of RLN dissection in the study made by Wit²⁶. In the study made by Chan et al, neuromonitoring incorrectly predicted normal function for 7 nerves that were subsequently confirmed to be immobile, as shown by postoperative laryngoscopy (false negative). And in the same study normal postoperative vocal cord function was demonstrated in 15 nerves, although the signal was absent at the completion of the procedure (false positive)²⁶.

An additional drawback is the cost of the whole procedure including the monitoring equipment itself and the additional cost of each set of electrodes are a burden on the patient and the treating center. A procedure involving electro-physiologic monitoring requires additional time, reflecting an additional cost not only in operative time, but also in the purchase and maintenance of the nerve integrity monitor, need for a special endotracheal tube, and the technical staff who intra-operatively monitor the RLN. Despite the application of intraoperative neuromonitoring, the rate of permanent RLN palsy was 0.6% for benign lesions, 2.9% for malignant lesions, and 7.7% for those requiring recurrent thyroid surgery²⁵.

Thomusch et al²⁸ presented a large prospective multicenter trial evaluating neuromonitoring during benign goiter surgery. The rate of permanent RLN palsy was reduced from 0.8% to 0.4% with the use of neuromonitoring. However, 66% of their patients were excluded because the nerves were not identified intraoperatively. In our series, there were only one case of permanent RLN palsy (0.9%), no patients were excluded after surgery, and the RLN was exposed intraoperatively in 97%. Furthermore, their rate of total lobectomy was distinctively lower, with 22%, compared to 77.6% in our series. Witt in his study comparing monitored and unmonitored thyroid surgery has concluded that electro-physiologic RLN monitoring was not demonstrated to reduce the incidence of transient or permanent vocal fold injury after thyroid surgery²⁶.

In this study there were only 6 cases of temporary RLN palsy that subsided gradually within 3-16 weeks after surgery. This palsy could be attributed to a small-localized hematoma (not detected clinically), or due to a neuropraxia (from dissection attempts to expose the nerve in high risk cases). Most cases with thyroiditis are surrounded with tough adhesions (due to capsular and pericapsular inflammations) that make identification of the nerve more difficult requiring more sharp dissections. The patient who developed permanent RLN palsy had anaplastic cancer, the nerve couldn't be identified or freed during the surgery. In the 17 cases in which the RLN was not identified (593/610),

capsular dissection was the safest way. These cases were 5 cases of large benign long standing multinodular goiter, 2 cases of chronic thyroiditis having tough adhesions, 3 cases of recurrent disease requiring redo surgery, 4 cases of toxic goiter and 3 cases of malignant thyroid. At this point it is never wise or brave to dissect and expose the RLN in such situations; any excessive dissection can traumatize or injure the nerve, as the nerve is mostly adherent to these tough adhesions, so it is better to avoid dissecting through such adhesions to protect the nerve.

Surgeons experience

This study has shown that surgeons' experience has a good influence on identification and protection of the RLN. In this study surgical experience and awareness of the RLN anatomy and abnormality was the mainstay for its conduction. Most surgeons agree that although nerve monitoring could be a useful adjunct for RLN identification this technique is not a substitute for meticulous dissection by an experienced surgeon. LaMade and colleagues²⁸ reported nearly twice as high an incidence of early RLN dysfunction in surgeons who had completed their training and were not specializing in thyroid surgery compared to established surgeons specializing in thyroid surgery and surgical trainees. The lower incidence of complications in surgical trainees was likely the result of extensive supervision by more experienced surgeons.

We believe that if a surgeon ever faces a difficult dissection the capsular approach could be an efficient and reasonable way to save the RLN. The RLN always exists and will always enter the larynx to supply its muscle's, it's not an intraglandular structure as the facial nerve that needs intraglandular dissection or search for. It's always separable and nonadherent to surrounding tissues except in certain situations as malignancy, redo-surgery or inflammations. It will always be identified by wise and meticulous surgical techniques.

There are several ways to protect the RLN intraoperatively; an experienced endocrine surgeon will be careful and very meticulous at the most common site of injury to the nerve; the area of the Berry ligament where the nerve enters the larynx. Avoiding excessive traction to safe guard embedded nerve fibers from being pulled and total extracapsular thyroidectomy without hemostatic sutures must be performed at this area to safeguard the nerve. A bloodless field allows excellent visualization with identification and preservation of the nerve until entering the larynx. The surgeon must also be careful during ligation of the inferior thyroid veins; a mass ligature of these veins is not wise as it may include the RLN particularly if it is anterolateral to the trachea. Finally hemorrhage, which is a most common cause of nerve damage during its control, should be stopped meticulously without blind ligatures or cauterization except under direct vision of the bleeding point or preferably by absorbable packing.

In this study all of the surgeons trained in endocrine surgery and had completed their training.

Conclusions

Identification and protection of the RLN will always be dependent on the Surgeons experience, knowledge of anatomical variations and meticulous dissection. In this study the surgeons experience has shown to be an efficient and reliable method of reducing permanent and transient RLN injury. Nerve monitoring techniques has never been a substitute to meticulous dissection by an experienced surgeon and has never lead to better outcomes.

References

1. Abdel R, Ahmed ME, Hassan MA. Respiratory complications after thyroidectomy and the need for tracheostomy in patients with a large goiter. *Br J Surg* 1999;86:88-90.
2. Kern KA. Medicolegal analysis of errors in diagnosis and treatment of surgical endocrine disease. *Surg* 1993; 114:1167-74.

3. Hermann M, Alk G, Roka R, et al. Laryngeal recurrent nerve injury insurgery for benign thyroid diseases: effect of nerve dissection and impact of individual surgeon in more than 27,000 nerves at risk. *Ann Surg* 2002; 235:261-8.
4. Brennan J, Moore EJ, Shuler KJ. Prospective analysis of the efficacy of continuous intraoperative nerve monitoring during thyroidectomy, parathyroidectomy, and parotidectomy. *Otolaryngol Head Neck Surg* 2001; 124(5):537-43.
5. Djohan RS, Rodriguez HE, Connolly MM. Intraoperative monitoring of recurrent laryngeal nerve function. *Am Surg* 2000; 66(6):595-7.
6. Eltzschig HK, Posner M, Moore FD Jr. The use of readily available equipment in a simple method for intraoperative monitoring of recurrent laryngeal nerve function during thyroid surgery: initial experience with more than 300 cases. *Arch Surg* 2002; 137(4):452-7.
7. Brauckhoff M, Walls G, Brauckhoff K. Identification of the nonrecurrent inferior laryngeal nerve using intraoperative neurostimulation. *Langenbecks Arch Surg* 2002; 386(7):482-7.
8. Hemmerling TM, Schmidt J, Bosert C, et al. Intraoperative monitoring of the recurrent laryngeal nerve in 151 consecutive patients undergoing thyroid surgery. *Anesth Analg* 2001; 93(2):396-9.
9. Flisberg K, Lindholm T. Electrical stimulation of the human recurrent laryngeal nerve during thyroid operation. *Acta Otolaryngol* 1970;263:63-7.
10. Steurer M, Passler C, Denk DM, et al. Advantages of recurrent laryngeal nerve identification in thyroidectomy and parathyroidectomy and the importance of preoperative and postoperative laryngoscopic examination in more than 1000 nerves at risk. *Laryngoscope* 2002; 112(1):124-33.
11. Jonas J, Ba` hr R. Intraoperative electromyographic identification of the recurrent laryngeal nerve. *Chirurg* 2000; 71(5):534-8.
12. Misiolok M, Waler J, Namyslowski G, et al. Recurrent laryngeal nerve palsy after thyroid cancer surgery: a laryngological and surgical problem. *Eur Arch Otorhinolaryngol* 2001; 258(9):460-2.
13. Lipton RJ, McCaffrey TV, Litchy WJ. Intraoperative electrophysiologic monitoring of laryngeal muscle during thyroid surgery. *Laryngoscope* 1988; 98:1292-6.
14. Maloney RW, Murcek BW, Steehler KW, et al. A new method for intraoperative recurrent laryngeal nerve monitoring. *Ear Nose Throat J* 1994; 73:30-3.
15. Mra Z, Wax MK. Nonrecurrent laryngeal nerves: anatomic considerations during thyroid and parathyroid surgery. *Am J Otolaryngol* 1999; 20(2):91-5.
16. Mountain JC, Stewart GR, Colcock BP. The recurrent laryngeal nerve in thyroid operations. *Surg Gynaecol Obstet* 1971; 133: 978-80.
17. Tumor Registry Annual Report, 1998. Oncology Data Unit, King Faisal Specialist Hospital and Research Center. Thyroid cancer is the second most common cancer among Saudi women. 1998 Cancer Incidence Report, Gulf Cooperation Council Countries, April, 2002.
18. Brian D. Affleck, MDa, Keith Swartz, MDb, Joseph Brennan, MD, FACS, Surgical considerations and controversies in thyroid and parathyroid surgery *Otolaryngol Clin N Am* 36 (2003) 159-187.
19. Jatzko GR, Lisborg PH, Muller MG, et al. Recurrent nerve palsy after thyroid operations: principle nerve identification and a literature review. *Surgery* 1994; 115:139-44.
20. Sasaki CT, Mitra S. Recurrent laryngeal nerve monitoring by cricopharyngeus contraction. *Laryngoscope* 2001; 111:738-9.
21. Katz AD. Extralaryngeal division of the recurrent laryngeal nerve: report on 400 patients and the 721 nerves measured. *Am J Surg* 1986; 152:407-10.
22. Eltzschig HK, Posner M, Moore FD Jr. The use of readily available equipment in a simple method for intraoperative monitoring of recurrent laryngeal nerve function during thyroid surgery: initial experience with more than 300 cases. *Arch Surg* 2002; 137(4):452-7.
23. Shindo ML. Considerations in surgery of the thyroid gland. *Otolaryngol Clin North Am* 1996; 29:629-35.

24. Beldi G, Kinsbergen T, Schlumph R. Evaluation of Intraoperative recurrent Nerve monitoring in thyroid surgery World J Surg. 28, 589-591, 2004.
25. Witt R Recurrent Laryngeal nerve Electrophysiologic Monitoring in Thyroid Surgery: The Standard of care? J Voice 2005; 19 (3): 497-400,2005.
26. Chan WF, LO CY. Pitfalls of Intraoperative Neuromonitoring for Predicting Postoperative Recurrent Laryngeal Nerve Function during Thyroidectomy. World J Surg. 2006 Apr 17 30:806-812.
27. Thomusch O, Sekulla C, Walls G, et al. Intraoperative Neuromonitoring of Surgery for benign Goitre. Am J Surg. 2002; 183, 673-678.
28. Lamade W, Renz K, Willeke F, Klar E, Herfarth C Effect of training on the incidence of nerve damage in thyroid surgery. Br J Surg. 1999 Mar; 86(3):388-9.