

REVIEW ARTICLE

Endoscopic trans-canal myringoplasty: Relevance for sub-Saharan Africa? A systematic review

Wakisa Mulwafu¹, David Strachan², Emmanuel Singano³, Anil Banerjee⁴, Kerry Haddow⁵, Chris Raine²

1. College of Medicine, University of Malawi, Blantyre, Malawi
2. Bradford Royal Infirmary, Bradford, UK
3. Queen Elizabeth Central Hospital, Blantyre, Malawi
4. University Hospitals of Leicester, Leicester, UK
5. Department of Otolaryngology, Victoria Hospital, Kirkcaldy, UK

Correspondence: Dr Wakisa Mulwafu (wmulwafu2@gmail.com)

© 2019 W. Mulwafu et al. This open access article is licensed under a Creative Commons Attribution 4.0 International License (<http://creativecommons.org/licenses/by/4.0/>), which permits unrestricted use, distribution, and reproduction in any medium, provided you give appropriate credit to the original author(s) and the source, provide a link to the Creative Commons license, and indicate if changes were made.



East Cent Afr J Surg. 2019 Apr;24(1):61–66
<https://dx.doi.org/10.4314/ecajs.v24i1.9>

Abstract

Background

We systematically reviewed the literature on endoscopic trans-canal myringoplasty with regard to graft take-up rates with mean air-bone gaps.

Methods

All identified English-language articles from Medline and Embase reporting on endoscopic trans-canal myringoplasty were eligible. Both pediatric and adult patients were included. No limitation was placed on study design or level of evidence. We extracted data regarding study country, mean patient age, mean air–bone gap, type of anesthesia used, endoscope used, duration of follow-up, and graft take rate.

Results

Twenty-one articles were included in the review. The overall graft closure was 88.3%. Sixteen studies provided the air bone gap gain. The mean air bone gap gain was 9.8.

Conclusions

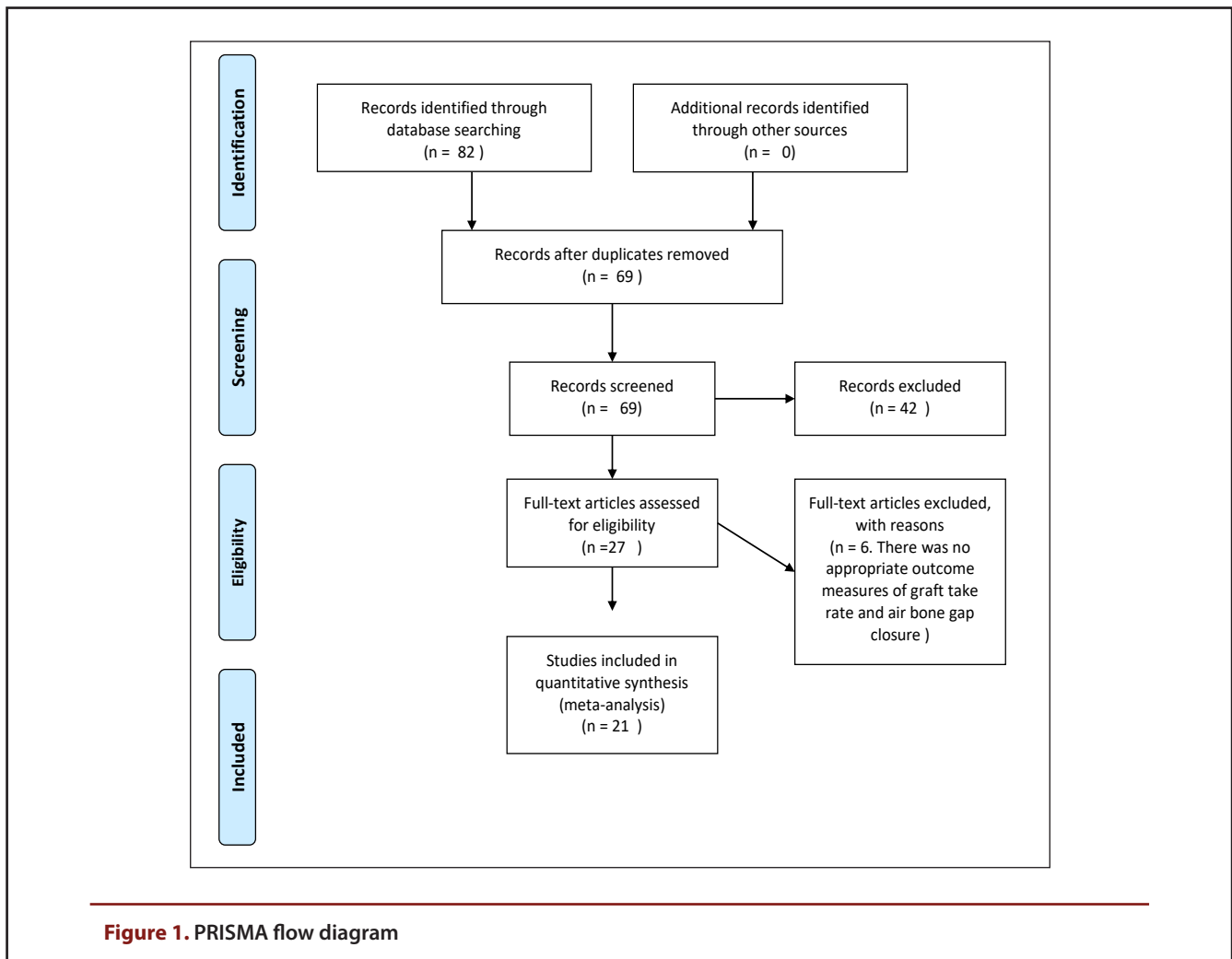
Endoscopic trans-canal myringoplasty leads to high graft take-up rates with low mean air-bone gaps. The technique has not been reported in Sub-Saharan Africa but has a potential to play a significant role in surgical management of CSOM in this region.

Keywords: endoscopic, trans-canal, myringoplasty, sub-Saharan Africa

Introduction

The impact of Chronic Suppurative Otitis Media (CSOM) on the developing regions of the world, as well as its current lack of effective treatment options, make it in danger of becoming a neglected tropical disease (1). Although myringoplasty is one of the most common forms of surgery in otology, it is rarely performed in the developing countries for the treatment of CSOM. The obstacles for treatment of CSOM include the training of physicians, procurement of specialized instrumentation including operating microscopes, and adequate hospital facilities and support services. Patient factors are proximity to the treatment facility, ease of transportation and access to post-operative care. (1). Although provision of hearing aids in the developing world is improving, unless CSOM is effectively treated, patients are rendered unsuitable for fitting.

Endoscopic ear surgery is a growing field. It has many advantages compared to traditional microscopic techniques. It is relatively simple to perform and trainees often already have an appropriate skill set from the use of endoscopes in the nose and throat allowing for a shorter and less problematic learning curve. It allows the same operation to be performed with less tissue trauma – ideal in situations that apply in many developing countries where heat and hygiene outside of the operating theatre can compromise postoperative healing. Disadvantages include the lack of depth perception with an endoscope and the single-handed surgery it usually necessitates. However, following the principles of minimally invasive surgery for the repair of tympanic membrane perforations including ‘parachuting’ the graft through the perforation rather than via the lifting of a tympanomeatal flap (TM) may confer significant advantages over standard techniques (2,3).



Despite the overwhelming reports on the increasing use of the endoscope in ear surgery, data from Africa is lacking. A systematic review on endoscopic middle ear surgery by Kozin et al (4) showed that only one country in Africa, Egypt, had a corresponding author of article publication on observational endoscopic ear surgery. We recently introduced endoscopic trans-canal myringoplasty in our unit in Malawi, one of the least developed countries in the world, and it has been readily adopted by both registrars and middle level health workers.

Although many observational studies have shown that endoscopic trans-canal myringoplasty leads to high graft take-up rates with reduced air-bone gaps it should be noted that these rates vary widely.

The objective of this systematic review is to review the graft take-up rate and mean air-bone gap in endoscopic trans-canal myringoplasty.

Methods

Data Sources and Search strategy

A systematic narrative review of published literature was performed according to the Preferred Reporting Items for Systematic Reviews and Meta-Analysis (PRISMA) statement

[5]. Two electronic databases, EMBASE and PubMed were searched on 25 March 2017.

Search terms for endoscop* myringoplast* OR endoscop* tympanoplast* were identified through MeSH as well as from those used for systematic reviews on similar topics. We included articles published in the English language. There were no limits placed on publication date and status.

Inclusion/exclusion criteria

Papers were included if they addressed endoscopic trans-canal myringoplasty or tympanoplasty. Studies that compared endoscopic approach and microscopic approach were included but the data extracted from them only included data from the endoscopy arm. Studies that addressed other middle ear problems such as cholesteatoma, ossiculoplasty and cochlear implants were excluded from the study. Studies that used the endoscopes to assist the microscopic approach were also excluded. Review articles were excluded, but we searched through the reference list to identify relevant papers. Any design was eligible for inclusion (case series, retrospective, cohort, randomised controlled trials)

Study selection

Articles were screened by three reviewers (WM, DZ & ES), first by titles, then by abstract and finally by full text to determine eligibility in the final sample. Titles that were selected by two of the five reviewers were included for review of their abstracts. For those articles that were selected by only one reviewer and the reviewer stuck by their decision, the other two reviewers were asked to look at the title and if there was consensus, the title was included for review of the abstract. The similar process was repeated for the abstracts and full text articles.

Data extraction

Data from the final sample were collated using an extraction table (Table 1). Major outcome variables were extracted and any disagreement resolved by discussion. The main outcome variable was the proportion of graft take. We also extracted data on mean air bone gap, type of graft used, whether or not the TM flap was elevated and length of follow-up. Data on mean age and sex were also extracted

Assessment of risk of bias and quality of studies

We used the Joanna Briggs Institute (JBI) Checklist for Case series to assess the methodological quality of studies and to determine the extent to which the studies addressed the possibility in the design, conduct and analysis (6)

RESULTS

Search for studies

The PRISMA flow diagram (Figure 1) shows the step by step search for studies that were included in the final analysis. Twenty-one studies were included in the final analysis (2-3,7-25)-.

Characteristics of involved studies

The studies were published between 1992 and 2017 with the majority of the studies (14/21) being published between 2012 and 2017. Most of the studies were published in India and Turkey. Only two studies were from North Africa (Egypt) and none from Sub-Saharan Africa. Twelve studies provided the percentages of males and females. There were more females in the studies representing 53.8%. Nineteen studies provided the age range and it ranged between 5 to 87 years. The mean sample size was 35 (SD=16) and ranged between 20 and 82.

The majority of the studies used tragal-perichondrium cartilage graft (9/21) followed by TFG/Connective tissue (7/21). The majority of the cases (9/21) were done under General Anaesthesia (GA) followed by a combination of GA and Local Anaesthesia (LA).

The average graft closure was 88.3%. Sixteen studies provided the air bone gap gain. The mean air bone gap gain was 9.8.

The follow-up period ranged from 2 to 36 months.

Risk of bias

Selection bias

The participation rate reported in some studies are those of patients that had an endoscopic approach but not all who were eligible for surgery. Studies are at risk of selection bias if they do not attempt to recruit participants consecutively.

Detection bias

The studies are a mixture of both retrospective chart review and prospective case series. For retrospective chart review, the researchers had no control of how the graft take rate was assessed.

Discussion

This systematic review identified 21 studies that describe endoscopic trans-canal myringoplasty. In these studies the graft take rate was acceptable at 88.3% and equivalent to the microscopic technique of an average weighted result of 86.5% (26) and for paediatric review 83.4% (27). Whilst the principle of surgery is closure of the perforation there are reported improvements in the reduction of the air bone gap. In these studies, the mean air bone gap of 9.8 dB is a good outcome.

The endoscope has great potential for use in tympanoplasty and it is likely that its introduction will increase the use off the trans-canal approach rather than post-auricular procedures(7). The identity of endoscopic ear surgery is emerging (28). The cost of the endoscope is approximately 10% of the cost of the average operating microscope, thus it is more cost-effective, especially in developing countries (2). Unlike the microscope, the endoscope is easily transportable and hence is ideal for use in ear surgery camps conducted in remote places (29). One of the limitations of the technique is the single-handedness although De Zinis et al(30) have reported using a two handed technique with good outcomes.

The majority of the studies in this systematic review have been published in the last five years reflecting the fact that more surgeons have recently begun using endoscopes during ear surgeries. As such middle ear surgeries, which were traditionally being done using the microscope, are now increasingly being done using the endoscope (8)

In the majority of the studies, the centres were already using the microscopic technique and appear to have transferred to the endoscopic technique. It is not clear from the available data if any centres started using the endoscopic technique "de novo". More research is required on the impact of the microscopic technique in learning the endoscopic technique.

The majority of the studies used tragal cartilage-perichondrium with two studies mentioning that they used a variation of this graft, the butterfly graft. More than 20 types of grafting techniques have been described using cartilage as the graft material and these have been through microscopic techniques (31). Tragal cartilage-perichondrium, also known as composite graft, has the advantage of one using a single incision rather than a separate post auricular incision

Table 1. Heavy metal contents ($\mu\text{g/g}$) of a commercial mesh and mosquito nets after wet digestion (mean of 3 replicates \pm standard deviation)

Author	Country	Average age (age range)	Mean air-bone gap	Type of graft	Anesthesia	Endoscope used	Follow-up	Graft take (%)
Tseng CC (2017)	Taiwan	51.1 +/-15.5 (N/A)	11.3	Tragal perichondrium	LA & GA	0 degrees :4mm, 18 cm long & 3mm, 14 cm long	12.9 months(N/A)	95.3
Lade (2013)	India	28.30 +/-9.39 (N/A)	10.37	TFG	LA & GA	4 mm: 0 degree	6 months	83.3
Furukuwa (2014)	Japan	51.8 (8-82 years)	10.3	Connective tissue, postauricular	GA	2.7mm: 0,30 & 70 degrees	9.8 months (5-18 months)	84
Harugop (2008)	India	N/A (15-65 years)	N/A	TFG	GA & LA	4mm, 17cm long: 0 degree	6 months	82
Mohindra (2010)	India	N/A (6 to 58 years)	9.96	TFG	GA/LA	4mm: 0 and 30 degrees	N/A (6 months to 2.9 years)	91.5
Yadav (2009)	India	N/A (18-45years)	80% closed with less than 10dB	TFG	LA	1.7mm, 100mm long: 0, 30, 90 degrees	8 weeks	80
Usami (2001)	Japan	38.4 (6-59 years)	14.8	TFG/Connective tissue	LA & GA	3mm & 1.5mm	Mean 24.5 (6-36 months)	82
Karhuketo (2001)	Finland	37.8 (8-75 years)	11	TFG	GA	1.7mm, 112-114mm long: 0, 30,90 degrees	12 months duration	80
Ayache (2013)	France	53 (11-87 years)	9.8	tragal perichondrium-cartilage graft		4mm, 6cm long: 0 degree	12 months duration	96
El Guindy (1992)	Egypt		83% closed to Less than 10dB	Tragal perichondrium		4mm or 2.7mm, 18 cm long: 0, 30 and 70 degrees		91.7
Raj (2001)	India		8	Tragal perichondrium	LA	4mm	2.5 months duration	90
Celik (2015)	Turkey	40.3 (16-62 years)	6.6	tragal cartilage, composite	LA & GA	4mm, 18 cm long: 0 degree	mean 12.4 months (6-24months)	87.5
Migirov (2015)	Israel	10.7 (5 to 16 years)	9.8	tragal cartilage, composite	GA	3mm, 14mm long: 0 and 30 degrees	12 months duration	100
Garcia Lde (2016)	Brazil	32.2 +/-6.0	N/A	tragal cartilage, composite	GA	4mm, 18 cm long: 0 degree	3 months	86.4
Akyigit (2017)	Turkey	13.9 (8-17 years)	10.54	tragal perichondrium-cartilage graft	GA	2.7mm: 0 degree	12 months duration	93.7
Nassif (2015)	Italy	N/A (5 to 16 years)	6.6	tragal perichondrium	GA	2.7mm, 11 cm long & 4mm, 18 cm long: 0 degree	6 months duration	90.9
Eren (2015)	Turkey	33.5 +/-12.4 (N/A)	8.5	tragal cartilage, composite	N/A	4mm: 0 degree	11.8 months +/-3.7%	95.5
Ozgur (2016)	Turkey	31 (9-56 years)	9.4	butterfly inlay, composite	GA	4 or 2.7mm, 18 cm long: 0 or 45 degrees	14.4 (6-25 months)	97.8
Omran (2012)	Egypt	9.43 (9 to 57 years)	7.09	tragal cartilage, composite, butterfly	GA	2.7mm, 9 cm long: 0 degree	7.75 months (N/A)	73.3
Dundar (2014)	Turkey	12.40 +/-2.36 (7-16 years)	12.28	tragal perichondrium-cartilage graft	GA	2.7mm, 6cm or 4mm, 16cm	12 months duration	87.5
Kostantinidis (2012)	Greece	47.6 (17 -68 years)		fat	LA	N/A	6 months duration	85.4

as is used in temporalis fascia graft. The temporalis fascia graft (TFG) may not be as resilient to infections. The meta-analysis for type I Tympanoplasty by Tan et al(26) showed that cartilage (90.80%) had a small but significant superior closure rate to TFG (88.00%). Proper patient and graft material selection can affect the outcome of myringoplasty procedures and one has to be aware of these factors when interpreting the results of the myringoplasty procedures. Another option that has been used is biomaterials such as bacterial cellulose. Bacterial cellulose is a safe graft material that is inexpensive, easy-to-use, and provides a high success rate in small tympanic membrane perforations. However, further studies of large tympanic membrane perforations with more samples and long-term follow-up are required (32). The impact of the size of the perforation is controversial. Some studies have shown that size of the perforation matters and that the bigger the perforation in Type I tympanoplasty, the lower the success rate (33). Other studies have shown that size of the perforation has no impact on the closure rate of the perforation (34).

It was not clear from the studies included in this review, as to whether or not, they used overlay or underlay technique. Tan et al(26) showed that there was no significant difference between the grafting technique used (underlay, overlay and inlay) in type I tympanoplasty.

In this review, the follow-up period ranged between 2 to 36 months. A meta-analysis by Tan et al (26) demonstrated that there was no correlation between follow-up rates and success rates in Type I tympanoplasty. However, they recommend that future studies should aim to follow-up graft success for a minimum of 12 months. The other advantage of long-term follow-up is to exclude cholesteatoma formation especially bearing in mind that the tympano-meatal flap is not raised in the endoscopic trans-canal method.

With appropriate training the technique can be undertaken by middle level health workers in developing countries. It does not involve the lifting of the TM flap as for the repair of small to medium sized perforations, the benefits of elevating a TM flap are minimal. Elevation of the TM flap has many drawbacks. In particular the tympanic membrane and even ossicular chain can be vulnerable to damage and transection of the chorda tympani may occur in some cases. It may also lead to adhesions within the tympanic cavity (35).

Strengths and limitations

This is a structured systematic review of endoscopic trans-canal myringoplasty. However, we did not include in our analysis other outcomes such as duration of the endoscopic procedure.

Implications for research

A study is proposed which will utilise only the trans-canal endoscopic technique, single graft placement technique and one type of graft material and comparing it to the microscopic technique also using single graft placement technique and one type of graft material. These are confounding factors in assessing the outcomes of endoscopic trans-canal myringoplasty.

Conclusions

Endoscopic trans-canal myringoplasty leads to high graft take-up rates with low mean air-bone gaps. The technique has not been reported in Sub-Saharan Africa but has a potential to play a significant role in surgical management of CSOM in this region.

References

1. Li MG, Hotez PJ, Vrabec JT, Donovan DT. Is Chronic Suppurative Otitis Media a Neglected Tropical Disease? *PLoS Negl Trop Dis* 2015; 9(3):e0003485.
2. Yadav SP, Aggarwal N, Julaha M, Goel A. Endoscope-assisted myringoplasty. *Singapore Med J*. 2009;50 (5):510-2.
3. Usami S, Iijima N, Fujita S, Takumi Y. Endoscopic-assisted myringoplasty. *ORL J Otorhinolaryngol Relat Spec*. 2001;63(5):287-90.
4. Kozin ED, Gulati S, Kaplan AB, Lehmann AE, Remenschneider AK, Landegger LD, Cohen MS, Lee DJ. Systematic review of outcomes following observational and operative endoscopic middle ear surgery. *The Laryngoscope* 2015;125(5):1205-14.
5. Moher D, Liberati A, Tetzlaff J, Altman DG, The PRISMA Group. Preferred Reporting Items for Systematic Reviews and Meta-Analyses: The PRISMA Statement. *PLoS Med* 2009; 6(7): e1000097.
6. The Joanna Briggs Institute. Joanna Briggs Institute Reviewers' Manual: 2011 edition. Adelaide: The Joanna Briggs Institute; 2011
7. Raj A, Meher R. Endoscopic transcanal myringoplasty-A study. *Indian J Otolaryngol Head Neck Surg*. 2001;53(1):47-9.
8. Harugop AS, Mudhol RS, Godhi RA. A comparative study of endoscope assisted myringoplasty and microscope assisted myringoplasty. *Indian J Otolaryngol Head Neck Surg*. 2008 ;60(4):298-302.
9. Ayache S. Cartilaginous myringoplasty: the endoscopic transcanal procedure. *Eur Arch Otorhinolaryngol*. 2013 ;270(3):853-60.
10. Mohindra S, Panda NK. Ear surgery without microscope; is it possible. *Indian J Otolaryngol Head Neck Surg*. 2010 ;62(2):138-41.
11. Tseng CC, Lai MT, Wu CC, Yuan SP, Ding YF. Comparison of endoscopic transcanal myringoplasty and endoscopic type I tympanoplasty in repairing medium-sized tympanic perforations. *Auris Nasus Larynx*. 2017 Jan 21. pii:S0385-8146(16)30429-1..
12. Ozgur A., Dursun E., Erdivanli O.C., Coskun Z.O., Terzi S., Emiroglu G., Demirci M. Endoscopic cartilage tympanoplasty in chronic otitis media. *Journal of Laryngology and Otology* 2015; 129 (11) 1073-1077,.
13. Karhuketo TS, Ilomäki JH, Puhakka HJ. Tympanoscope-assisted myringoplasty. *ORL J Otorhinolaryngol Relat Spec*. 2001;63(6):353-7
14. el-Guindy A. Endoscopic transcanal myringoplasty. *J Laryngol Otol*. 1992;106(6):493-5.
15. Furukawa T, Watanabe T, Ito T, Kubota T, Kakehata S. Feasibility and advantages of transcanal endoscopic myringoplasty. *Otol Neurotol*. 2014;35(4):e140-5. doi: 10.1097/MAO.0000000000000298.
16. Lade H, Choudhary SR, Vashishth A. Endoscopic vs microscopic myringoplasty: a different perspective. *Eur Arch Otorhinolaryngol*. 2014;271(7):1897-902.
17. Migirov L, Wolf M. Transcanal microscope-assisted endoscopic myringoplasty in children. *BMC Pediatr*. 2015 ;15:32. doi: 10.1186/s12887-015-0351-6.
18. Celik H, Samim E, Oztuna D. Endoscopic "Push-Trough" Technique Cartilage Myringoplasty in Anterior Tympanic Membrane Perforations. *ClinExp Otorhinolaryngol*. 2015 ;8(3):224-9.

19. Eren SB, Tugrul S, Ozucer B, Veyseller B, Aksoy F, Ozturan O. Endoscopic Transcanal Inlay Myringoplasty: Alternative Approach for Anterior Perforations. *Otolaryngol Head Neck Surg.* 2015 ;153(5):891-3.
20. Nassif N, Berlucchi M, Redaelli de Zinis LO. Tympanic membrane perforation in children: Endoscopic type I tympanoplasty, a newly technique, is it worthwhile? *Int J Pediatr Otorhinolaryngol.* 2015 ;79(11):1860-4.
21. Akyigit A, Karlidag T, Keles E, Kaygusuz I, Yalcin S, Polat C, Eroglu O. Endoscopic cartilage butterfly myringoplasty in children. *Auris Nasus Larynx.* 2017 ;44(2):152-155.
22. Garcia Lde B, Moussalem GF, Andrade JS, Mangussi-Gomes J, Cruz OL, PenidoNde O, Testa JR. Transcanal endoscopic myringoplasty: a case series in a university center. *Braz J Otorhinolaryngol.* 2016;82(3):321-5.
23. Dundar R., Kulduk E., Soy FK., Aslan M., Hanci D., Muluk N.B., Cingi C. Endoscopic versus microscopic approach to type I tympanoplasty in children. *International Journal of Pediatric Otorhinolaryngology* 2014; 78 (7) 1084-1089,.
24. Omran AA. Endoscopic bivalve inlay cartilage myringoplasty for central perforations: preliminary report. *Egyptian Journal of Ear, Nose, Throat and Allied Sciences* 2012 ;13(1):37-42.
25. Konstantinidis I, Malliari H, Tsakiropoulou E, Constantinidis J. Fat myringoplasty outcome analysis with otoendoscopy: who is the suitable patient?. *Otology & Neurotology.* 2013 ;34(1):95-9.
26. Tan, H. E., P. L. Santa Maria, R. H. Eikelboom, K. S. Anandacoomaraswamy and M. D. Atlas . "Type I Tympanoplasty Meta-Analysis: A Single Variable Analysis." *Otol Neurotol* 2016 37(7): 838-846.
27. Hardman, J., J. Muzaffar, P. Nankivell and C. Coulson . "Tympanoplasty for Chronic Tympanic Membrane Perforation in Children: Systematic Review and Meta-analysis." *Otol Neurotol* 2015; 36(5): 796-804.
28. Anzola JF, Nogueira JF. Endoscopic Techniques in Tympanoplasty. *Otolaryngol Clin North Am.* 2016 ;49(5):1253-64.
29. Lakpathi G, Sudarshan Reddy L, Anand. Comparative Study of Endoscope Assisted Myringoplasty and Microscopic Myringoplasty. *Indian J Otolaryngol Head Neck Surg.* 2016 ;68(2):185-90.
30. De Zinis, L. O., M. Berlucchi and N. Nassif (2017). "Double-handed endoscopic myringoplasty with a holding system in children: Preliminary observations." *Int J Pediatr Otorhinolaryngol* 2017; 96: 127-130.
31. Tos M. Cartilage tympanoplasty methods: proposal of a classification. *Otolaryngol Head Neck Surg* 2008; 139:747-58.
32. Biskin, S., M. Damar, S. N. Oktem, E. Sakalli, D. Erdem and O. Pakir . "A new graft material for myringoplasty: bacterial cellulose." *Eur Arch Otorhinolaryngol* 2016; 273(11): 3561-3565.
33. Lee P, Kelly G, Mills RP. Myringoplasty: does the size of the perforation matter? 1. *Clinical Otolaryngology & Allied Sciences.* 2002 Oct 1;27(5):331-4.
34. Wasson JD, Papadimitriou CE, Pau H. Myringoplasty: impact of perforation size on closure and audiological improvement. *The Journal of Laryngology & Otology.* 2009 Sep;123(9):973-7.
35. Tseng CC, Lai MT, Wu CC, Yuan SP, Ding YF. Endoscopic Transcanal Myringoplasty for Anterior Perforations of the Tympanic Membrane. *JAMA Otolaryngol Head Neck Surg.* 2016;142(11):1088-1093.

Peer Reviewed (Uncorrected Proof)**Competing Interests:** None declared.**Received:** 26 Nov 2018 • **Revised:** 12 Mar 2019**Accepted:** 29 Apr 2019 • **Published:** 30 Apr 2019

Cite this article as: Mulwafu W, Strachan D, Singano E, Banerjee A, Haddow K, Raine C. Endoscopic trans-canal myringoplasty: Relevance for sub-Saharan Africa? A systematic review. *E Cent Afr J Surg.* 2019;24(1):61-66. <https://dx.doi.org/10.4314/ecajs.v24i1.9>.

© Mulwafu et al. This is an open-access article distributed under the terms of the Creative Commons Attribution License, which permits unrestricted use, distribution, and reproduction in any medium, provided the original author and source are properly cited. To view a copy of the license, visit <http://creativecommons.org/licenses/by/4.0/>. When linking to this article, please use the following permanent link: <https://dx.doi.org/10.4314/ecajs.v24i1.9>.