

CASE REPORT

Surgical management of a large, symptomatic renal angiomyolipoma: A case report from a tertiary hospital in Ndola, Zambia

Luyando Simunyama, Kamwi Mundia, Khumbolakhe Fisonga, Boniface Kaela, Simon Mukosai, Bright Chirengendure, Seke M.E. Kazuma

Department of Surgery, Ndola Teaching Hospital, Ndola, Zambia

Correspondence: Dr Seke M.E. Kazuma (sekekazuma@gmail.com)

© 2024 L. Simunyama et al. This corrected proof has been published before the article's inclusion in an upcoming issue of the *East and Central African Journal of Surgery* so that it can be accessed and cited as early as possible. This open access article is licensed under a Creative Commons Attribution 4.0 International License (<http://creativecommons.org/licenses/by/4.0/>), which permits unrestricted use, distribution, and reproduction in any medium, provided you give appropriate credit to the original author(s) and the source, provide a link to the Creative Commons license, and indicate if changes were made.



East Cent Afr J Surg
Published 29 April 2024

Abstract

Renal angiomyolipomas (AMLs) are classified as typical (classic) or atypical renal AMLs. Eighty per cent of renal AMLs occur sporadically, with a female preponderance (4:1) and a mean age of presentation of about 40 years. The remaining 20% are associated with genetic disorders. Most AMLs are discovered incidentally during imaging or surgery performed for other conditions. Treatment options include partial nephrectomy (nephron-sparing surgery), radical nephrectomy, embolization, cryoablation, or percutaneous radiofrequency ablation. We report a case of renal AML managed by radical nephrectomy at Ndola Teaching Hospital in north-central Zambia.

Keywords: renal angiomyolipoma, benign renal tumours, radical nephrectomy, nephron-sparing surgery, Zambia

Introduction

Renal angiomyolipomas (AMLs) are benign perivascular epithelioid tumours that arise from the mesenchyme of the kidney.[1]-[3] In 1900, Grawitz described renal AMLs as tumours composed of fat, muscle, and blood vessels; hence, renal AMLs are classified as triphasic tumours.[4] In the general population, autopsies and population-based ultrasonography studies have revealed AML detection rates between 0.13% and 0.44%. [5]-[8] The pathogenesis of renal AMLs is not well established, but it has been associated with the mTOR (mammalian target of rapamycin) pathway and tuberous sclerosis complex (TSC).[5],[9] Notably, while nearly half of patients with TSC have at least 1 AML, about 80% of AMLs occur in people without TSC.[5],[10]-[13]

Types of renal AML have been described based on their histologic appearance as typical or classic renal AML and atypical renal AML (monophasic or epithelioid).[2],[14] The classic type is more common and triphasic and tends to be benign, while the atypical type makes up 10% of renal AMLs, has a variable amount of fat, tends to be associated with malignant transformation, and is locally aggressive at diagnosis. Immunohistochemistry, by way of smooth muscle cell markers (caldesmon and smooth muscle actin) and melanocyte cell markers (HMB [human melanoma black]-45), must be used to distinguish renal AML from renal cell carcinoma.

[14] A third type tends to have solid and cystic areas on histologic examination and is referred to as AML with epithelial cysts.

Eighty per cent of renal AMLs are sporadically detected, with a female preponderance (expressing oestrogen and progesterone receptors), in a female-to-male ratio of 4:1, and with a mean age of 40 years at diagnosis; 20% are inherited in association with genetic disorders.[1],[2],[5]-[19] Sporadic renal AMLs tend to present with a diameter <4 cm and are solitary, whereas hereditary renal AMLs are larger and often bilateral.[9] Hereditary renal AMLs present in young patients and are associated with TSC and pulmonary lymphangiomyomatosis (LAM).[5],[9],[14]

Sporadic renal AMLs tend to be asymptomatic and are incidental findings on imaging or during surgery for other conditions in 80% of patients, while the 20% of patients with inherited renal AMLs tend to be symptomatic due to haemorrhage from microaneurysms; symptoms can range from abdominal pain to haemorrhagic shock.[15],[18],[19] Imaging by computed tomography (CT) is essential for diagnosis.[2] An indication for treatment, according to the European Association of Urology, is suspicion of malignancy and/or presence of symptoms relating to size, with a biopsy done to rule out malignancy.[20]

We report a case of renal AML that was managed at Ndola Teaching Hospital in north-central Zambia.

[PAGE NUMBERS NOT FOR CITATION PURPOSES]

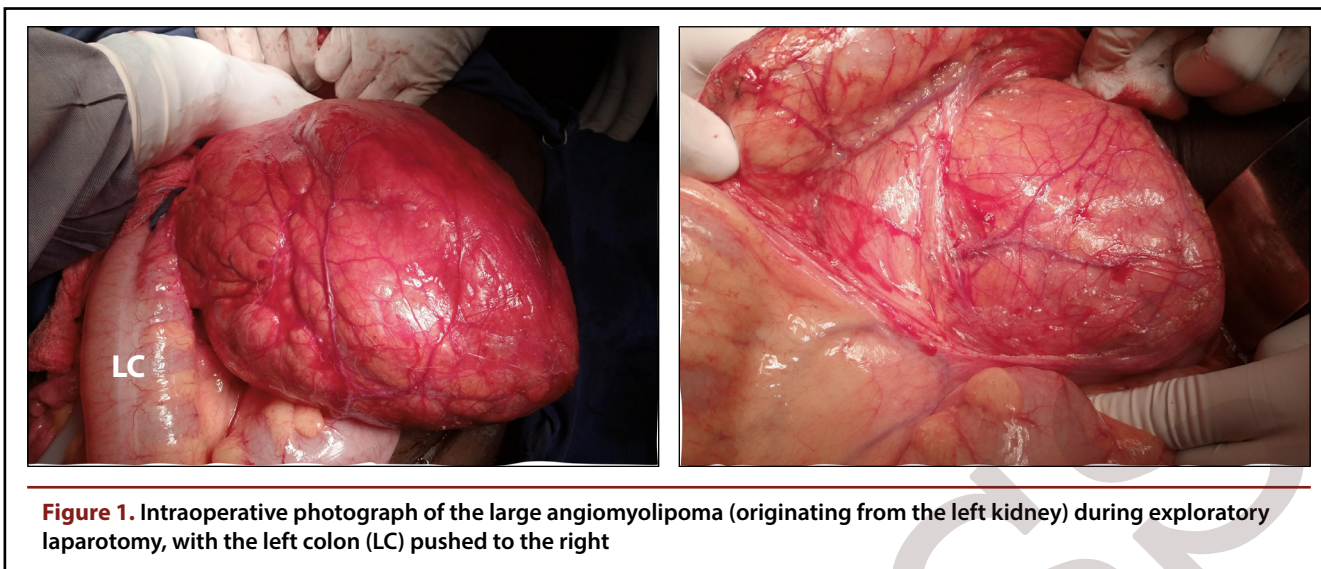


Figure 1. Intraoperative photograph of the large angiomyolipoma (originating from the left kidney) during exploratory laparotomy, with the left colon (LC) pushed to the right

Case presentation

A 37-year-old woman was evaluated for a left-sided abdominal mass, present for 5 months and characterized by gradual enlargement and intermittent abdominal pain over the preceding 2 months. The systemic review revealed no significant findings. She reported no alterations in bowel habits, weight loss, symptoms suggestive of anaemia, or symptoms suggestive of tuberous sclerosis. Her medical history was unremarkable except for a caesarean section for a large baby 2 months prior to presentation. No abdominal mass was documented during antenatal visits; however, the obstetrician noted a mass in the left upper abdominal quadrant during the caesarean section but did not determine its origin. The patient reported occasional alcohol consumption but had never smoked.

Her general condition was good, with an ECOG (Eastern Cooperative Oncology Group) performance status of 1. She had no comorbidities such as hypertension or diabetes, and she was HIV negative. Physical examination revealed a firm, smooth, fixed, nontender mass extending to the pubic region, arising from the left upper abdominal quadrant, and measuring 25 × 15 cm. It was possible to palpate below the mass but not above it, and it lacked a distinct notch.

Laboratory tests revealed a haemoglobin level of 13.3 g/dL and a platelet count of 241,000 cells/ μ L, both within the respective normal ranges. Results from kidney and liver function tests also fell within normal limits. Tests for the tumour markers CEA (carcinoembryonic antigen), CA19-9 (carbohydrate antigen 19-9), and CA125 (cancer antigen 125) yielded results within normal limits. The abdominal ultrasonography report identified a complex cystic mass but incorrectly indicated it as arising from the left ovary. A subsequent CT scan accurately depicted the complex mass in the left kidney, primarily consisting of fatty tissue, indicative of a renal AML. Kidney and brain CT revealed no evidence of tubers. Following a thorough consultation, the patient consented to undergo surgery, with the possibility of either a partial or radical nephrectomy being discussed and agreed upon.

Summary of operative steps and patient management:

1. Under general anaesthesia and with endotracheal intubation, a midline incision was made to access the abdomen. The midline incision was selected because of the tumour's wide horizontal diameter, which spanned across the midsagittal plane. [21]-[23]
2. A large left compartment tumour composed of blood vessels, fat, and muscle was identified, with minimal remaining renal tissue. The tumour displaced the left and sigmoid colon medially without invasion (Figure 1).
3. Deposits were noted on the mesentery of the jejunum, approximately 5 cm from the ligament of Treitz. A biopsy was obtained (Figure 2), and histopathologic examination indicated chronic inflammation.
4. Small bowel mesenteric lymphadenopathy was observed, and a biopsy was collected (Figure 2).
5. The left descending colon was mobilized to the right side of the abdomen. A left compartment excision (en bloc resection of the left kidney, left adrenal gland, and left ureter) was performed to minimize the risk of malignant transformation (Figure 3).
6. The excised tumour weighed 1.2 kg.
7. Postoperative recovery was uncomplicated.
8. Histopathologic examination confirmed the diagnosis of benign renal AML. The mesenteric lymph node biopsy showed sinus histiocytosis, a nonspecific inflammatory finding.

The patient was discharged 7 days postoperatively and followed up for 3 months without complications or wound infection.

[PAGE NUMBERS NOT FOR CITATION PURPOSES]

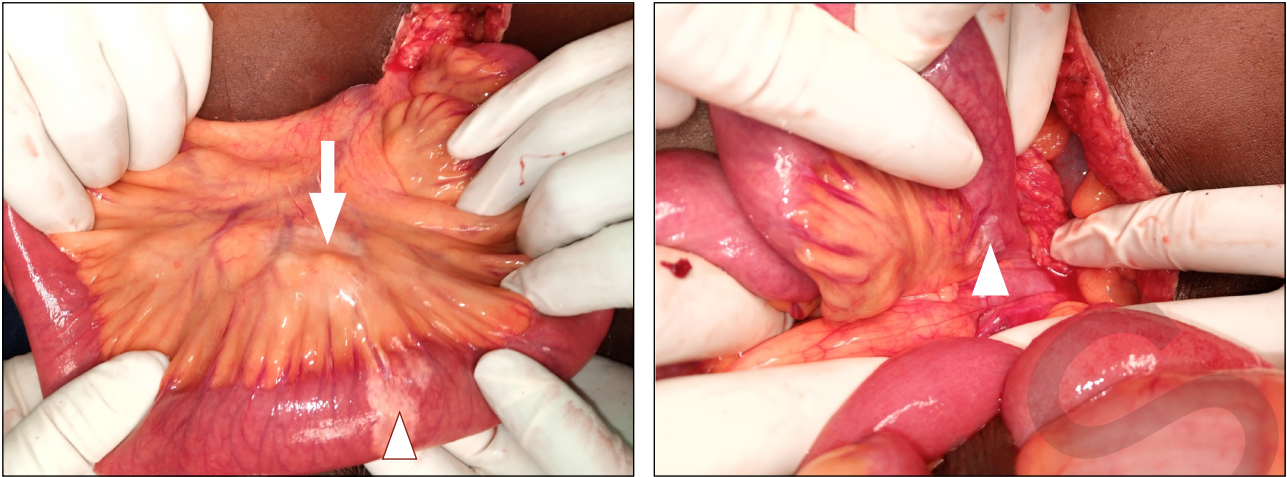


Figure 2. Intraoperative photograph showing mesenteric lymphadenopathy (arrow) and suspicious bowel deposits (arrowheads)

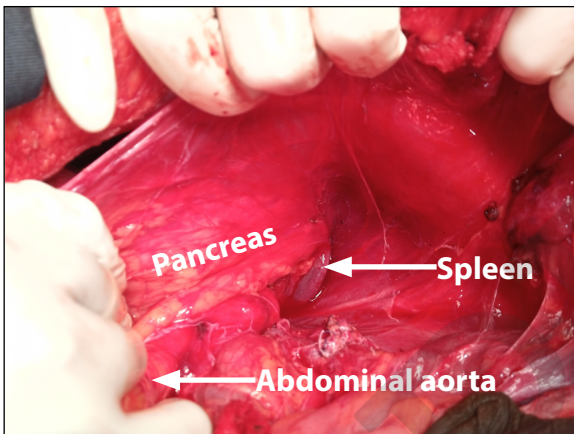


Figure 3. Intraoperative photograph showing total compartment excision with removal of the left kidney, adrenal gland and ureter en bloc in the Gerota fascia

Discussion

The majority of renal AMLs are asymptomatic and discovered incidentally during imaging studies or surgical procedures performed for other indications.[2],[9] However, 20% of renal AMLs present with symptoms related to the abdominal mass or tumour bleeding. This can manifest as haematuria, acute abdomen, or life-threatening haemorrhagic shock due to the rupture of microaneurysms within the AML vasculature.[15],[18],[19] Our patient presented with an abdominal mass that was initially painless but became intermittently painful following manipulation during caesarean section. Histopathologic analysis confirmed bleeding within the tumour.

Technological advancements in imaging have increased the likelihood of incidental detection, even for small AMLs.[24] For our patient, contrast-enhanced abdominal CT enabled a confident diagnosis. The classic appearance of a typical AML via abdominal ultrasonography is a hyper-

echoic tumour with posterior acoustic shadowing due to the presence of fat, blood vessels, and muscle.[2],[24] When distinguishing between AML and renal cell carcinoma presents a diagnostic challenge, abdominal CT provides excellent sensitivity and specificity.

Current European Association of Urology guidelines recommend intervention for symptomatic tumours, tumours in women of childbearing age, cases with suspected malignancy, patients with poor follow-up adherence, and emergency presentations.[20] Our patient met multiple criteria, being of childbearing age and presenting with a symptomatic tumour that had recently increased in size following manipulation during caesarean section. The role of AML size as the sole threshold for surgical intervention remains a subject of debate.

Active surveillance with annual abdominal CT or ultrasonographic examination is appropriate for small AMLs (diameter <4 cm).[2],[15] For AMLs >4 cm in diameter, patients at risk of malignant transformation, or those with epithelioid-type AMLs awaiting therapeutic intervention, imaging should be performed every 6 months for 5 years, then annually if the condition remains stable.[2],[20],[24]

Treatment options include selective renal artery embolization or surgical excision (partial or radical nephrectomy).[2],[20],[24] Embolization is particularly useful for controlling retroperitoneal haemorrhage and managing massive tumours that present surgical challenges.[24] Given the lack of embolization facilities at our centre, surgical excision is our primary treatment modality. For this patient, radical nephrectomy was performed because of the patient's risk of malignancy, as suggested by the presence of lymphadenopathy. Nephron-sparing surgery is preferred for smaller tumours and those with a low risk of malignancy, especially in patients with TSC or LAM.[20] Cryoablation and percutaneous radiofrequency ablation are alternatives to embolization for asymptomatic patients with tumours <4 cm in diameter.[9],[20],[24] Medical management with mTOR inhibitors, such as sirolimus or everolimus, can reduce tumour size and is an option for patients with TSC and LAM who exhibit progressive AML growth.[2],[9],[14],[20]

[PAGE NUMBERS NOT FOR CITATION PURPOSES]

Our patient requires active surveillance with abdominal CT or ultrasonography every 6 months due to the increased risk of malignancy associated with a tumour diameter >4 cm.

Conclusions

Renal AMLs are benign mesenchymal kidney tumours. While mostly sporadic and asymptomatic, they often present incidentally. Renal AMLs are rare and can reach a significant size before diagnosis. Intratumoral bleeding is a common precipitant for hospital presentation. Symptoms arise from haemorrhagic microaneurysms and range from abdominal pain to haemorrhagic shock. Partial nephrectomy (nephron-sparing surgery) remains the primary treatment for large AMLs, although embolization is gaining popularity. Postoperative active surveillance with imaging is essential.

Acknowledgements: We thank the management of Ndola Teaching Hospital for their support.

References

1. El Sayed Esheba G, El Sayed Esheba N. Angiomyolipoma of the kidney: clinicopathological and immunohistochemical study. *J Egypt Natl Canc Inst.* 2013;25(3):125-134. doi:10.1016/j.jnci.2013.05.002 [View Article] [PubMed]
2. Iorga L, Costache RS, Anghel R, Bratu I, Manea M, Marcu D. Renal angiomyolipoma - a short review of the literature. *Rom J Mil Med.* 2019;122(1):39-45. doi:10.55453/rjmm.2019.122.1.6 [View Article]
3. Ceifo W, Al-Khaldy O, Al-Shirbini M. A giant angiomyolipoma of the kidney: a case report. *Kuwait Med J.* 2017;49(1):72-75.
4. Grawitz P. Demonstration eines grossen Angio-Myo-Lipoma der Niere. *Dtsch Med Wochenschr.* 1900;26:290.
5. Nelson CP, Sanda MG. Contemporary diagnosis and management of renal angiomyolipoma. *J Urol.* 2002;168(4 Pt 1):1315-1325. doi:10.1016/S0022-5347(05)64440-0 [View Article] [PubMed]
6. Fujii Y, Ajima J, Oka K, Tosaka A, Takehara Y. Benign renal tumors detected among healthy adults by abdominal ultrasonography. *Eur Urol.* 1995;27(2):124-127. doi:10.1159/000475142 [View Article] [PubMed]
7. Hajdu SI, Foote FW Jr. Angiomyolipoma of the kidney: report of 27 cases and review of the literature. *J Urol.* 1969;102(4):396-401. doi:10.1016/s0022-5347(17)62157-8 [View Article] [PubMed]
8. Fittschen A, Wendlik I, Oetzuerk S, et al. Prevalence of sporadic renal angiomyolipoma: a retrospective analysis of 61,389 in- and out-patients. *Abdom Imaging.* 2014;39(5):1009-1013. doi:10.1007/s00261-014-0129-6 [View Article] [PubMed]
9. Wang SF, Lo WO. Benign neoplasm of kidney: angiomyolipoma. *J Med Ultrasound.* 2018;26(3):119-122. doi:10.4103/JMUJMU_48_18 [View Article] [PubMed]
10. O'Hagan AR, Ellsworth R, Secic M, Rothner AD, Brouhard BH. Renal manifestations of tuberous sclerosis complex. *Clin Pediatr (Phila).* 1996;35(10):483-489. doi:10.1177/000992289603501001 [View Article] [PubMed]
11. Webb DW, Kabala J, Osborne JP. A population study of renal disease in patients with tuberous sclerosis. *Br J Urol.* 1994;74(2):151-154. doi:10.1111/j.1464-410x.1994.tb16577.x [View Article] [PubMed]
12. Cook JA, Oliver K, Mueller RF, Sampson J. A cross sectional study of renal involvement in tuberous sclerosis. *J Med Genet.* 1996;33(6):480-484. doi:10.1136/jmg.33.6.480 [View Article] [PubMed]

13. Stillwell TJ, Gomez MR, Kelalis PP. Renal lesions in tuberous sclerosis. *J Urol.* 1987;138(3):477-481. doi:10.1016/s0022-5347(17)43234-4 [View Article] [PubMed]
14. Vos N, Oyen R. Renal angiomyolipoma: the good, the bad, and the ugly. *J Belg Soc Radiol.* 2018;102(1):41. doi:10.5334/jbsr.1536 [View Article] [PubMed]
15. Swärd J, Henrikson O, Lyrdal D, Peeker R, Lundstam S. Renal angiomyolipoma-patient characteristics and treatment with focus on active surveillance. *Scand J Urol.* 2020;54(2):141-146. doi:10.1080/21681805.2020.1716066 [View Article] [PubMed]
16. Kuusk T, Biancari F, Lane B, et al. Treatment of renal angiomyolipoma: pooled analysis of individual patient data. *BMC Urol.* 2015;15:123. doi:10.1186/s12894-015-0118-2 [View Article] [PubMed]
17. Henske EP, Ao X, Short MP, et al. Frequent progesterone receptor immunoreactivity in tuberous sclerosis-associated renal angiomyolipomas. *Mod Pathol.* 1998;11(7):665-668. [PubMed]
18. Bissler JJ, Kingswood JC. Renal angiomyolipomata. *Kidney Int.* 2004;66(3):924-934. doi:10.1111/j.1523-1755.2004.00838.x [View Article] [PubMed]
19. Magabe PC, Otele W, Mugambi LM. Large aneurysm in renal angiomyolipoma causing life-threatening retroperitoneal hemorrhage. *Afr J Urol.* 2014;20(4):193-196. doi:10.1016/j.afju.2014.05.003 [View Article]
20. Fernández-Pello S, Hora M, Kuusk T, et al. Management of sporadic renal angiomyolipomas: a systematic review of available evidence to guide recommendations from the European Association of Urology Renal Cell Carcinoma Guidelines Panel. *Eur Urol Oncol.* 2020;3(1):57-72. doi:10.1016/j.euo.2019.04.005 [View Article] [PubMed]
21. Anastasiou J, Karatzas T, Felekouras E, et al. Radical nephrectomy with transperitoneal subcostal incision for large and locally advanced tumors of the right kidney. *Anticancer Res.* 2012;32(11):5023-5029. [PubMed]
22. Oyiedo RJ, Robertson JC, Whithaus K. Surgical challenges in the treatment of a giant renal cell carcinoma with atypical presentation: a case report. *Int J Surg Case Rep.* 2016;24:63-66. doi:10.1016/j.ijscr.2016.05.010 [View Article] [PubMed]
23. Khayyamfar F, Gholfam F, Delavar P, Mirzabozorg M, Esfahani NH, Khayyamfar A. A case report of the world largest spindle cell renal tumor (9 kg) with longest survival, removed by innovative technique. *Urol Case Rep.* 2022;42:102011. doi:10.1016/j.eucr.2022.102011 [View Article] [PubMed]
24. Andersen PE, Thorlund MG, Wennevik GE, Pedersen RL, Lund L. Interventional treatment of renal angiomyolipoma: immediate results and clinical and radiological follow-up of 4.5 years. *Acta Radiol Open.* 2015;4(7):2058460115592442. doi:10.1177/2058460115592442 [View Article] [PubMed]

Peer reviewed

Competing interests: S.M.E.K. is a deputy editor of the East and Central African Journal of Surgery but was not involved in the processing or peer review of this article, and he did not have any influence on the decision to accept this article for publication. The other authors declare that they have no competing interests related to this work.

Received: 24 Feb 2022 • **Revised:** 27 Oct 2022, 29 Jan 2023, 26 Mar 2023

Accepted: 20 Sep 2023 • **Published:** 29 Apr 2024

Cite this article as: Simunyama L, Munda K, Fisonga K, et al. Surgical management of a large, symptomatic renal angiomyolipoma: a case report from a tertiary hospital in Ndola, Zambia. *East Cent Afr J Surg.* Published online April 29, 2024. doi:10.4314/ecajs.v28i3.5

© L. Simunyama et al. This is an open-access article distributed under the terms of the Creative Commons Attribution License, which permits unrestricted use, distribution, and reproduction in any medium, provided the original author and source are properly cited. To view a copy of the license, visit <http://creativecommons.org/licenses/by/4.0/>.