

# CASE REPORT

## A 29-year-old man with bilateral polyorchidism and testicular tuberculosis managed at a tertiary hospital in Addis Ababa, Ethiopia

Aklilu Getachew, Nathan K. Suga

Myungsung Medical College and Department of Surgery, MCM Comprehensive Specialized Hospital, Addis Ababa, Ethiopia

Correspondence: Dr Aklilu Getachew ([getake1715@gmail.com](mailto:getake1715@gmail.com))

© 2023 Aklilu G. & N.K. Suga. This corrected proof has been published before the article's inclusion in an upcoming issue of the *East and Central African Journal of Surgery* so that it can be accessed and cited as early as possible. This open access article is licensed under a Creative Commons Attribution 4.0 International License (<http://creativecommons.org/licenses/by/4.0/>), which permits unrestricted use, distribution, and reproduction in any medium, provided you give appropriate credit to the original author(s) and the source, provide a link to the Creative Commons license, and indicate if changes were made.



East Cent Afr J Surg  
Published 7 July 2023

### Abstract

Polyorchidism (also known as polyorchism) is a rare anomaly characterized by the presence of at least 1 supernumerary testis and is typically an incidental finding. Bilateral polyorchidism is particularly rare, with only 10 reported cases in the literature. Polyorchidism may be associated with a variety of complications, including malignancy.

A 29-year-old man with a history of bone tuberculosis presented to our centre with a painless scrotal mass. The diagnosis of bilateral polyorchidism with concurrent testicular tuberculosis was reached after comprehensive physical examination, imaging, biopsy, and exploratory surgery. The patient's testes were discovered to be in pairs, fused within both the right and left hemiscrotums. The management strategy consisted of tuberculosis medication and regular follow-up.

Supernumerary testes may be found within or outside the scrotum. Ultrasonography is the preferred diagnostic modality. In the absence of complications or associated conditions, no further intervention is typically required. This case report expands our understanding of polyorchidism and outlines a comprehensive approach to patient management. Moreover, given the rarity of reported bilateral polyorchidism, this case provides further insights into this unusual medical condition.

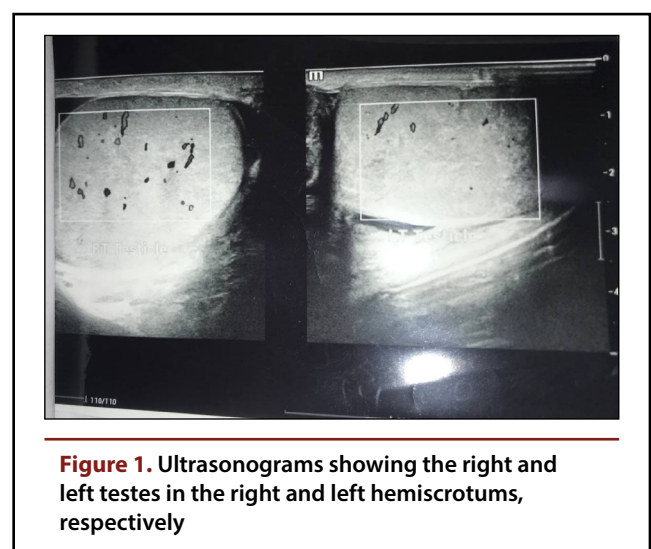
**Keywords:** polyorchidism, polyorchism, bilateral polyorchidism, supernumerary testes, testicular tuberculosis, Ethiopia

### Introduction

**P**olyorchidism (also called polyorchism) is a rare congenital anomaly characterized by the presence of 1 or more supernumerary testes. Just over 200 cases have been reported in the literature, and most were asymptomatic and discovered incidentally.[1] Triorchidism is the most prevalent form, with 4 and 5 testes previously reported in 10 and a single patient, respectively, although the latter lacked histologic confirmation.[1] The additional testes are predominantly found within the scrotum (75%), with the remainder discovered in the inguinal region (20%) or abdominally/retroperitoneally (5%).[1] We present a case of bilateral polyorchidism in conjunction with testicular tuberculosis.

### Case presentation

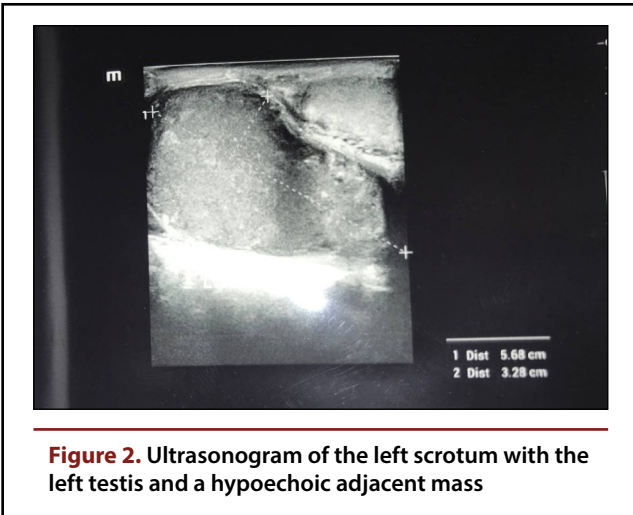
A 29-year-old man presented to our general medical hospital in Addis Ababa, Ethiopia, with nontender bilateral scrotal swelling and a history of treated bone tuberculosis. Examination revealed palpable testes of normal size and firm consistency in both the right and left hemiscrotums, with addi-



**Figure 1.** Ultrasonograms showing the right and left testes in the right and left hemiscrotums, respectively

tional, similarly sized and consistent masses also identified. Ultrasonographic examination revealed hypoechoic hemiscrotal masses measuring 5.7 cm × 3 cm (right) and

[PAGE NUMBERS NOT FOR CITATION PURPOSES]



**Figure 2.** Ultrasonogram of the left scrotum with the left testis and a hypoechoic adjacent mass

5.7 cm × 3.3 cm (left), following the epididymal outline and displaying peripheral calcific foci (Figure 1, Figure 2). Fine-needle aspiration (FNA) cytologic examination confirmed the masses as testes, characterized by ill-formed epithelioid cell granulomas. Acid-fast bacilli detected in the sample indicated tuberculosis infection.

Exploratory surgery through a midscrotal raphe incision revealed 2 fused testes of identical size and shape, sharing the same arteries, epididymis, and vas deferens within the right hemiscrotum (Figure 3). The left hemiscrotum was not explored, and both testes were returned to the scrotum.

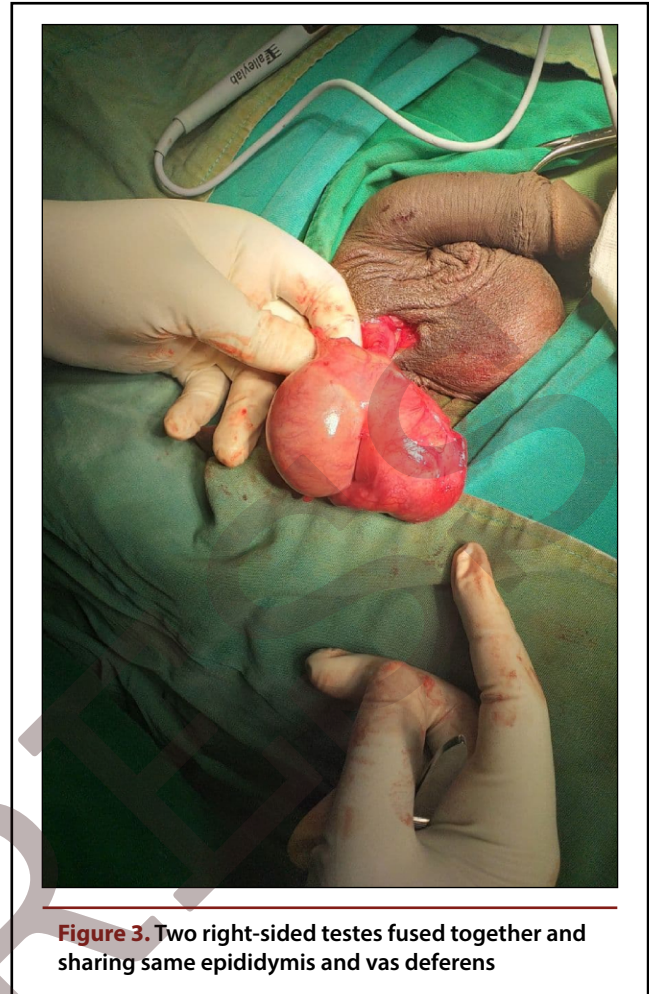
After extensive physical examination, imaging, FNA cytologic examination, and an exploratory procedure, a diagnosis of bilateral polyorchidism with testicular tuberculosis was established.

## Discussion

Polyorchidism, defined as the presence of more than 2 testes in 1 person, is a rare condition typically discovered incidentally in patients between 15 and 25 years of age during surgery for cryptorchidism, testicular exploration, inguinal hernia, or testicular torsion.[2] The first histologically and surgically confirmed case was recorded by Arbuthnot Lane in 1895].[3],[4]

The genesis of the testes occurs from the genital ridge of the mesoderm, giving rise to the gonads, ductal system, and primordial germ cells. In genetic males, the TDF (testis-determining factor) triggers gender determination.[5] Also referred to as the SRY (sex-determining region of the Y chromosome), the TDF is located on the Y chromosome's short arm (Yp11). It transforms the primitive gonads into testes, which subsequently produce testosterone, prompting growth of the mesonephric (wolffian) ducts.[6] The wolffian duct, a primordial urogenital tissue, contributes to the formation of the epididymides, vasa deferentia, seminal vesicles, and common ejaculatory duct following male sex determination.[7]

Among polyorchidism cases, triorchidism is the most common. The specific pathogenetic mechanisms underlying polyorchidism remain elusive, but several theories propose mechanisms, including duplication of the geni-



**Figure 3.** Two right-sided testes fused together and sharing same epididymis and vas deferens

tal ridge, as well as longitudinal or transverse division of the genital ridge. Leung and Singer have further suggested a classification of embryologic polyorchidism based on embryologic differentiation [1]:

- Type A: The supernumerary testis lacks an epididymis or vas deferens and is unattached to the normally situated testes.
- Type B: The supernumerary testis drains into the epididymis of a normally situated testis and shares a common vas deferens.
- Type C: The supernumerary testis has its own epididymis and vas deferens.
- Type D: There is complete duplication of the testes, epididymides, and vasa deferentia.

According to this classification system, our patient had bilateral type B polyorchidism, with the additional testes attached together in both the right and left hemiscrotums and sharing common vasa deferentia, arterial supplies, and venous drainage.

Most people with polyorchidism present with painless testicular masses. Associated anomalies commonly include cryptorchidism (40%), inguinal hernia (30%), hydrocoele (9%), and testicular malignancy (6%).[8] Our patient's FNA results indicated testicular tuberculosis in the supernumerary right and left testes.

Ultrasonography is the primary diagnostic tool for polyorchidism, with magnetic resonance imaging available for further imaging if necessary for confirmation or to investigate associated anomalies or differential diagnoses.[9] In our patient, the diagnosis was confirmed through the findings of ultrasonography, FNA cytology, and exploratory surgery.

Polyorchidism necessitates no further management if the supernumerary testes are uncomplicated and located in the scrotum. Regular ultrasonographic check-ups are recommended, with orchidopexy required for cryptorchidism and orchiectomy for suspected malignancy.[10] Our patient was initiated on a tuberculosis treatment regimen for the testicular tuberculosis and scheduled for further follow-up, as all testes appeared healthy.

## Conclusions

Polyorchidism is a rare congenital anomaly, with ultrasonography being the primary diagnostic tool. Magnetic resonance imaging may complement the diagnosis if needed. Generally, uncomplicated cases require no further treatment, but patients should undergo regular ultrasonographic follow-up. Any risk of malignancy necessitates the removal of extra testes. For our patient, ultrasonographic and FNA biopsy investigations confirmed the diagnosis, and the patient was scheduled for follow-up. Given the rarity of bilateral polyorchidism (only 10 cases reported in the literature), our patient's presentation and complications contribute to the body of knowledge on the topic, and this report serves as a valuable reference point for comparing bilateral polyorchidism with other possible presentations and manifestations.

**Acknowledgements:** We would like to express gratitude to MCM Comprehensive Specialized Hospital, Myungung Medical College, and Dr Hilkiyah Suga for their support.

## References

- Cheng L, MacLennan GT, Bostwick DG. *Urologic surgical pathology*. 4th ed. Elsevier; 2020.
- Bayraktar A, Olcucuoglu E, Sahin I, Bayraktar Y, Tastemur S, Sirin E. Management of polyorchidism: surgery or conservative management? *J Hum Reprod Sci*. 2010;3(3):162-163. doi:10.4103/0974-1208.74166
- Lane A. A case of supernumerary testes. *Trans Clin Soc Lond*. 1895;28:59-60.
- Boggon RH. Polyorchidism. *Br J Surg*. 1933;20(80):630-639. doi:10.1002/bjs.1800208010
- Hoare BS, Khan YS. Anatomy, abdomen and pelvis, female internal genitals. In: *StatPearls*. StatPearls Publishing; 2022.
- Titi-Lartey OA, Khan YS. Embryology, testicle. In: *StatPearls*. StatPearls Publishing; 2020.
- Yang Y, Workman S, Wilson M. The molecular pathways underlying early gonadal development. *J Mol Endocrinol*. 2018;JME-17-0314. doi:10.1530/JME-17-0314
- Mathur P, Prabhu K, Khamesra HL. Polyorchidism revisited. *Pediatr Surg Int*. 2002;18(5-6):449-450. doi:10.1007/s00383-002-0765-8
- Yalçinkaya S, Şahin C, Şahin AF. Polyorchidism: sonographic and magnetic resonance imaging findings. *Can Urol Assoc J*. 2011;5(5):E84-E86. doi:10.5489/auaj.10077
- Artul S, Habib G. Polyorchidism: two case reports and a review of the literature. *J Med Case Rep*. 2014;8(1):464. doi:10.1186/1752-1947-8-464

### Peer Reviewed

**Competing Interests:** None declared

**Received:** 8 Apr 2022 • **Revised:** 30 Jan 2023

**Accepted:** 30 Jan 2023 • **Published:** 7 Jul 2023

**Cite this article as:** Getachew A, Suga NK. A 29-year-old man with bilateral polyorchidism and testicular tuberculosis managed at a tertiary hospital in Addis Ababa, Ethiopia. *East Cent Afr J Surg*. Published online July 7, 2023. doi:10.4314/ecajs.v28i2.5

© Akliu G. & N.K. Suga. This is an open-access article distributed under the terms of the Creative Commons Attribution License, which permits unrestricted use, distribution, and reproduction in any medium, provided the original author and source are properly cited. To view a copy of the license, visit <http://creativecommons.org/licenses/by/4.0/>.