

CASE REPORT

Tuberculosis as a cause of nonhealing, complex fistula in ano in a 35-year-old man: A case report from Ethiopia

Anteneh Gadisa¹, Joseph Bedore¹, Sophia Tam², Abier Abdelnaby³

¹Hawassa University College of Medicine and Health Sciences, Hawassa, Ethiopia

²NewYork-Presbyterian/Columbia University Irving Medical Center, New York, NY, USA

³Division of Colorectal Surgery, Montefiore Medical Center, New York, NY, USA

Correspondence: Dr Anteneh Gadisa (antenehgadisa@gmail.com)

© 2022 Anteneh G. et al. This **uncorrected proof** has been published before the article's inclusion in an upcoming issue of the *East and Central African Journal of Surgery* so that it can be accessed and cited as early as possible. This open access article is licensed under a Creative Commons Attribution 4.0 International License (<http://creativecommons.org/licenses/by/4.0/>), which permits unrestricted use, distribution, and reproduction in any medium, provided you give appropriate credit to the original author(s) and the source, provide a link to the Creative Commons license, and indicate if changes were made.



East Cent Afr J Surg
Published 31 August 2022

Abstract

Extrapulmonary tuberculosis (TB) constitutes fewer than 15% of all TB cases. Within this category, perianal TB is particularly rare, accounting for under 1% of gastrointestinal TB cases. This report details the presentation and successful treatment of a 35-year-old man with a chronic perianal fistula yielding persistent purulent discharge, which a biopsy confirmed as secondary to TB. Combined surgical and pharmacological management led to a successful resolution. This case emphasizes the importance of including TB in the differential diagnosis for persistent, complex perianal fistulas, especially in settings where TB prevalence is high.

Keywords: complex fistula in ano, tuberculosis, extrapulmonary tuberculosis, Ethiopia

Introduction

Tuberculosis (TB) remains a significant health issue in Africa.[1] Extrapulmonary presentations are infrequent, with perianal TB constituting less than 1% of gastrointestinal TB cases. Perianal TB may be misidentified as other inflammatory or granulomatous diseases and typically necessitates histological diagnosis and a high index of suspicion. There have been few case reports on the diagnosis and management of perianal TB.

Case presentation

History

A 35-year-old man presented with 2 months of persistent purulent drainage from a perianal wound. He had undergone 2 surgical interventions—seton placement and fistulotomy—within the previous 18 months. The first operation, conducted at a district hospital, did not include a biopsy. The second operation involved the application of a seton to a fistulous tract and curettage of 2 draining sinuses, owing to the challenge of discerning the tracts' internal and external connections. Follow-up at our facility was inconsistent due to the patient missing several appointments. Notably, the discharge continued unabated, with an additional fistulous tract developing, indicative of a lack of healing. The patient reported no alteration in bowel habits or abdominal discomfort and reported no symptoms such as cough, weight loss, fever, night sweats, or loss of appetite. He also had no history of prior TB treatment.

Physical examination

He had a blood pressure of 110/80 mmHg, pulse rate of 78 beats per minute, respiratory rate of 19 breaths per minute, and body temperature of 36.8 °C. Systemic examination did not reveal any other abnormalities. The abdomen appeared flat and soft without organomegaly. Perianal examination revealed 4 pus-draining orifices and 1 healed scar (Figure 1). Digital rectal examination detected no masses; however, the perianal region was indurated, with palpable fibrous tracts forming a horseshoe pattern.

Diagnostic investigations

Abdominal ultrasonography and colonoscopy returned normal results. HIV and diabetes mellitus tests were negative. A full blood count and organ function tests were within normal ranges. The chest x-ray showed no pathological findings.

Differential diagnosis

The complexity and refractory nature of the fistulas prompted us to consider several primary diagnostic possibilities: Crohn's disease, complications from the use of traditional herbal remedies often applied for haemorrhoids or anal fissures in rural Ethiopia, and TB. We promptly ruled out malignancy and other common risk factors, including radiotherapy. We also explored and excluded additional risk factors for chronic, nonhealing wounds, such as undiagnosed collagen vascular disorders and immunosuppression from conditions like HIV or diabetes.

[PAGE NUMBERS NOT FOR CITATION PURPOSES]

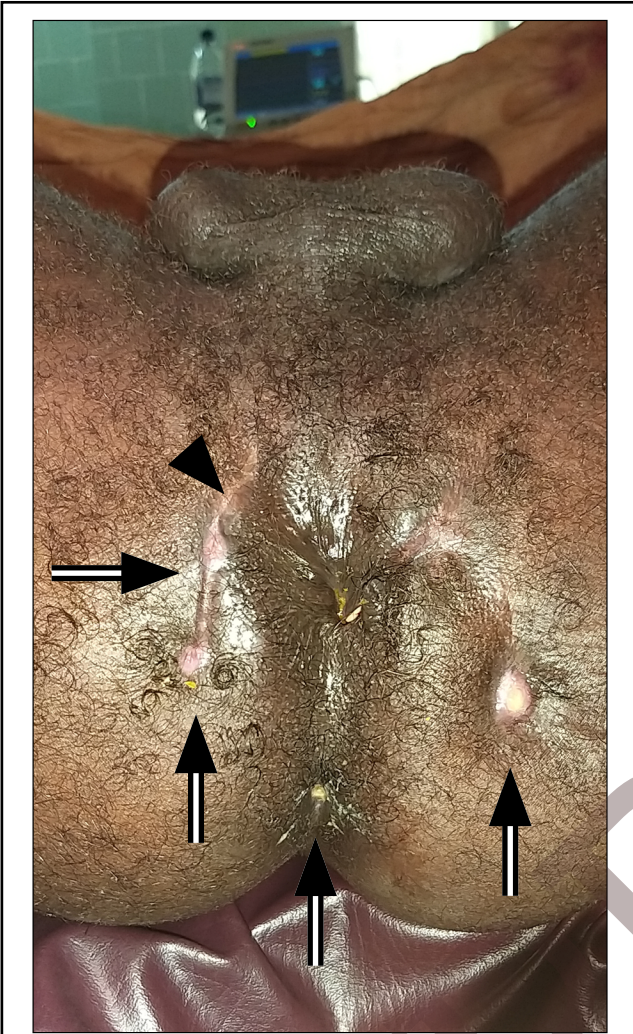


Figure 1. Fistula in ano before the last surgery showing external openings (arrow) and surgical scarring from previous surgical intervention (arrowhead)

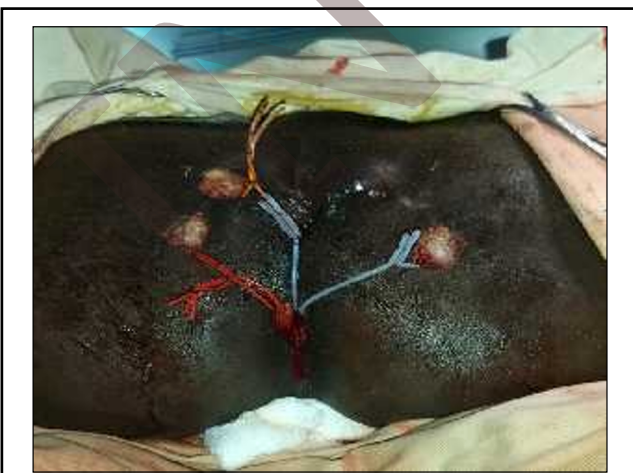

Figure 2. Examination under anaesthesia and draining seton placement

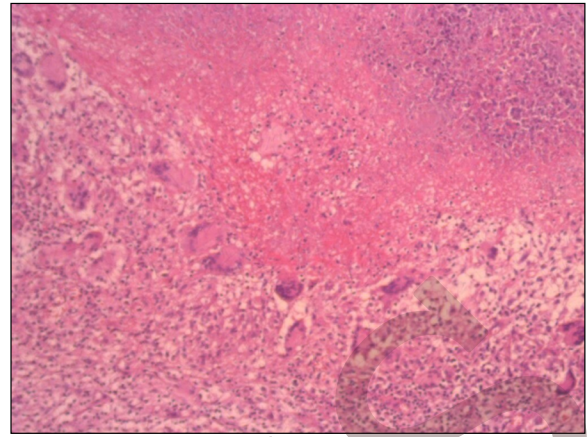


Figure 3. Histopathology photomicrograph showing caseating granuloma

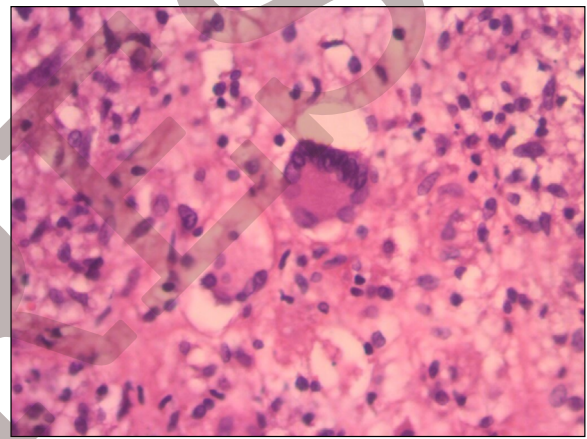


Figure 4. Histopathology photomicrograph showing multinucleated giant cells and epithelioid cell granuloma

Management

Confronted with a complex, nonhealing fistula in ano, we performed an anal examination under anaesthesia. The examination revealed 4 pus-draining external openings situated at the left lateral, posterior midline, right lateral, and right anterior positions, arranged in a horseshoe configuration. Primary openings were identified at the posterior midline and right lateral positions. The fistula tracts, following a transsphincteric route, were curetted, and the tissue obtained was sent for histopathologic examination. A draining seton was placed (Figure 2).

Outcome and follow-up

The patient exhibited a favourable postoperative recovery and was discharged after 2 days. One month later, the histopathology results confirmed TB, characterized by granuloma formation and caseous necrosis (Figure 3, Figure 4). Draining setons were replaced with nylon sutures (Figure 5), and anti-TB drug therapy was initiated. Subsequent follow-up showed significant improvement; within 2 months, the perianal area had healed, allowing for the removal of the nylon seton.

[PAGE NUMBERS NOT FOR CITATION PURPOSES]

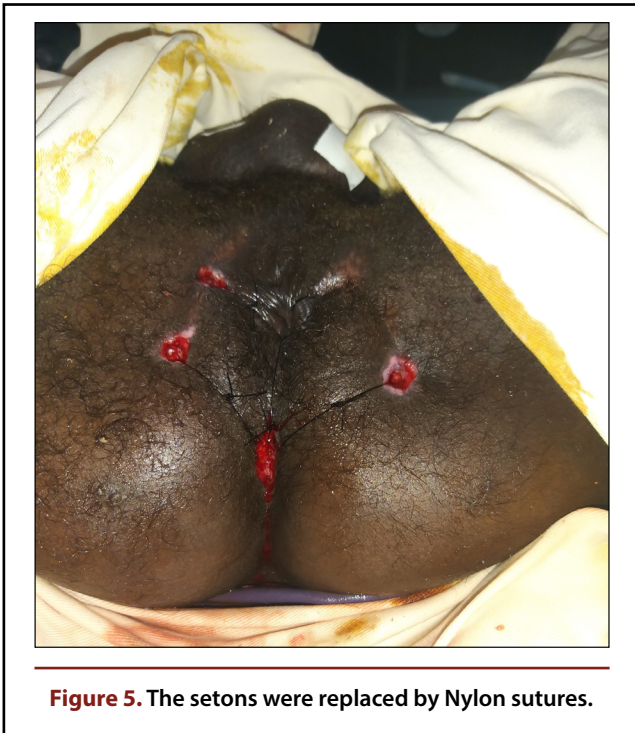


Figure 5. The setons were replaced by Nylon sutures.

Discussion

This report describes a case of a chronic, nonhealing perianal fistula secondary to untreated TB, successfully managed with surgical intervention and appropriate drug therapy.

According to the World Health Organization, TB is the ninth leading cause of death globally, and in 2017, there were an estimated 1.3 million TB-related deaths among HIV-negative individuals and an additional 300 000 deaths among people living with HIV. In Africa, TB continues to be a significant health challenge, with the World Health Organization reporting an estimated incidence of 25 900 cases in a population of 1 020 000 in 2016.[1] Ethiopia remains a high-TB-burden country, with an incidence rate of 164 per 100 000 in 2017.[2]

While the majority of TB cases affect the lungs, extrapulmonary manifestations, including lymphadenitis, pleural, skeletal, meningeal, genitourinary, and gastrointestinal TB, are well recognized.[3] Gastrointestinal TB accounts for 1% of extrapulmonary TB cases[4] and may arise from the ingestion of infected sputum, consumption of contaminated food, haematogenous spread, or direct extension from adjacent organs. The ileocaecal region is the most commonly affected area, presenting as strictures, obstruction, fistulas, or perforation, with lesions being ulcerative, hypertrophic, or a combination of both.[3] Perianal TB, accounting for less than 1% of gastrointestinal TB cases, is particularly rare. It predominantly occurs alongside active pulmonary disease[5] and typically presents as haemorrhoids, perianal abscesses, or fistula in ano.[6] Nepomuceno et al.[7] identified 4 types of perianal TB: ulcerative, verrucous, lupoid, and miliary, with ulcerative being the most common form, often secondary to pulmonary or intestinal lesions—perianal disease is seldom primary.[7],[8] Anal fistula is the most frequent manifestation of perianal TB,[9] and differentiating tuberculous fistulas from those with other causes requires histologic or bacteriologic analysis. Crohn's disease is often considered in differential diagnoses due to symptomatic par-

allels with perianal TB,[10] along with other granulomatous conditions, such as amoebiasis, sarcoidosis, syphilis, and venereal lymphogranuloma secondary to *Chlamydia trachomatis* infection. Instances of perianal TB mimicking cancer are exceedingly rare.[11]

In some instances, perianal TB may resolve with anti-TB treatment alone.[12] However, as previously discussed, a biopsy is generally necessary to confirm the diagnosis, often obtained through surgical intervention.

Conclusions

TB should be considered in the differential diagnosis of non-healing perianal fistulas, particularly in geographical regions with high incidence rates. Combination drug therapy is crucial for effective treatment.

References

1. World Health Organization. *Global Tuberculosis Report 2018*. World Health Organization; 2018. <https://www.who.int/publications/i/item/9789241565646>
2. Tuberculosis country profiles. World Health Organization. 2020. <http://www.who.int/tb/country/data/profiles/en/>
3. Golden MP, Vikram HR. Extrapulmonary tuberculosis: an overview. *Am Fam Physician*. 2005;72(9):1761-1768. [PubMed]
4. Mehta JB, Dutt A, Harvill L, Mathews KM. Epidemiology of extrapulmonary tuberculosis: a comparative analysis with pre-AIDS era. *Chest*. 1991;99(5):1134-1138. doi:10.1378/chest.99.5.1134 [View Article] [PubMed]
5. Logan VS. Anorectal tuberculosis. *Proc R Soc Med*. 1969;62(12):1227-1230. doi:10.1177/003591576906201214 [View Article] [PubMed]
6. Akgun E, Tekin F, Ersin S, Osmanoglu H. Isolated perianal tuberculosis. *Neth J Med*. 2005;63(3):115-117. [PubMed]
7. Nepomuceno OR, O'Grady JF, Eisenberg SW, Bacon HE. Tuberculosis of the anal canal: report of a case. *Dis Colon Rectum*. 1971;14(4):313-316. doi:10.1007/BF02553208 [View Article] [PubMed]
8. Harland RW, Varkey B. Anal tuberculosis: report of two cases and literature review. *Am J Gastroenterol*. 1992;87(10):1488-1491. [PubMed]
9. Sultan S, Azria F, Bauer P, Abdelnour M, Atienza P. Anoperineal tuberculosis: diagnostic and management considerations in seven cases. *Dis Colon Rectum*. 2002;45(3):407-410. doi:10.1007/s10350-004-6191-3 [View Article] [PubMed]
10. Engstrand L. *Mycobacterium paratuberculosis* and Crohn's disease. *Scand J Infect Dis Suppl*. 1995;98:27-29. [PubMed]
11. Walsh TJ, Mulholland JH. Laryngeal and perianal tuberculosis simulating laryngeal and perianal carcinoma. *Johns Hopkins Med J*. 1981;149(4):135-137. [PubMed]
12. Candela F, Serrano P, Arriero JM, Teruel A, Reyes D, Calpena R. Perianal disease of tuberculous origin: report of a case and review of the literature. *Dis Colon Rectum*. 1999;42(1):110-112. doi:10.1007/BF02235192 [View Article] [PubMed]

Peer reviewed

Competing interests: None declared

Received: 21 Aug 2021 • **Revised:** 15 Mar 2022, 18 May 2022

Accepted: 18 May 2022 • **Published:** 31 Aug 2022

Cite this article as: Gadisa A, Bedore J, Tam S, Abdelnaby A. Tuberculosis as a cause of nonhealing, complex fistula in ano in a 35-year-old man: a case report from Ethiopia. *East Cent Afr J Surg*. Published online August 31, 2022. doi:10.4314/ecajs.v27i4.6

© Anteneh G. et al. This is an open-access article distributed under the terms of the Creative Commons Attribution License, which permits unrestricted use, distribution, and reproduction in any medium, provided the original author and source are properly cited. To view a copy of the license, visit <http://creativecommons.org/licenses/by/4.0/>.