



Ileosigmoid knotting in pregnancy: A case report from Zimbabwe

Busisiwe R. Mlambo*, Simbarashe G. Mungazi, Aspect J.V. Maunganidze
University of Zimbabwe, Parirenyatwa Group of Hospitals, Harare, Zimbabwe

*Correspondence: ruva82@yahoo.com

<https://dx.doi.org/10.4314/ecaajs.v22i2.9>

Abstract

Ileosigmoid knotting (ISK), also known as compound volvulus, is a rare cause of intestinal obstruction wherein the ileum wraps around the base of the sigmoid colon and forms a knot with rapid progression to gangrene. The worldwide incidence of ISK ranges from 1 in 1500 to 1 in 66,431. ISK is particularly rare in pregnancy, with the majority of cases occurring in the third trimester. The preoperative diagnosis of ISK in pregnancy is challenging because the condition is often mistaken for other obstructive or nonobstructive emergencies and delayed because of concerns regarding imaging in pregnancy. We report a case of a gravid woman presenting at 13 weeks' gestation with features suggestive of intestinal obstruction and who underwent an emergency laparotomy during which a diagnosis of ISK was made. Her recovery was uneventful, and she was able to carry the pregnancy to term.

Keywords: ileosigmoid knotting, pregnancy, intestinal obstruction

Introduction

Intestinal obstruction in pregnancy is rare in Zimbabwe, with a reported incidence of 1 in 7179.¹ Worldwide the reported incidence is 1 in 1500 to 1 in 66,431.^{2,3} Intestinal obstruction in pregnancy most commonly occurs at 3 separate time frames during gestation: at 4 to 5 months when the uterus becomes intra-abdominal, at 8 to 9 months when the foetal head descends into the pelvis and during the puerperium. Coincident with these intervals is the rearrangement of intra-abdominal organs which in the presence of a pre-existing adhesive band can lead to intestinal obstruction.¹

Adhesions are the most common cause of intestinal obstruction in pregnancy occurring in 58% of cases. 70% of these patients will have a history of previous abdominal or pelvic surgery such as an appendectomy or several episodes of pelvic inflammatory disease. The remaining documented causes of intestinal obstruction in pregnancy listed in descending frequency are volvulus (24%), intussusception (5%) and ileosigmoid knotting (3.2% to 5.9%).^{1,2,4,5}

Ileosigmoid knotting (ISK), also known as compound volvulus is a rare cause of intestinal obstruction where the ileum wraps around the base of the sigmoid colon and forms a knot with rapid progression to gangrene. Ileosigmoid knotting in pregnancy is rare with only 13 cases reported in literature up to 2016. The majority of cases are reported in the third trimester of pregnancy although the condition has been documented as early as 13 weeks. This report describes a case of ileosigmoid knotting presenting at 13 weeks of gestation.^{3,6}

Case presentation

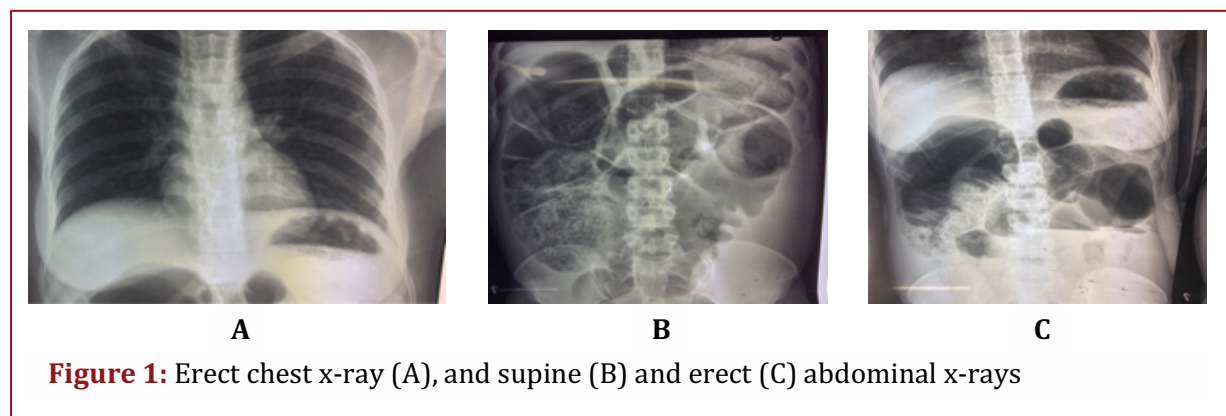
A para-2, gravida-3 32-year-old African female patient, presented to Parirenyatwa Group of Hospitals Casualty Department with a 1-day history of abdominal pain and vomiting at 13 weeks' gestation. The abdominal pain was of sudden onset, colicky nature, peri-umbilical location and progressively worsened in intensity over time. It was non-radiating and no aggravating or

relieving factors were recalled. The pain was associated with gradually progressive abdominal distention and a prominent history of bilious vomiting. Her last bowel motion occurred a day prior to presentation. She had no previous diagnosis of a hernia or pelvic inflammatory disease and no history of a previous laparotomy.

On general examination the patient was dehydrated with pink mucous membranes and no palpable lymphadenopathy. Her blood pressure was 82/59 mmHg, and she had a pulse of 68 beats per minute, a respiratory rate of 16 breaths per minute and a temperature of 37.5°C. On examination of her abdomen she had minimal abdominal movement with respiration and no previous laparotomy scar or masses suggestive of a hernia. Her abdomen was full and tympanic to percussion with no signs of peritonitis. Digital rectal examination revealed normal stool in the rectum and no blood. The rest of the systems examination was normal.

Based on the patient's history abdominal x-rays were done. The images are as shown in Figure 1. Chest and abdominal x-rays showed no evidence of free air under the diaphragm. There were distended loops of large bowel and stool in the ascending and transverse colon and some air fluid levels were seen on the straight and erect abdominal films, respectively.

Full blood count showed a leucocytosis of 16.59×10^9 cells/L. Urea and electrolytes showed an elevated urea of 9.2 mmol/L. All other parameters were normal. The patient was admitted with a provisional diagnosis of intestinal obstruction secondary to sigmoid volvulus. Aggressive intravenous fluid resuscitation was commenced, and a transurethral catheter was inserted for the monitoring of fluid output. Additional supportive treatment instituted included oxygen per face mask, a nasogastric tube for decompression, and intravenous antibiotics.



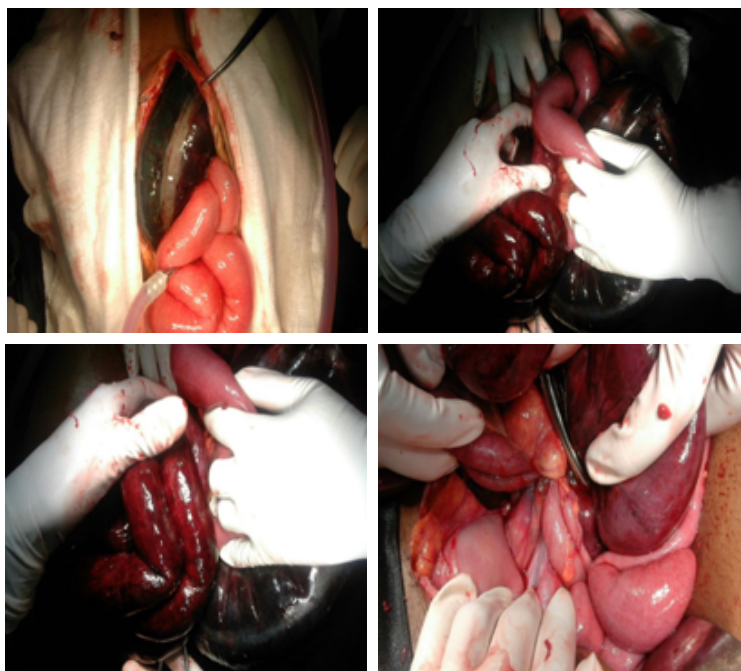


Figure 2: Intraoperative images showing gangrenous loops of ileum and sigmoid colon in a patient with an ileosigmoid knot

The patient was counselled about the diagnosis and informed consent was obtained for a laparotomy. Reassessment of the patient after a few hours revealed a marked clinical deterioration. She had a respiratory rate of 22 breaths per minute, a pulse of 106 beats per minute, a temperature of 37.8°C, and a blood pressure of 108/72 mmHg. Her abdomen was grossly distended and tympanic, with overt signs of peritonitis.

At laparotomy, 1 L of haemorrhagic fluid was suctioned from the abdomen and an ileosigmoid knot was noted, with gangrenous ileum and sigmoid colon as shown in Figure 2. One-and-a-half metres of distal ileum and the sigmoid colon were resected. A limited right hemi-colectomy was done, followed by a Hartmann's procedure for the gangrenous sigmoid colon.

Postoperatively, the patient was admitted into the intensive care unit (ICU) and extubated after 2 days. She was discharged from ICU 2 days later and started on oral feeds on day 5 postoperation. An obstetric ultrasound scan done on the seventh postoperative day showed a viable intra-uterine pregnancy. She was eventually discharged from the hospital on day 8 with a pink colostomy and a plan for review in the surgical outpatients after 2 weeks. Closure of colostomy was scheduled after delivery.

Discussion

Ileosigmoid knotting in pregnancy is rare with only 13 cases reported in the literature.⁵ The majority of these were reported in multiparous women in their third trimester of pregnancy. As reported by Maunganidze et al., ileosigmoid knotting can occur as early as 13 weeks.³ Multiparity in this patient could have been a risk factor for the development of ISK. Multiparity is associated



with laxity of the anterior abdominal wall, a risk factor for ISK.⁷ No other risk factors for ISK were identifiable in this patient.

The preoperative diagnosis of ileosigmoid knotting is difficult, occurring in less than 28% of cases. In most cases, ours included, it is mistaken for an obstructive or nonobstructive emergency with the diagnosis only being clinched intraoperatively.⁸ In this case the working diagnosis was that of sigmoid volvulus. It was interesting to note that the patient's history of prominent bilious vomiting was more suggestive of small bowel obstruction, yet the radiological investigations showed more of a large bowel obstruction picture. It has been shown by Raveethiran that this apparent conflict between clinical presentation and radiological appearance should raise the index of suspicion for a diagnosis of ileosigmoid knotting.⁹

This patient had a provisional diagnosis of sigmoid volvulus without peritonitis. No attempt was made to decompress the volvulus using a flatus tube. This decision was largely based on the presence of a neutrophil leucocytosis. Although in pregnancy, such an elevated white cell count should be interpreted with caution considering the occurrence of a physiologic leucocytosis in pregnancy.² The patient's raised urea of 9.2 mmol/L was not to be undermined because the reference range for urea in a pregnant woman in her second trimester is 1.1 to 4.6 mmol/L, which is notably lower than the range of 2.5 to 7.1 mmol/L in a nonpregnant adult. This patient would have fulfilled the criteria of a classical diagnostic triad for ISK described by Raveethiran which includes a clinical picture of sudden onset small bowel obstruction, radiological features of large bowel obstruction and inability to pass a sigmoidoscope or flatus tube.⁹

A striking feature of this case was the rapid deterioration with development of sepsis and peritonitis. This has been shown to be a characteristic feature of ileosigmoid knotting which should raise the index of suspicion for a preoperative diagnosis of ileosigmoid knotting.⁸

One of the reasons for a delayed diagnosis of ISK in pregnancy is reluctance to perform radiological investigations. In our case we concluded that the benefits of radiological investigation out-weighed the risk of fetal exposure to harmful levels of radiation. This line of thought is in accordance with the International Commission on Radiological Protection, which clearly reports that an abdominal series in pregnancy is unlikely to result in any adverse outcome.¹⁰

The intraoperative findings in this patient were in keeping with most cases of ISK in that both small bowel and sigmoid colon were gangrenous. The knot was so tightly and repetitively twisted that although desirable, it was not possible to determine the active from the passive segment. Considering this patient was now septic with features of peritonitis and gangrenous small and large bowel the definitive surgical intervention was deemed appropriate.

Management of ISK in pregnancy requires a multi-disciplinary approach involving the general surgeons, radiologists, obstetricians and neonatologists. Preoperative aggressive resuscitation followed by emergency surgery is essential.

Conclusions

Ileosigmoid knotting in pregnancy is rare. Its preoperative diagnosis requires a high index of suspicion. Its management should involve appropriate radiological investigations, aggressive resuscitation and an expeditious operative management.



Acknowledgements

Thanks to Mr Mashayamombe and Mr Ngulube for their guidance in the management of the case.

References

1. Muguti GI. Intestinal obstruction during pregnancy and the puerperium at Mpilo Central Hospital. *J R Coll Surg Edinb.* 1988;33(3):156-158.
2. Chihaka OB. Cecal Volvulus in Pregnancy: a Case Report. *Centr Afr J Med.* 2011;57:32-35.
3. Maunganidze AJV, Mungazi SG, Siamuchembu M, Mlotshwa M. Ileosigmoid knotting in early pregnancy: A case report. *International Journal of Surgery Case Reports.* 2016;23:20-22.
4. Connolly MM, Unti JA, Nora PF. Bowel obstruction in pregnancy. *Surg Clin North Am.* 1995;75(1):101-113.
5. Perdue PW, Johnson Jr. HW, Stafford PW. Intestinal obstruction complicating pregnancy. *Am J Surg.* 1992;164(4):384-388.
6. Shimizu R, Hoshino Y, Irie H, et al. Ileosigmoid knot at week 13 of pregnancy: Report of a case. *Int Surg.* 2014;99(3):230-234.
7. Koshariya M, Choudhary A, Gome N, Rai A, Songra MC. Ileosigmoid knotting: An unusual cause of intestinal obstruction. *Int Arch Integr Med.* 2015;2(4):179-181.
8. Atamanalp SS, Ören D, Başoğlu M, et al. Ileosigmoidal knotting: Outcome in 63 patients. *Dis Colon Rectum.* 2004;47(6):906-910.
9. Raveenthiran V. The ileosigmoid knot: new observations and changing trends. *Dis Colon Rectum.* 2001;44(8):1196-1200.
10. Tamura M, Shinagawa M, Funaki Y. Ileosigmoid knot: computed tomography findings and the mechanism of its formation. *ANZ J Surg.* 2004;74(3):184-186.