



Iatrogenic tube jejunostomy complicating suprapubic cystostomy: A case report

A. Sadiq Muhammad*¹, Ahmed Bello², Muhammed Ahmed², Maitama H. Yusuf²

¹Urology Unit, Department of Surgery, Usmanu Danfodiyo University Teaching Hospital and Usmanu Danfodiyo University, Sokoto, Nigeria

²Urology Division, Department of Surgery, Ahmadu Bello University Teaching Hospital and Ahmadu Bello University, Zaria, Nigeria

*Correspondence: asmgusau@gmail.com

<https://dx.doi.org/10.4314/ecajs.v22i2.8>

Abstract

Suprapubic cystostomy (SPC) can be done by open or percutaneous technique. The procedure is considered simple and generally safe even in less experienced hands. However, some complications may arise occasionally, including bowel injury. We report a 60-year-old man who presented with acute-on-chronic urinary retention 6 months after a SPC in a peripheral hospital for chronic urinary retention. The catheter was draining scanty turbid fluid and was changed regularly. Abdominal exploration revealed an intact full bladder with the supposed suprapubic catheter passing through a small perforation into the jejunum. He had repair of the perforation and proper SPC was inserted. The recovery was uneventful, and he was discharged home after a week.

Keywords: suprapubic cystostomy, complications, bowel injury, tube jejunostomy

Introduction

Suprapubic cystostomy (SPC) is a procedure of diversion of urine at the level of bladder when there is infra vesical obstruction. It is done commonly to relieve urinary retention, either when there is failure of urethral catheterisation or when catheterisation is contraindicated. It can be done by open or percutaneous techniques and either blind or with image guidance such as ultrasound. Blind punctures and sometimes open procedures may be associated with bowel injury. Bowel injury occurs in 2.2% to 2.7% of cases following percutaneous trocar punch procedures.¹ There have been several reports of injuries to the ileum and sigmoid colon and a few reports of injuries to the stomach and rectum.²⁻⁴ Stomach injury can occur in the form of iatrogenic suprapubic gastrostomy.⁴ We did not find report of jejunal injury in the literature.

We report a case of iatrogenic tube jejunostomy complicating SPC from a peripheral hospital. This is a very rare complication of this procedure and to our knowledge; it is the first reported case. It is hoped that this will educate us on the rare possibility of this type of occurrence.

Case presentation

A 60-year-old man presented with a 6-month history of persistent difficulty in urination despite the placement of a suprapubic cystostomy (SPC) at a peripheral hospital to relieve urinary retention secondary to urethral stricture. The suprapubic catheter was draining scanty turbid fluid and was changed monthly. Examination revealed well preserved patient with an indwelling suprapubic catheter draining turbid fluid. A diagnosis of urethral stricture was confirmed by retrograde urethrogram (RUG). Ultrasound showed a markedly distended urinary bladder with normal upper tract. He had pelvic exploration which revealed a distended intact urinary bladder (Figure 1). The suprapubic catheter was seen passing through the jejunum (Figure 2 and Figure

3) 100 cm from the ligament of Treitz, with its balloon inflated in the lumen of the bowel segment. The catheter balloon was deflated and removed, while the jejunal stoma was repaired. A proper SPC was done with uneventful recovery.

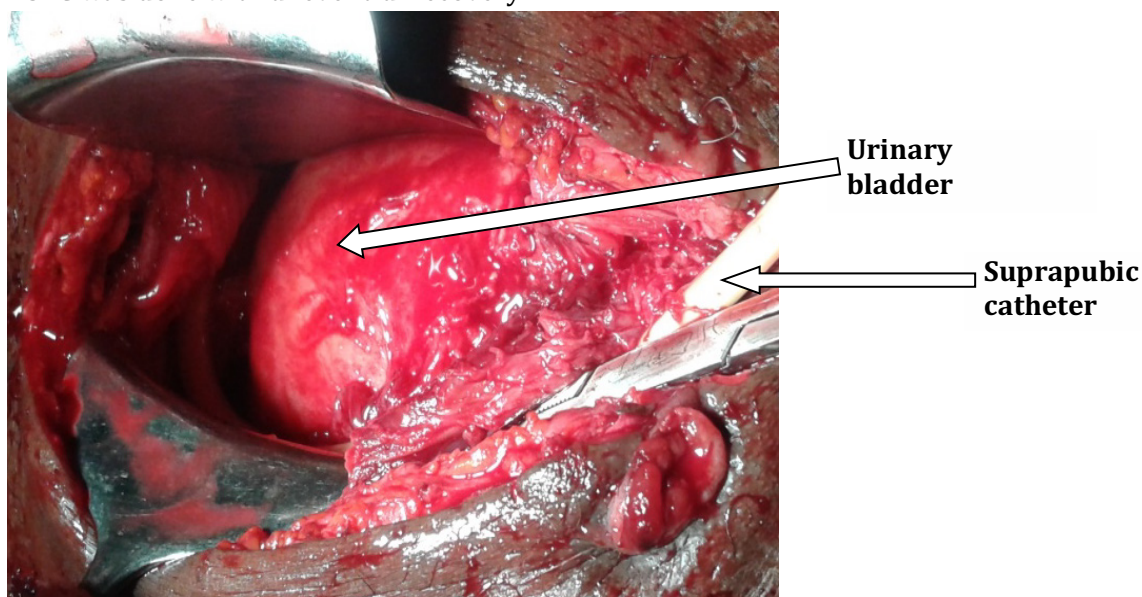


Figure 1: Suprapubic catheter bypassing intact full bladder

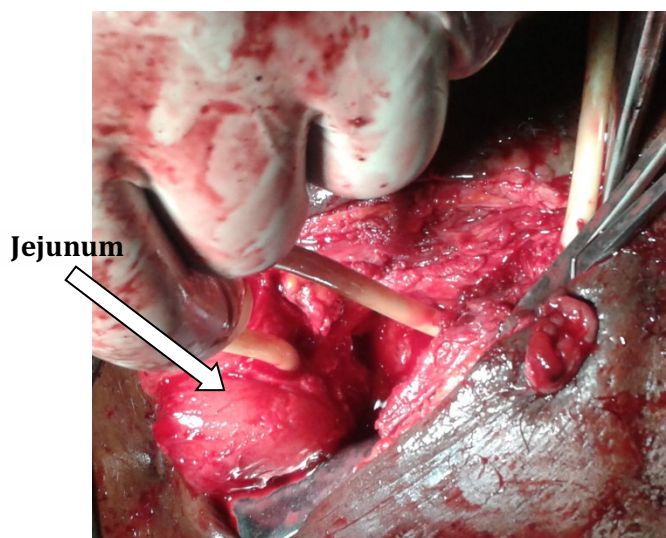


Figure 2: Suprapubic catheter passing into a segment of jejunum (tube jejunostomy before bowel mobilisation)

Discussion

Suprapubic cystostomy is a simple and safe procedure even in less experienced hands.¹ It is often done on an outpatient basis as a day case.⁵ However, some complications are occasionally encountered, even in experienced hands. The common early complications include bleeding, catheter blockage, and catheter-associated infections.⁵⁻⁷ Bowel injury is a rare early and dreaded complication that occurs in 2.2% to 2.7% of SPC procedures.^{1,4} Bowel injuries usually occur during the initial procedure, the commonest part of bowel involved is the small intestine.⁴ Bowel injuries were reported to involve terminal ileum, caecum, rectum and colon.^{1,2,4,5,7} These can be

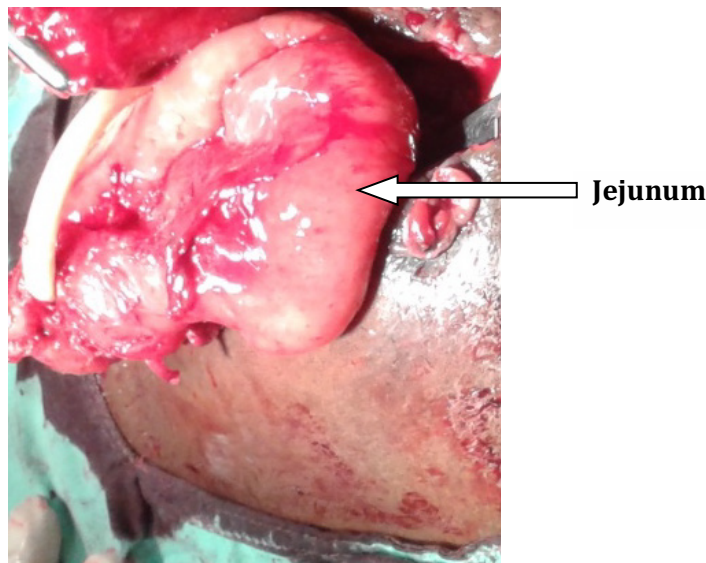


Figure 3: Tube jejunostomy after bowel mobilisation

complicated by enterocutaneous fistula with early presentation.^{8,9} In our index patient despite persistent lower urinary tract symptoms (LUTS) and regular catheter change over a period of 6 months, the bowel injury was not discovered at the referring hospital suggesting a poor clinical judgment and inadequate patient evaluation. The occurrence of this rare complication may in part be attributable to limited experience of the physician. Though, even experienced surgeons may injure bowel during similar procedures, the diagnosis would have been made much earlier and necessary action taken.⁴ Involvement of jejunum, as in our index patient (Figure 2 and Figure 3), is quite uncommon; we could not find a reported case in literature.

The rarity of jejunal injury is due to the fact that jejunum is located relatively far away from the region of bladder compared to the ileum. Pain and discomfort from inadequate anaesthesia for open suprapubic cystostomy, poor lighting, and inadequate exposure (especially in inexperienced hands) increase the risk of inadvertent bowel injury. Other risk factors for bowel injury include cystostomy on an empty bladder, blind techniques, previous abdominal surgery, and when the distance between the upper border and pubis is less than 18 cm due to bowel interposition.¹⁰ Adhesions were reported in 59% of cases following midline scars.^{10,11}

Safety measures during the procedure include ensuring a full bladder, ultrasound guidance, use of Seldinger technique in those without a full bladder and open procedures in those with previous abdominal procedure.⁴ In open suprapubic cystostomy, the urinary bladder is recognised by its glistening appearance, presence of perivesical fat and veins, location behind the symphysis pubis and occasionally the appearance of the crisscrossing fibers of the detrusor muscle.

Conclusions

Bowel injury is an uncommon complication of suprapubic cystostomy and jejunum may be affected. Safety measures and high index of suspicion may prevent or lead to early recognition of this complication.



Acknowledgements

Thanks to Prof. Aminu Mode, Department of Modern European Languages and Linguistics, Usmanu Dan Fodiyo University, Sokoto, Nigeria, for grammatical corrections.

References

1. Ahluwalia RS, Johal N, kouriefs C, Kooiman G, Montgomery BS, Plail RO. The Surgical risk of suprapubic catheter insertion and long-term sequelae. *Urology*. 2006;88:210–213.
2. Wu CC, Su CT, Lin ACM. Terminal ileum perforation from a misplaced percutaneous suprapubic cystostomy. *Eur J Emerg Med*. 2007;14:92–93.
3. Rajmohan R, Aguilar-Davidov B, Tokas T, Rassweiler J, Gözen AS. Iatrogenic direct rectal injury: An unusual complication during suprapubic cystostomy (SPC) insertion and its laparoscopic management. *Arch Ital di Urol e Androl*. 2013;85:101–103.
4. Halder SK, Khan I, Mukhopadhyay P, Paira SK. Inadvertent suprapubic gastrostomy: Report of a unique complication of blind percutaneous suprapubic trocar cystostomy. *Indian J Urol*. 2012;28:445–449.
5. Khan A, Abrams P. Suprapubic catheter insertion is an outpatient procedure: cost savings resultant on closing an audit loop. *BJU Int*. 2008;103:640–644.
6. Vaidyanathan S, Hughes PL, Soni BM, Oo T, Singh G. Inadvertent positioning of suprapubic catheter in urethra: a serious complication during change of suprapubic cystostomy in a spina bifida patient - a case report. *Cases J*. 2009;2:9372-9376.
7. Vaidyanathan S, Soni B, Hughes P, Singh G, Oo T. Preventable long-term complications of suprapubic cystostomy after spinal cord injury: Root cause analysis in a representative case report. *Patient Saf Surg*. 2011;5:27-30.
8. Ajape AA, Obiano SK, Ibrahim A. Enterocutaneous fistula: An usual complication of suprapubic cystostomy. *Niger J Surg Res*. 2005;7:199–203.
9. Islam S, Barai KP. Suprapubic catheterisation complicated by iatrogenic enterocutaneous fistula. *Cases J*. 2009;2:9311-9315.
10. Levrant SG, Bieber EJ, Barnes RB. Anterior abdominal wall adhesions after laparotomy or laparoroscopy. *J Am Assoc Gynecol Laparos*. 1997;4:353–356.
11. Cho KH, Doo SW, Yang WJ, Song YS, Lee KH. Suprapubic cystostomy: risk analysis of possible bowel interposition through the percutaneous tract by computed tomography. *Korean J Urol*. 2010;51:709–712.