

**Acalculous cholecystitis: Three Case Reports**S G Mungazi<sup>1</sup>, H Mungani<sup>2</sup><sup>1</sup>General Surgery Registrar, University of Zimbabwe, Parirenyatwa Hospital, Harare<sup>2</sup>Consultant General Surgeon, Harare Central Hospital, Harare**Correspondence to:** Simbarashe Gift Mungazi, Email:[sgmungazi@gmail.com](mailto:sgmungazi@gmail.com)

*Acute acalculous cholecystitis is an acute necroinflammatory disease of the gallbladder. Whilst acalculous cholecystitis accounts for approximately 10 percent of acute cholecystitis cases it is associated with a high morbidity and mortality. The condition rapidly progresses to complications such as gangrene, perforation and empyema of the gallbladder. Gangrenous cholecystitis is the most severe form and complication of acute cholecystitis. Acute acalculous cholecystitis warrants urgent surgical intervention to prevent catastrophic outcomes. We report a series of three patients that we managed for acute acalculous cholecystitis. The first patient was a 65-year-old, male who was positive of Human Immunodeficiency Virus (HIV) with a CD4 count of 165 cells/mm<sup>3</sup> and was on antiretroviral treatment. The second patient was a 73-year-old male with no comorbidities. The last patient was a 72-year-old female with congestive cardiac failure due to hypertension. One patient had a successful laparoscopic cholecystectomy and the other two had open cholecystectomies. Two of the patients did well and were discharged whilst the third patient died in intensive care unit day 2 postoperatively. All the three patients had no evidence of gallbladder stones. Two of the histology reports confirmed acalculous gangrenous cholecystitis and the third histology showed acalculous haemorrhagic cholecystitis. Acalculous cholecystitis is a surgical emergency. Once suspected, principles of management include resuscitation, hospital admission, broad spectrum antibiotics, adequate analgesia and emergency surgery.*

**Key words:** Acalculous cholecystitis, Gangrenous cholecystitis, Cholecystectomy**DOI:** <http://dx.doi.org/10.4314/ecajs.v21i3.17>**Introduction**

Acute acalculous cholecystitis (AAC) is an acute necroinflammatory disease of the gallbladder in the absence of cholelithiasis and has a multifactorial pathogenesis<sup>1</sup>. It accounts for approximately 10% of all cases of acute cholecystitis<sup>2</sup>. AAC can progress to gangrene, perforation, and empyema of the gallbladder in 6% to 82% of cases<sup>3</sup>. The incidence of gangrenous cholecystitis ranges from 2–38% of all patients with acute cholecystitis<sup>4</sup>. Gangrenous cholecystitis has a mortality rate of up to 22% and a complication rate of 16–25%<sup>4</sup>. The preoperative diagnosis of gangrenous cholecystitis is difficult and may often only be entertained after deterioration of a patient suspected of having simple or uncomplicated acute cholecystitis.

We report a series of three patients whom we managed for acute acalculous cholecystitis. Two of these patients had confirmed gangrenous cholecystitis at histology.

**Case Reports****Case 1**

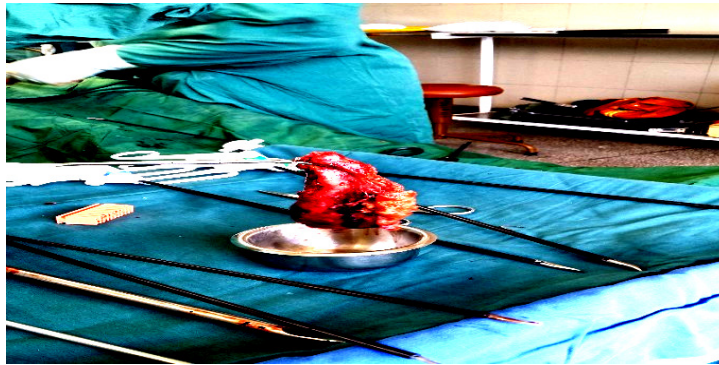The first case was of a Human Immunodeficiency Virus (HIV) positive 65-year-old male patient, who was on antiretroviral treatment for seven years. He presented at Harare Hospital surgical unit with one-week history of right upper quadrant pain that worsened two days prior to presentation. There was no history of jaundice. He did not have a history of diabetes mellitus or other chronic illnesses. Current CD4 count was 165 cells/mm<sup>3</sup>. He was of sober habits. On examination the patient was ill, normotensive, afebrile and not jaundiced. The gallbladder was palpable and tender with the rest of the abdomen being soft and non-tender. The rest of the physical examination was unremarkable.

Full blood count showed a white cell count (WCC) 12.4/mm<sup>3</sup> (4-11), hemoglobin (Hb) of 14 g/dl (15+/-1.7), platelets (PLT) 185 x 10<sup>3</sup> (150-400). Liver function tests (LFTS) and urea and electrolytes (U &Es) were normal. The abdominal ultrasound showed a distended gallbladder with thickened mucosa, absence of stones or sludge and normal intra and extrahepatic ducts. After fluid resuscitation, antibiotics and analgesia commencement he underwent a laparoscopic cholecystectomy. During the surgery there were extensive adhesions on and around the gallbladder that was grossly dilated and friable. Laparoscopic cholecystectomy was successfully done (see picture below) with an operative time of 2 hours.

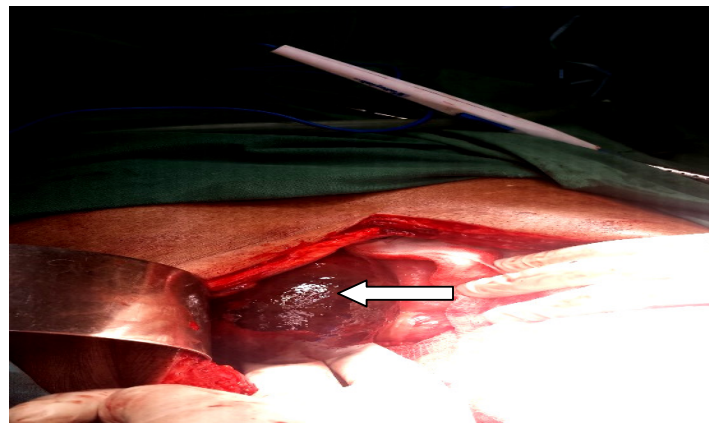
### Case 2.

He was a 73-year-old male, previously healthy, with no comorbidities who presented with a 3-day history of an acute abdomen and no history of prior intermittent jaundice. On examination he was ill looking, with a temperature 37.8 degrees Celsius but was not jaundiced. He had marked generalized abdominal tenderness with associated rebound tenderness that signified peritonitis. Full blood count results showed a WCC  $11.5/\text{mm}^3$ , Hb 13.0g/dl, MCV 80.0 fem to litres (80-96) and PLT  $200 \times 10^3$ . The other investigations were normal. The patient was resuscitated with intravenous fluids and broad spectrum antibiotics as well as analgesia instituted. The patient underwent an emergency laparotomy. A gangrenous gallbladder with no stones was found as shown in Figure 2. The common bile duct was of a normal caliber. A cholecystectomy was done.

Both patients had an uneventful postoperative recovery period and were subsequently discharged. The histology of the first patient reported "sections from the gallbladder show suppurative inflammation with necrosis consistent with a gangrenous cholecystitis". The histology of the second patient reported "the gallbladder wall shows complete hemorrhagic necrosis consistent with torsion. Conclusion is gallbladder gangrene". Repeat LFTs of both patients after 2weeks were normal.



**Figure 1:** Gallbladder Specimen from Case 1.



**Figure 2.** Gangrenous Gallbladder of Case 2.

### Case 3.

The third patient was a 72year old female with congestive cardiac failure due to hypertension who presented with a 3-day history of generalized abdominal pain associated with vomiting. On examination she was ill looking, dehydrated and not jaundiced. She had a temperature of 36.1 degrees Celsius, BP 166/72 mmHg, Pulse of 120 bpm and a respiratory rate of 16bpm. She had a positive Murphy's sign. Blood results showed WCC  $12.31/\text{mm}^3$ , Hb 13.4 g/dl, PLT  $233 \times 10^3$ , urea 34.7mmol/l (2-6.7), creatinine 127umol/l (98-131), sodium 133mmol/l (133-146), and potassium 3.7mmol/l (3.5-5.2). LFTs: Total Bilirubin 12umol/L (3-29) ALP 176 U/L (34-140) GGT 153U/L (13-63) AST 65U/L (10-30) ALT 70 U/L (5-44). Transabdominal ultrasound showed a distended gallbladder with thickened mucosa, absence of stones or sludge and normal intra and extrahepatic ducts. An electrocardiogram was normal. After resuscitation the patient underwent an emergency open cholecystectomy. Unfortunately, the patient died

in the intensive care unit on day 2 post operation. The histology showed acalculous hemorrhagic cholecystitis.

## Discussion

AAC most often occurs in old age, is associated with conditions such as immunosuppression, critically ill patients in the intensive care unit, major surgery, severe trauma, sepsis and patients on long term total parenteral nutrition<sup>2</sup>. Risk factors for AAC in our patients were notably of: age in all the patients, immunosuppression in one patient and congestive cardiac failure on the third patient. The age of onset of patients with AAC is known to be older than those patients with calculous cholecystitis<sup>5</sup>. Furthermore, although calculous cholecystitis is much more common in women than in men, many studies on AAC have revealed a male predominance<sup>5</sup>. The youngest of our patients was 65 years of age and the oldest being 73 years, 2 were males and one was female. However, no conclusion can be drawn from this case series as our sample size is too small. AAC occurring in patients with acquired immunodeficiency syndrome (AIDS) and other immunosuppressed patients maybe due to opportunistic infections such as microsporidia, *Cryptosporidium* or cytomegalovirus<sup>6</sup>. The low CD4 count on our patient who had been on antiretroviral treatment for seven years could indicate treatment failure. Unfortunately, a viral load was not done to confirm treatment failure. However, the patient was referred to the physicians for consideration of second line treatment.

The pathogenesis of AAC is ill defined and appears to be multifactorial<sup>2,5</sup>. The commonly postulated theories regarding the pathogenesis of AAC are bile stasis, sepsis and ischemia<sup>5</sup>. There is histologic data that explain some of the pathology of AAC as a response to systemic inflammation<sup>2</sup>. AAC showed the following:

1. increased leukocyte margination (consistent with ischemia and reperfusion injury);
2. increased focal lymphatic dilation with interstitial edema associated with local microvascular occlusion (ischemia related); and
3. increased and deeper bile infiltration in the GB wall suggesting that bile stasis and increased epithelial permeability exist, leading to epithelial damage<sup>2</sup>.

These findings substantiate the hypotheses that bile stasis and ischemia are likely involved in the pathogenesis of AAC<sup>2</sup>. Typhoid fever is a known cause of spontaneous gallbladder perforation in the absence of stone disease in the young<sup>2</sup>. AAC may also occur in patients with disseminated fungal infection (*Candida* species), systemic leptospirosis, *Vibrio cholera* and *clonorchis sinensis*<sup>5</sup>. AAC has also been reported in patients with connective tissue disease<sup>5</sup>.

The clinical presentation of AAC is variable and more so when it complicates. In one large single center report, 36 of 47 patients (77%) identified over a seven-year period developed symptoms at home without evidence of acute illness or trauma<sup>7</sup>. This is in keeping with our patients' presentations. They came from home as opposed to critically ill patients in intensive care. Our patients presented with a 3 to 7 days' history which suggests that our patients seem different by presenting late. There are studies that have attempted to predict the risk factors for gangrenous cholecystitis. Based on the univariate analysis from one study, nine variables were found to be associated with gangrenous cholecystitis: age 51 years or older, African-American race, history of diabetes mellitus, WBC<sub>15,000</sub>, AST<sub>43 U/L</sub>, ALT<sub>50 U/L</sub>, ALP<sub>200 U/L</sub>, lipase<sub>200 U/L</sub>, and pericholecystic fluid on ultrasonography<sup>8</sup>. Based on multivariate analysis variables associated with a gangrenous gallbladder were: male sex, diabetes mellitus and a raised white cell count<sup>8</sup>. However, Contini *et al*<sup>9</sup> showed that there is no single clinical or laboratory finding, apart from a high WBC, predictive of severe inflammation of the gallbladder. Interestingly all three patients presented with not much elevated fever. Possible explanations are could it be due to an insidious course or that the immune response is poor. This is even shown on the marginal elevation of the white cell count compared with other authors.

The preoperative diagnosis of gangrenous cholecystitis is difficult and often only be entertained after deterioration of a patient suspected of having simple or uncomplicated acute cholecystitis. Two of our patients had a histological diagnosis of gangrenous cholecystitis, signifying the much feared sequela to the most severe form of cholecystitis. Clinical evaluation, laboratory and imaging investigations as well as a high index of suspicion are all in the armamentarium of the clinician to suspect acalculous gangrenous cholecystitis. Once suspected, acalculous gangrenous cholecystitis is a surgical emergency. Principles of management include resuscitation, hospital admission, broad spectrum antibiotics, adequate analgesia as

well as surgery. Laparoscopic cholecystectomy can be performed for AAC<sup>2</sup>; however, there is some controversy regarding the best surgical approach to gangrenous cholecystitis<sup>10</sup>.

### Conclusion

Acute acalculous cholecystitis (AAC) is a surgical emergency. It is associated with a high morbidity and mortality. The pathogenesis is multifactorial. AAC rapidly progresses to complications such as gangrene, perforation and empyema of the gallbladder. The preoperative diagnosis of gangrenous cholecystitis is difficult and often only be entertained after deterioration of a patient suspected of having simple or uncomplicated acute cholecystitis. Once suspected, acute acalculous cholecystitis, principles of management include resuscitation, hospital admission, broad spectrum antibiotics, adequate analgesia as well as surgery.

### Acknowledgement

To Professor G I Muguti for his guidance, wisdom and mentorship and also to Lancet laboratories for the pathological reports.

### References

1. Barie PS, Eachempati SR. Acute Acalculous Cholecystitis. Vol. 39, Gastroenterology Clinics of North America. 2010. p. 343–57.
2. Dr Hemendra Kumar DAJDDSDMJA. Acute Gangrenous Acalculous Cholecystitis In An Adolescent: \nA Case Report\n. IOSR J Dent Med Sci [Internet]. 2014;13(11):56–9. Available from: <http://www.iosrjournals.org/iosr-jdms/papers/Vol13-issue11/Version-3/N0131135659.pdf>
3. Wang AJ, Wang TE, Lin CC, Lin SC, Shih SC. Clinical predictors of severe gallbladder complications in acute acalculous cholecystitis. World J Gastroenterol. 2003;9(12):2821–3.
4. Grant RL, Tie MLH. False negative biliary scintigraphy in gangrenous cholecystitis. Australas Radiol. 2002;46(1):73–5.
5. Ryu JK, Ryu KH, Kim KH. Clinical features of acute acalculous cholecystitis. J Clin Gastroenterol. 2003;36(2):166–9.
6. Wind P, Chevallier JM, Jones D, Frileux P, Cugnenc PH. Cholecystectomy for cholecystitis in patients with acquired immune deficiency syndrome [Internet]. Vol. 168, American Journal of Surgery. 1994. p. 244–6. Available from: <http://www.ncbi.nlm.nih.gov/pubmed/8080061>
7. Savoca PE, Longo WE, Zucker K a, McMillen MM, Modlin IM. The increasing prevalence of acalculous cholecystitis in outpatients. Results of a 7-year study. Ann Surg [Internet]. 1990;211(4):433–7. Available from: <http://www.pubmedcentral.nih.gov/articlerender.fcgi?artid=1358029&tool=pmcentrez&rendertype=abstract>
8. Fagan SP, Awad SS, Rahwan K, Hira K, Aoki N, Itani KMF, et al. Prognostic factors for the development of gangrenous cholecystitis. Vol. 186, American Journal of Surgery. 2003. p. 481–5.
9. Contini S, Corradi D, Alessandri L, Pezzarossa A, Scarpignato C. Can Gangrenous Cholecystitis be Prevented? Vol. 38. 2004. p. 710–6.
10. Chaudhry S, Hussain R, Rajasundaram R, Corless D. Gangrenous cholecystitis in an asymptomatic patient found during an elective laparoscopic cholecystectomy: a case report. J Med Case Rep [Internet]. 2011;5(1):199. Available from: <http://www.jmedicalcasereports.com/content/5/1/199>