

## Colostomy for Anorectal Malformation in a Tertiary Center in Nigeria

E Aiwanlehi<sup>1</sup>, O Murphy<sup>2</sup>, A Abraham<sup>2</sup>

<sup>1</sup>Paediatric Surgery Unit, Department of Surgery, Irrua Specialist Teaching Hospital, Irrua Edo State

<sup>2</sup>Department of Surgery, Federal Medical Centre, Yenogoa, Bayelsa State, Nigeria

**Correspondence to:** Dr. E. Aiwanlehi, Email Address: [eighemhenrioehi@yahoo.com](mailto:eighemhenrioehi@yahoo.com)

**Background:** Anorectal malformations constitute a wide spectrum of congenital anorectal abnormalities ranging from absent anus to anal membranes and fistulae. It is one major indication for the creation of colostomy in early neonatal life. This study was aimed at to describe and highlight the place of colostomy in the management of anorectal malformations. This article also reviews the issues relating to the choice of colostomy in anorectal malformation and common complications.

**Methods.** The study was a prospective study carried out at a tertiary medical centre in Nigeria. It involved patients with an anorectal malformation requiring the creation of colostomy.

**Results:** A total of 19 neonates with anorectal malformation was seen over the period. The male to female ratio was approximately 1:2 with a female preponderance. Rectovestibular fistula was the commonest indication in females while recto-urethral fistula was commonest indication in males. Elective colostomy accounted for 78.9%.

**Conclusion:** Anorectal malformation is the commonest indication for the creation of colostomy; this is closely followed by hirschsprungs disease. It is usually a part of the staged repair of anorectal malformation.

The use of colostomy is acceptable as important in the initial management of patients with anorectal malformation. This affords the neonates the ability to feed and evacuate from the stoma. Complications are common and not life-threatening.

**Keywords:** Colostomy, congenital, anorectal

**DOI:** <http://dx.doi.org/10.4314/ecajs.v21i2.7>

### Introduction

The use of colostomy in the management of congenital anomalies of the gastrointestinal tract (GIT) in newborns and infants is generally acceptable. Some of these GIT anomalies include anorectal malformations, Hirschsprungs disease, necrotizing enterocolitis, meconium plug amongst others. Acceptance of the use of colostomy in treating GIT problems in children have increased over the years. The use and management of GIT stomas in children have evolved since the early success with colostomy formation in the 1800s. The abdomen is by far the most common site for the intestinal stoma, although the neck and chest can also serve as sites<sup>1</sup>. Several types of intestinal stomas are recognized. The clinical scenarios often dictate the segment of intestine selected.

ARM constitute a spectrum of congenital anomalies that is characterized by absent anal opening or the presence of a fistula connecting the blindly ending rectum to the urethra or vagina/vestibular. ARM could be high, intermediate or low types depending on its severity. Colostomies are commonly indicated in high and intermediate types of ARM. ARM are one of the commonest causes of neonatal intestinal obstruction.

Overall HD and ARM are the commonest indications for the creation of colostomy in children 2.3.4. Recent reports from Europe<sup>5</sup> and Asia<sup>6</sup> indicates that ARM form the main indication for colostomy creation in children. However Ekenze et al reported HD as the commonest indication for colostomy creation<sup>2</sup>. Similarly some other studies have reported HD as the commonest

indication<sup>7,8</sup>. ARM and HD therefore form the commonest reasons for creation of colostomy in the paediatric age group.

Colostomies are defined as iatrogenic connection between the mucosa of the colon and the skin for the purpose of evacuation of the contents of the colon (faeces and fistula) to the exterior. It is grossly indicated for some conditions where there is failure of normal evacuation of colonic contents in neonates which are usually congenital. Creation of colostomy in these cases will allow the children to evacuate through the stomas so as to allow for feeding, growth and development. Colostomies creation is an essential component of the staged surgeries in the management of HD and ARM.

Its creation also comes with complications .Many potential stoma-related complications are recognized <sup>9,10</sup>. Skin excoriation and infection are the most common complications with paediatric stomas<sup>1</sup>.Other common complication include prolapse,retraction, stoma stenosis, stoma necrosis , parastomal hernias and psychological issues ; Candida infection is less commonly seen.

Most colostomies in the paediatric age are temporary and therefore will be closed when it has served its purpose as part of the staged repair of the GI anomalies. The establishment of luminal continuity by colostomy closure is usually the last stage in the treatment and is done after the anomaly has been repaired. This study highlights the use of colostomy in the management of anorectal malformation in our hospital. The study evaluates the challenges with colostomy; it also serves as a template for further research in this field.

### Patients and Methods

This was a prospective study of paediatric patients with ARM for whom colostomy was created. The study period was over one year (July - June 2015) in our hospital; the Federal Medical Centre Yenagoa which is a tertiary centre in the Niger-Delta region of Nigeria.

The types of ARM were noted and documented. Result of routine and specific investigations done were also noted. The patients were all subjected to similar mode of management based on their presentation. The biodata of the patients were recorded.

The data obtained were analyzed using SPSS and presented as counts, frequency and percentages. Categorical data were analyzed using Chi-square test and where necessary p-square values less than 0.05 and greater than 0.05 were regarded as significant and non-significant respectively.

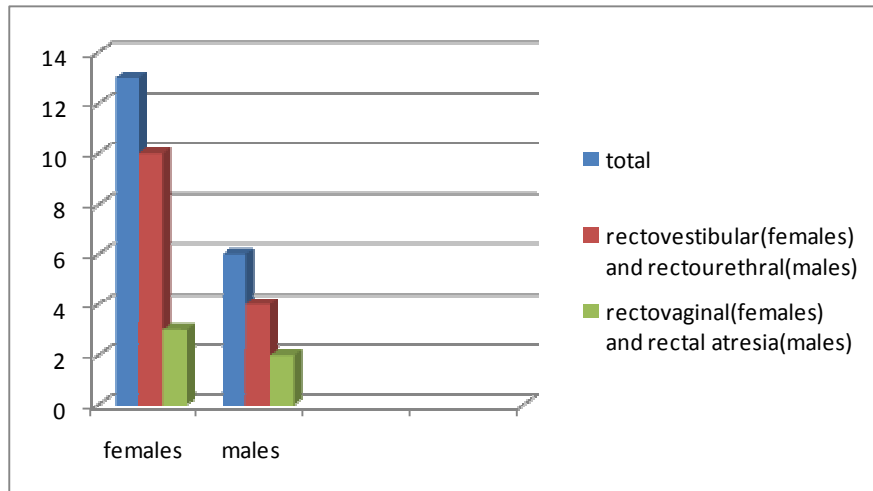
### Results

In this study a total of 19 patients with ARM had colostomy creation as part of the staged repair for ARM. Of this total 13(68.4%) were females and 6(31.6%) males with a M: F ratio of approximately 1:2.

**Table 1.** Timing of presentation

AGE	TOTAL	MALE	FEMALES
1 <sup>ST</sup> day(24hrs)	5	3	2
2 <sup>nd</sup> day(48hrs)	5	2	3
3 <sup>rd</sup> day(72hrs)	2	1	1
4 <sup>th</sup> day	1	-	1
5 <sup>th</sup> day	2	-	2
>5 <sup>th</sup> day	4	-	4

Rectovestibular fistula constituted 10(77%) of the total number seen in females with ARM while rectovaginal fistula made up the remaining 3(33%) (Figure 1). There were no other type of malformation seen in these females. In males, rectourethral fistula was seen in 4(66.6%) of the males with ARM while rectal atresia was seen in the other 2(33.4%). All the patients seen in this study presented in the neonatal period (<28days). The mean age of presentation was 3days. Males presented earlier than females. All the males (100%) presented within the first 72hours of life, while only 46% of females presented in the first 72hours of life. 30.7% of females presented after the 5<sup>th</sup> day of life and they were all cases of rectovestibular fistula.



**Figure 1.** Types of malformation seen in both sexes

**Table 2.** Timing of colostomy creation

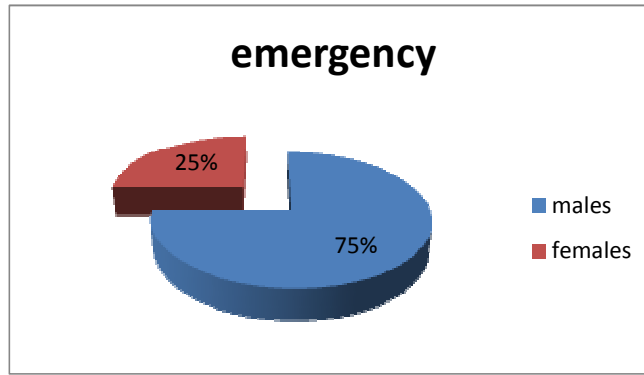
	Total	Males	Females
Emergency	4	3(75%)	1(25%)
Elective	15	3(20%)	12(80%)

At presentation the neonates were evaluated, resuscitated and investigated based on their presentation. The diagnoses were made based on a thorough history, physical examination and investigation. The type and level of malformation were also noted. A cross-table lateral X-ray is the gold-standard in determining the level of malformation by revealing the distance between the distal rectal air levels to the point of supposed anal opening which is usually represented by a radio-opaque material. All the patients in this study had high ARM thus the need for a colostomy.

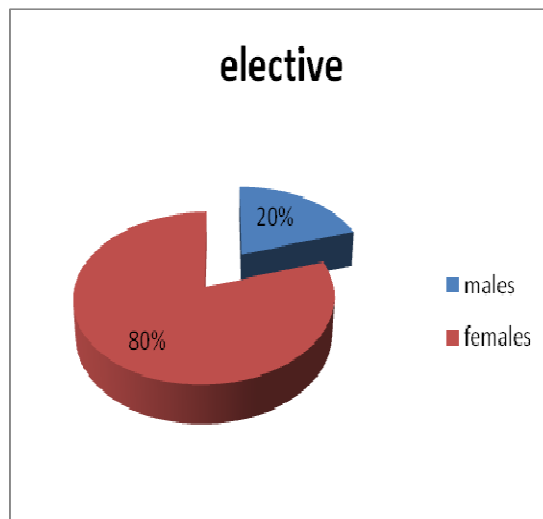
The colostomies were created as emergency or elective cases. A total of 4 patients (21%) had emergency colostomy, of this 3 (75%) were males and only 1(25%) was a female.

The majority of the cases were done as elective which is usually on the next operating list (Figure 2). A total of 78.9% of the colostomies were done as elective cases, 80% of this were done in males while 20% in females (Figure3). All the neonates had divided (Devine) sigmoid colostomy. This involves the transection of the sigmoid colon and exteriorizing the ends and suturing them to the skin as stomas (faecal and mucous fistula) (Figure 4)..

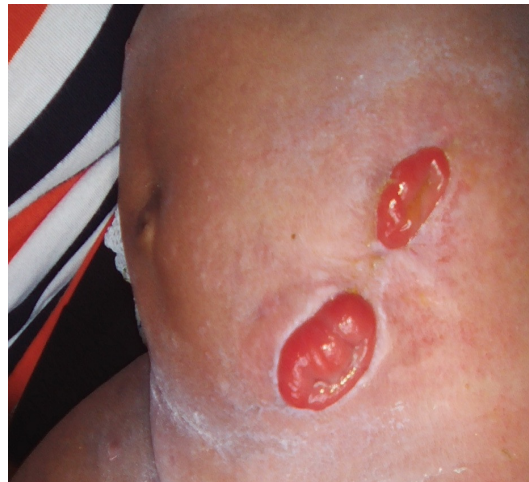The proximal stoma is the faecal fistula which allows for evacuation of faeces while the distal fistula is the mucous fistula which only evacuates mucous. There is an intervening skin in-between the two stomas. The average operating time from induction to end of surgery was 44minutes (range was 30 -55minutes). All the cases were done under general anaesthesia.



**Figure 2.** Emergency Colostomy



**Figure 3.** Elective Colostomy

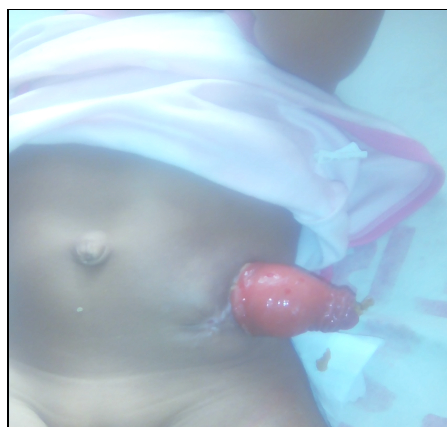

**Figure 4.** Faecal And Mucous Fistula

**Table 3.** Colostomy complications

COMPLICATIONS	Number	Percentage
Skin excoriation	15	79
Prolapse	4	21
Retraction	1	5.2
Stoma stenosis	1	5.2
Stomal bleeding	3	15.6
Colostomy diarrhoea	1	5.2
Dermatitis	9	47.3

There are a number of complications that have been associated with colostomies. Those seen in this study include skin excoriation, prolapsed, retraction amongst others (Table 3). There was a 15.7% revision rate (3 patients had colostomy revision). Two were cases of prolapse and one case of retraction. In these cases the patients had to be taken back to theatre for the reconstruction of the colostomy.



**Figure 6.** Prolapse and Stenosis

**Table 4.** Management Of Complications

Complications	Management
Skin excoriation	Use of zinc oxide cream. Effects noticed 48-72 hours after commencement
Prolapse	Colostomy revision done with re-establishment of stomas
Stenosis	Dilation using lubricated Hagers dilators
Retraction	Colostomy revision with re-establishment of stomas
Bleeding	Pressure dressing
Colostomy diarrhea	Dietary modification

Mortality rate was 0%. No death was recorded following the creation of the colostomy. All the patients were discharged home and had been seen on follow-up in the out-patient clinic while awaiting the definitive repair of the malformation. The definitive repair is a posterior sagittal anorectoplasty (PSARP) which involves the creation of a neoanus. Of the 19 patients studied in this study 9 (47.3%) has had PSARP. This will then be followed by the closure of the colostomy.

## Discussion

The construction of intestinal stoma (temporary or permanent) is an established procedure in surgery<sup>11</sup>. The creation of colostomy is a common procedure performed in children for some congenital anomalies of the GIT, especially in our subregion<sup>12, 13</sup>. Most of the colostomies are performed in the neonatal period and are temporary. Anorectal malformation is one of the commonest indication for creation of colostomy in children. This is usually done as a component of staged repair in the management of this malformation in children. However in many parts of the world (including Nigeria) there has been a progressive paradigm shift in this management protocol from the use of temporary colostomy to single stage repair<sup>11</sup>. With refinement in paediatric and neonatal anesthesia, improved facilities and sufficiently trained and available manpower single stage repair of ARM will only become more popular and practicable. Staged repair using colostomy still remains widely practiced worldwide. Acceptance had however increased in parents for the use of colostomy in this condition in children<sup>13</sup>.

ARM are a spectrum of congenital malformations of the rectum and anus leading to a diverging pattern of anatomic variations and presentations. The spectrum range from the complete absence of the anal opening with or without fistula to a simple membrane covering the anal opening. ARM could be classified as high, intermediate and low types. A cross-table lateral x-ray would usually reveal the type of anomaly.

In our series, ARM with rectovestibular and rectovaginal were seen in females, while in males ARM with recto urethral fistula and rectal atresia were seen in males. A total of 19 patients with ARM who had colostomy were studied. It was a prospective study of one year and was able to recruit 13 females and 6 males with a M:F ratio of approximately 1:2. This shows a female preponderance unlike the slight male preponderance generally known for ARM<sup>2,4,14,15</sup>. In females rectovestibular fistula accounted for 77% while rectovaginal fistula 33% which is in keeping with global figures<sup>3,7,8</sup>. In the males recto-urethral fistula was seen in 66.6% while rectal atresia constituted 33.4% without any associated fistula.

All the patients presented in the neonatal age with all the males (100%) presenting within the first 72 hours while 46% of the females presented within the first 72 hours of life. Close attention is needed by parents and caregivers to be able to identify females with rectovestibular and rectovaginal fistula on time. This is because the female neonates will usually evacuate faeces almost normally from the fistula. In such cases early recognition may be difficult. 30.7% of the female neonates presented after the 5<sup>th</sup> day of life and they were all cases of rectovestibular fistula.

Elective colostomies were more commonly performed in this study with a rate of 78.9%. Emergency colostomies were performed in 21.1% of cases. 80% of the neonates that had elective procedures were females while 20% were males. Most females could easily wait till the next operating list because they could evacuate to a reasonable extent while those females who had the procedure on emergency were not evacuating from the fistula (blocked fistula). In most males evacuation from urethra is not possible, so most had emergency

Sigmoid defunctioning colostomy was commonly performed in these patients. This was the preferred type of colostomy as it completely defunctions the distal aspect and will allow for a distal colostogram before the definitive procedure. Loop colostomy has a significantly higher rate of complication than defunctioning colostomy indicating that defunctioning colostomy is the preferred stoma technique<sup>2</sup>. Soomro et al however believe that loop colostomy is ideal<sup>11</sup>. In this study however sigmoid defunctioning (Devine) colostomy was preferred. In a retrospective cohort study intended to compare clinical outcome of loop and divided colostomies in patients with ARM, Oda et al found that the former, because of the higher incidence of prolapse carried a higher total complication rate than the latter but that the rates of other complications did not differ significantly between the two stomas<sup>16</sup>.

As for today despite the large large number of modifications of colostomy ,complications rates are still high<sup>12,13</sup>.A 30-80% overall complication rate is reported by many studies<sup>5,6,8,17,18</sup>.In this study skin excoriation was the commonest complication seen rate of 79%,this is similar to what was seen by Ekenze et al<sup>2</sup>. Other complications seen in this study included prolapsed (21%),retraction(5.2%),stoma stenosis(5.2%) and others as shown in Table 3.

Treatment of complications presents certain difficulties<sup>3</sup>. A colostomy revision rate of 15.7% was observed in this study. A total of 3 colostomy revisions were done, 2 for cases of prolapse and one for retraction. Four patients had prolapse and only two (50%) were revised. The others were managed conservatively. Once prolapse occurs it often becomes a chronic problem that can be difficult to correct. Surgical revision is indicated for the rare instances of ischaemia, obstruction, ulceration or chronic bleeding<sup>1</sup>.

Psychological issues can be significant for the child and the family<sup>16</sup>. A team approach to providing counseling, postoperative care and rehabilitation is crucial to the well-being of the patient <sup>1, 9, 10, 20</sup>.The participation of enterostomal therapists or nurse specialist is essential. However in many centers in Nigeria many of these stoma specialists are either absent or in short supply. Mortality figures following colostomy formation range from 0-3.3% <sup>2, 21,22</sup>. In this study there was no death.

## References

1. Robert K Minkes, Harsh Grewal. Stoma of mtghe small and large intestine . emedicine .medscape.com/article/939453.
2. S.O Ekenze, NEN Agugua-Obianyo ,C.C Amah. Colostomy for large bowel anomalies in children;a case controlled study. Int J of Surg. Aug 2007;5 (4):273-277
3. S.Nour,M.D Stringer,J Beck. Colostomy complication in infants and children. Ann R Coll Engl1996; 178(1): 526-530
4. A.J Miller,K.Lakhoo,HRode,.M.W Ferreira,R.A Brown,S.Cywes. Bowel Stomas in infants and children: a 5 year audit of 203 patients .S Afri J Surg 1993; 31: 110-113
5. M.K Cigdem,A. Onen,H.Duran ,H .Ozturk,S.Otcu. The mechanical complications of colostomy in infants and children, analysis of 473 cases of a single center. Paediatric Surg Inter 2006; 22: 671-676
6. B Chandranmouli,K. Srinivasan ,S.Jagdash,N.Anantrha-Krishan. Morbidity and mortality of colostomy and its closure in children. J Paediatr Surg 2004; 39: 596-599
7. J Lister,P J Webster, S Mirza. Colostomy complication in children. Practitioner 1983; 227: 229-237
8. D.L Mollit ,M.A Malangoni,T.V Ballantine,JL Grosfeld. Colostomy complication in children ;an analysis of 146 cases. Arch Surg 1980; 115: 455-458
9. Pearl RK,Prasad ML, Orsay CP. Early local complications from intestinal stoma. Arch Surg 1985; 120(10):1145-7
10. Ratliff CR, Scarano KA , Donovan AM. Descriptive study of peristomal complication .J Wound. Ostomy Continence Nurs 2005; 32(1): 33-37
11. Osifo OD,Osaigbovo EO, Obeta EC. Colostomy in children ,indications and common problems in Benin City Nigeria.Pakistan J of Medical Sciences.June 2008; 24(3)
12. Uba AF,Chiordan LB,Colostomy complications in children. Ann Afri Med 2003; 2; 9-12
13. Ameh EA, Mshelbwala FM, Sabiu L,ChirdanLB. Colostomy in children an evaluation of acceptance among mothers and care-givers in a developing country. S .Afri J Surg 2006; 44:138-9
14. Soomro B.A ,Solangi R.D,Siddique,M.A . Colostomy in children ;Indications and complications. Pakistan J of Med Sciences Oct 2010; 29(4): 883
15. al-Saleem AH, Grant C,Khawaja. Colostomy complications in infants and children. Int Surg 1992; 77(4):164-166
16. Holschneider AM,Hutson JM. ARM in Children, Embryology,diagnosis,surgical treatment ,follow-up. Berlin Heidelberg, Springer-Verlag,Germany
17. A Pena,M Migotto-Krieger,M.A Levitt.Colostomy in anorectal malformation ;a procedure with serious but preventable complications.J Paediatric Surg 2006; 41: 748-756
18. R.W Brenner,O .Swenson. Colostomy in infants and children . Surg Gynaecol Obster 2007; 124: 1239-1244
19. Brown H ,Randle J .Living with a stoma ; a review of the literature..J Clin Nurs 2005;14(1): 74-81



- 
20. Oda O, DaviesD, Colapinto K, Gerstle JT. Loop versus divided colostomy for the management of anorectal malformation. J Paediatric Surg 2014;49(1):87-90
  21. M.A Shinkh, J Akhator, S Ahmed. Complications and problems of colostomy in infants and children. J Coll physician Surg Pak 2006; 16: 509-513
  22. N Patwardhan, E.M Kiely, D.P Drake, J Spitz, A Pierro. Colostomy. J Paediatric Surg 2001; 36: 795-798