

## A Comparative Study of Sclerotherapy With Phenol Versus Surgical Treatment For Hydrocoele

<sup>1</sup>Labib M A MD urology, FRCS (Ed), <sup>2</sup>Munthali G MB BCh

<sup>1</sup>Senior Lecturer, Head of urology section, <sup>2</sup>Registrar, University Teaching Hospital, Lusaka, Zambia.

*Correspondence to:* M.A. Lahib, University of Zambia, P.O.Box 33982 Lusaka- Zambia. E mail: [labib@zamtel.zm](mailto:labib@zamtel.zm)

**Background:** A comparison for the effectiveness, side effects and outcome of sclerotherapy using phenol and surgical treatment for hydrocoele was done at UTH in Lusaka, Zambia..

**Materials:** A total of 80 patients were randomly divided into 2 groups of 40 hydrocoeles each. Group A underwent phenol sclerotherapy and Group B underwent hydrocelectomy.

**Results:** In sclerotherapy group 47.5%, 32.5%, and 15% of the hydrocoele were cured with 1 to 3 injections, respectively, but 4% were not cured. There were no complaints of localized pain or infection in these cases. All patients returned to normal activities on the same day. In hydrocelectomy group, all the patients were cured. There was pain postoperatively in 73.5% of the patients and localized infection in 9%, while 65% required an average of 4 days of rest and were absent from work for 10 days.

**Conclusion:** Sclerotherapy for hydrocoele using phenol is as efficient as hydrocelectomy for cure, has a low risk of complications and allows the patients to return to normal activity on the same day. Sclerotherapy is recommended as an option for treatment of hydrocoele.

### Introduction

Surgical treatment for hydrocoele has been done successfully since the beginning of the common era but it is traumatic, painful and in the past caused risk, a high morbidity rate and prolonged convalescence<sup>1</sup>. In 1975 Moloney used phenol and observed that sclerotherapy for hydrocoele was efficient treatment<sup>2</sup>. Other agents have been used including tetracycline, adhesive fibrin, and absolute alcohol. A prospective randomized clinical study comparing sclerotherapy with hydrocelectomy was undertaken to assess the efficacy of the two procedures for hydrocoele treatment.

### Patients and Methods

A total of 80 patients with a clinical diagnosis of hydrocoele were treated from March 2002 to March 2003. The patients were randomly divided into two groups. The 40 patients in the Sclerotherapy Group were aged between 27 and 85 years with a median age 61 and had had the disease for a duration of between 2 and 48 months with an average of average 23.5 months. The 40 patients in the Surgical Group were between aged between 17 and 69 years with a median age of 56 years and with duration of the disease of between 1 and 39 months and an average of 19.8 months.

Sclerotherapy under an aseptic technique was performed on an outpatient basis with the patient in normal clothing and without any scrotal shaving. The patient was placed supine. The puncture area

was identified and cleaned with a local antiseptic. This was followed by infiltration of the skin and subcutaneous tissue with 2% lidocaine hydrochloride without adrenaline. Scrotal puncture was done with multiperforated 18 gauge intravenous cannula. Manipulation of the scrotum resulted in complete emptying of the hydrocoele. Subsequently 2% lidocaine hydrochloride was injected into the cavity between the tunica vaginalis in the proportion of 1% of the volume of the drained up to a maximum of 5 ml. After 1 minute the anaesthesia was removed and 2.5% phenol in aqueous medium with a pH of between 4 and 6 was injected. The volume of phenol injected was calculated to correspond to 10% of the volume of the drained hydrocoele when less than 400 ml., and to 5% of drained volume when it exceeded 400 ml. The maximum limit established was 50 ml. Phenol. Neither analgesic nor antibiotics were used.

The patients were clinically reassessed at 1, 3, 6, 9, and 12 months after the sclerotherapy procedure. After the first month, patients with complete relapse underwent a repeat application using the same technique. In cases of partial relapse that maintained a steady decrease, a further application was done at the end of every third month.

Patients in the hydrocelectomy group were treated as inpatients with partial excision and eversion of the parietal tunica vaginalis. Patients were clinically assessed on day 6, and at 1, 3, 6, 9, and 12 months after hydrocelectomy. The percent of hydrocele relapse per group, pain, the need for rest

and absence from work, and the incidence of localized infection were studied in the 2 groups.

## Results

Table 1 lists volumes obtained from draining the hydrocoeles in sclerotherapy group. Of the 40 hydrocoeles 39 (95%) were cured with 1 to 3 injections ( fig.1 ) . There were no complaints of localized pain or any infection in any patients. Of

the 40 hydrocoeles 39 (97.5%) were cured with 1 operation. One patient needed re-operation after 9 months to achieve cure. In 25 patients (73.5%) there were complaints of post-operative pain 1 to 21 days (average 6.7 days). A total of 25 patients (62.5%) reported that they rested for 3 to 15 days (average 3.2 days). Four patients with signs of infection post-operatively were treated with doxycycline for 10 days.

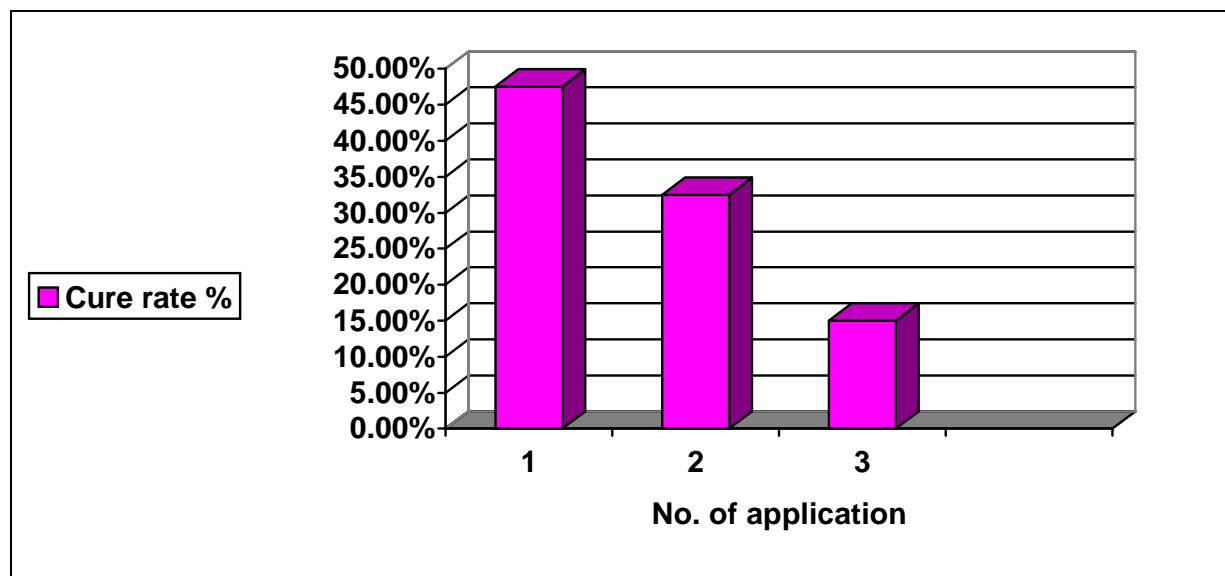
**Table 1.** The Volume Of Injections And Hydrocoele, Volume Withdrawn And Volume Of Phenol Injected.

| No. Injections | No. Hydroceles | Withdrawn Volume (Mean ) | Injected Volume |
|----------------|----------------|--------------------------|-----------------|
| 1              | 40             | 23 - 825 (223.6)         | 5-50            |
| 2              | 13             | 10 - 495 (108)           | 3-35            |
| 3              | 6              | 8 - 145 (54.6)           | 6-23            |

**Table 2.** Percentage Complication rate of various agents for sclerotherapy

| Sclerosing Agent          | Pain | Haematoma | % Fever | % Infection |
|---------------------------|------|-----------|---------|-------------|
| Tetracycline              | 10.7 | 7.1       | 0       | 0           |
| Ethanolamine              | 50   | 2         | 15      | 3           |
| Sodium Tetradecyl Sulfate | 49   | 0         | 9       | 0           |
| Alcohol                   | 26.6 | 0         | 0       | 0           |
| Antazoline                | 7.5  | 0         | 0       | 0           |
| Phenol                    | 1.8  | 0         | 0       | 0           |

**Figure 1.** Cure Rate and Number Of Applications



## Discussion

The progressive historical tendency in the types of treatment advocated shows the quest for greater

patient comfort and less aggressive procedures. Sclerotherapy for hydrocoele was perhaps one of the first attempts to adopt a less invasive procedure<sup>3,4,5</sup>. However, opinions on the procedure have not

yet achieved unanimity. Phenol, which is a chemical product much, used in the past as an antiseptic, is easily obtained, efficient for hydrocoele and has the least complication rate<sup>3,5,6,7,10</sup>.

Immediately after the sclerotherapy new liquid accumulated within the testicular sac, attaining a maximum volume between weeks 2 and 3. There followed a gradual regression with complete disappearance of the liquid between months 2 and 3, when adherence of the layers occurred<sup>5</sup>.

For the group B, we chose the technique of partial excision and eversion of the tunica vaginalis because this technique is classically accepted as a standard method for the cure of hydrocoele<sup>8,9</sup>. In the post-operative period all patients who underwent hydrocoelelectomy had different degrees of edema with hardening of and pain in the testicular sac. On post-operative day 6 at the first assessment 85% of the patients had moderate or accentuated edema and scrotal hardening, and pain at touching, which continued until the end of first month.

Rodriguez et al<sup>8</sup> showed that in operations requiring greater manipulation, such as dissection and ample removal of tunica vaginalis, the incidence of edema was 91%.

### Conclusions

Sclerotherapy for hydrocoele using phenol is as efficient as hydrocoelelectomy for cure. The risk of complications arising from phenol sclerotherapy is slight, while it allows the patient to return to normal activity on the same day, so sclerotherapy may be the option of choice for hydrocoele.

### References

1. Lander Y K, Leonhardt K. The history of hydrocoele. *Urol Surg* 1966; 17: 135-138
2. Moloney, G.T.: Comparision of results of treatment of hydrocele and epididymal cysts by surgery and injection. *Br Med*, 1975; Vol.3, Pp 478-480
3. Chen, J,S,: Escleroterapia de hidrocele com fenol. *J bras Urol*, 1998; Vol.24, Pp 258-161
4. Savion, M., Wolloch, Y. and Savir, A.: Phenol sclerotherapy for hydrocele: a study in 55 patients. *J Urol*, 1989; Vol.142, Pp 1500-1503
5. Levine, L.A. and DeWolf, W.C.: Aspiration and tetracycline sclerotherapy of hydroceles. *J Urol*, 1988; Vol.139, Pp 959-962
6. Hu, K.N., Khan, A.S, Gonder, M.: Sclerotherapy with tetracycline solution for hydrocele. *Urology*, 1982; Vol. 24, Pp 572-575
7. Rencken, R.K., Bornman, M.S., Reif, S. and Olivier, I.: Sclerotherapy for hydroceles. *J Urol*, 1990; Vol.143, Pp 940-943
8. Rodriguez, W.C. and Fortuno, R.F.:. The operative treatment of hydrocele: a comparison of 4 basic techniques. *J Urol*, 1981; Vol.125, Pp 804-808
9. Roosen, J.U., Larsen, T., Iversen, E. and Berg, J.B.: A comparison of aspiration, sclerotherapy and surgery in the treatment of hydrocele. *Br J Urol*, 1991; Vol.68, Pp 404-406
10. Chen J.S., Antonio, M.L. and Sami, A.: *J Urol*, 2003; Vol.169, Pp 1056-105