

Experience with Ultrasound of the Knee Joint at Mulago Hospital, Uganda

E. Wakamuke, M. Kawooya, E. Kiguli Malwadde, Z. Muyinda
Mulago Hospital, Kampala – Uganda.

Correspondence to: Dr. E. Malwadde, Email: <kigulimalwadde@gmail.com>

Background: The knee is prone to various pathology. Mulago Hospital records of 2001/2002 show that an average of 432 patients with knee joint disorders are seen in orthopaedic and rheumatology outpatient clinics out of a total of 5400 patients annually. For a long time the only mode of radiological investigation for these patients has been x-rays of the knee joints and this meant that limited information was got about the soft tissue component of the knee. Advances in technology with high frequency transducers, power Doppler ultrasound and extended field of view function have facilitated the progressive development of musculoskeletal sonography (MS). In developing countries like Uganda, where advanced imaging modalities like MRI are unaffordable and not readily available, ultrasound U/S serves as an efficient substitute in trained hands. This study was aimed at describing the sonographic pattern of knee joint pathology at Mulago Hospital in patients with knee joint symptoms.

Methods: A cross sectional descriptive study of the sonographic pattern of knee joint pathology was performed at Mulago Hospital from July 2004 –February 2005. A total of 107 consecutive patients referred to the Radiology department with knee joint pathology were studied. The patients' socio-demographic data, clinical history and physical examination were recorded. Sonography of the knees was done using U/S machines [ATL-HDI 1500, Sonoace [Medison] SA8800 & SA9900] with high frequency linear transducers (7-12 MHz) The sonographic appearance of joint fluid, synovitis, loose bodies, bursae and cysts, tendon, menisci and ligament pathology were recorded. The data was entered in the computer using Epi-data soft ware and analysed using the SPSS version 10.

Results: A total of 107 patients had their knee joints evaluated with U/S. The age range was from 2 months to 80 years. The mean age was 38.0 and median 36 years. The commonest presenting symptoms were painful swelling of the knee 55(51.4%), pain 39 (36.4%), swelling and inability to move were 6 (5.6%). Sonographic features revealed osteoarthritis was the most frequent 22(59.5%), loose bodies were 7 (18.9%) and fractures 2(5.4%).

Conclusion: U/S can ably evaluate the pathology of menisci, ligaments, tendons and muscles. The majority of the knee joint pathology disorders were as a result of the degenerative disease. In view of the fact that MRI is not readily available and is expensive, U/S goes a long way in contributing to the diagnoses of knee joint pathology in a low resourced countries like Uganda.

Introduction

Using U/S as a clinical investigative tool started in 1950's. However, its application in imaging of MS remained underutilized till 1980's^{1, 2}. Soft tissue pathology of the knee represents one of the more common, yet perplexing, musculoskeletal disorders presenting at Mulago Hospital. Knee pain and related symptoms may come as a result of damage to one or more of the soft tissue structures that stabilize and cushion the knee joint, including the ligaments, muscles, tendons, and menisci. Mulago Hospital records of 2001/2002 show that an average of 432 patients with knee joint disorders were seen in orthopaedic and rheumatology outpatient clinics out of a total of 5400 patients annually. In a country with a population of 26 million people, it contributes significantly to the burden of disease. The only mode of examination for these patients has been x-rays of the knee and this meant that little information was got about the soft tissue component of the knee. Yet U/S of the knee joint can yield a lot more information on the bursae, tendons, muscles, ligaments menisci and joint space pathologies.

In this study, the sonographic pattern of knee joint pathology at Mulago Hospital was reviewed.

Patients and Methods

A cross sectional descriptive study of the sonographic pattern of knee joint pathology was performed at Mulago Hospital. This was done from July 2004 –February 2005. One hundred and seven consecutive patients referred to the Radiology department with knee joint symptoms were recruited. The patients' socio-demographic data, clinical history and physical examination findings were recorded. Sonography of the knee joints was done using U/S machines [ATL-HDI 1500, Sonoace [Medison] SA8800 & SA9900] with high frequency linear transducers (7-12 MHz) The knee was examined in four positions: Anteriorly, posteriorly or popliteal fossa, laterally and medially. The sonographic appearance of joint fluid, synovitis, loose bodies, bursae and cysts, tendon, mensci and ligament pathology was recorded. For each position, transverse and longitudinal views were done. Joint effusions were readily detectable by US as anechoic area bounded by the joint capsule. A simple effusion was anechoic. Diffuse increase in echogenicity suggested infection or haemarthrosis. Simple bursitis was depicted as anechoic fluid, with or without septa (*fig 1A*). In chronic bursitis, there was bursal thickening seen as a band of moderate echogenicity. With complications like infection or haemorrhage internal echoes were detected in the fluid (*fig 1B*). Synovitis was demonstrated as diffuse nodular thickening of the joint or bursal margins, or as nodular thickened folds of synovium within an effusion and occasionally, flow was visible on a power Doppler examination, (*fig 2A*). In some cases synovial pannus would be mistaken for fluid. Graded compression was used to distinguishing between these two entities. Loose bodies detection was dependent on demonstrating a focal echogenic structure, completely separated from other structures, lying within the joint space, (*fig 3A*). Meniscal cysts were shown as anechoic fluid collections characteristically lying at the margin of the knee joint underlying the meniscus. They gave a characteristic appearance of an "ice cream cone," (*fig 4Ai*). Meniscal tears were recorded as discrete hypoechoic clefts coursing in the oblique fashion through a hyperechoic triangular meniscus. Meniscitis were seen as hypoechoic triangular mensci.

Baker's cysts were seen to arise from the semimembranosus bursa and protrude posteriorly to overlie the gastrocnemius muscle. The simple cysts were uniformly anechoic while internal echoes were in the complex cysts. In rupture of Baker's cysts there was abnormal and irregular hypoechoic or anechoic areas at the distal aspect of the cyst. Larger fluid collections extended distally and were located superficial to the medial gastrocnemius muscle. The double wall of the Baker's cyst was noted. Residual irregularity or hyperechoic scar tissue at the distal aspect of a Baker's cyst indicated a remote rupture. Ruptured Baker's cysts were differentiated from deep venous thrombosis by Doppler studies. Tendon pathology was also evaluated. Full-thickness tears appeared as echopoor focal defects in the fibre bundles, or as focal contour deformities, particularly when local pressure was applied with the transducer. Tendon calcification was shown as focal brightly hyperechoic area with variable degrees of posterior shadowing. Focal tendon swelling coupled with decreased echogenicity was reported as tendinosis. Tenosynovitis was shown as thickening of the tendon sheath or a hypoechoic rim around the tendon due to fluid or synovitis. Sonographic features of Osgood-Schlatter disease were demonstrated as cortical discontinuity of the tibial tuberosity associated with tendonitis of the patella ligament. The sonographic appearance of ligaments of the knee is similar to tendons characterized by parallel echogenic fibre bundles. Ligament tears were demonstrated as interrupted echogenic fibrillar pattern by hypoechoic granulation tissue when completely torn, or have focal internal hypoechoic areas with partial tears. Injury to the medial collateral ligament was also detected as a thickened heterogeneously hypoechoic band. Muscle tears were also seen. The partial thickness tears in the muscle were recognized as a discontinuity in the pinnate pattern or hypoechoic areas within the muscle. Lipomas were shown as hyperechoic masses with posterior attenuation within the muscle fibre without distorting architectural pattern, while calcifications were small hyperechoic structures with or without acoustic shadow. Haematomas and tumours had almost similar appearances with variable echogenicities.

Colour Doppler was used to distinguish viability of the tumour by demonstrating flow from the haematomas which had no flow. All the above sonographic features were demonstrated by at least 2 radiologists. The data was then entered in a precoded questionnaire which was then transferred into the computer using Epi-data soft ware and analysed using the SPSS version 10.

Results

A total of 107 patients with knee complaints were recruited in the study. Their ages ranged from 2 months to 80 years. The mean age was 38.0 and median 36 years. The peak age was in the 31-40 years age group which accounted for 30 (28.0%) cases. Females were 61 (57%) while 46 (43%) were males. The male: female ratio was 1:1.4. A painful swollen knee was the commonest presenting complaint by 51.4%. Pain alone was the second commonest symptom 36.4%. Out of the 107 patients seen 51 (47.7%) of them were office workers, 43(40.2%) were manual labourers and 13 (12.1%) were children and students. Thirty eight (35.5%) of patients were referred with a suspicion of osteoarthritis, 12 (11.2%) patients were suspected to have knee effusions and eight (7.5%) cases had diagnoses of ligament tears. The clinical diagnoses of haemarthrosis, meniscal tears and pyogenic arthritis each were recorded in 6 (5.6%) cases. Post traumatic arthritis was diagnosed in 5 (4.7%) cases. The rest of the cases 24.3% had various diagnoses including Baker's cyst, meniscal cyst, loose bodies and Osgood-Schlatter's disease. One patient had no diagnosis

The pathology was unilateral in 91 patients while 18 patients had pathology in both knees. This means that a total of 125 knees were scanned. Ninety five patients (89.8%) scanned had pathology in the knee joints while 12 patients (11.2%) had normal knee joints. Out of all patients scanned, normal knee joints were seen in those below 40 years while those above this group all the knee joints had pathology. A total of 85 cases were diagnosed with ultrasound as abnormal, 50 of which had normal x-ray findings.

Knee joint space pathology: In the knee joint space, it was found that osteoarthritis was commonest 22(20.6%), followed by loose bodies 7(6.5%), arthritis 6(5.6%) and fracture (1.9%). The above sonographic pathology was correlated with age, sex, and occupation. Osteoarthritis was common above 40 years, while loose bodies were more prevalent in the younger less than 40 years. Overall, more females were affected than males. Fifteen 15(14%) female had osteoarthritis compared to 7(6.5%) males. However, occupation does not seem to pose a risk in the development of knee joint diseases, except in osteoarthritis where there were 13(12.2%) manual labourers compared to 9(8.4%) office workers. Significantly students and children were not found to have any knee joint space pathology.

Bursal sonopathology: The suprapatella bursa was affected in 25 (23.2%) cases. Sixteen (14.8%) were simple effusions while the 9(13.3%) depicted internal echoes. This was observed in pyogenic arthritis and hemoarthrosis. These 2 conditions were confirmed on aspiration. Baker's cysts were demonstrated in 39 (36.2%) of cases and 14(13.0%) were regarded as complicated due to the presence of internal echoes. Four (3.7%) cases were documented for the pes anserinus and three 3(2.8%) infrapatellar bursitis. Of all Baker's cysts diagnosed, 32 (80%) occurred in patients aged above 30 years of age. Two peaks were observed at 31-40 years and 51-60 years age groups. There was no case of Baker's cysts recorded under 10 years of age. One subcutaneous cyst was recorded in the popliteal fossa in 0-10 age group. More females with Baker's cyst 30(75%) than males 9(22.5%) were recorded with female: male ratio of 3:1. There was no significant difference between the office workers 19 cases (47.5%) and manual labourers 20(50%). The majority of the suprapatella effusions 21(84%) were seen in cases above 30 years of age. The peak was noted at 31-40 years age group with 11 (44%) cases. Only 4 cases (16%) were recorded below 20 years of age. Majority of the cases with bursitis of the suprapatella bursa 34 (97.1%) were above 20 years. Two peaks were recorded 21-30 years age group 10(28.6%) and 51-60 years age group 8(22.9%) cases.

Meniscal pathology: Two patients (1.9%) had meniscal cysts, 4 (2.8%) meniscitis and 1 (0.9%) meniscal tear.

Ligaments, tendons and muscles pathology: Sonographic evaluation of the ligaments of the knee showed that 3 (2.8%) had tears, 6(5.6%) had ligamentitis and 1 (0.9%) had tumor. Two (1.9%) of the patients had Osgood-Schlatter's disease. One (0.9%) case of tendon tear was demonstrated. In the quadriceps muscle, 3 (2.7%) cases had partial thickness tears, 2(1.8%) haematomas, 1(0.9%) lipoma and another 1(0.9%) dystrophic calcification .

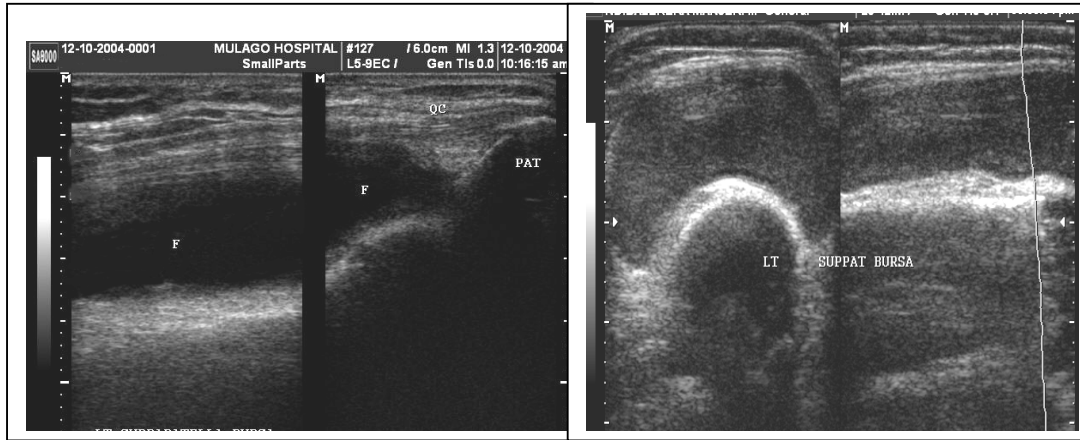


Figure 1A

Figure-1B

Figure 1A is a simple effusion shows anechoic fluid in the suprapatella bursa. Fig 1B shows fluid in the suprapatella bursa with internal echoes.

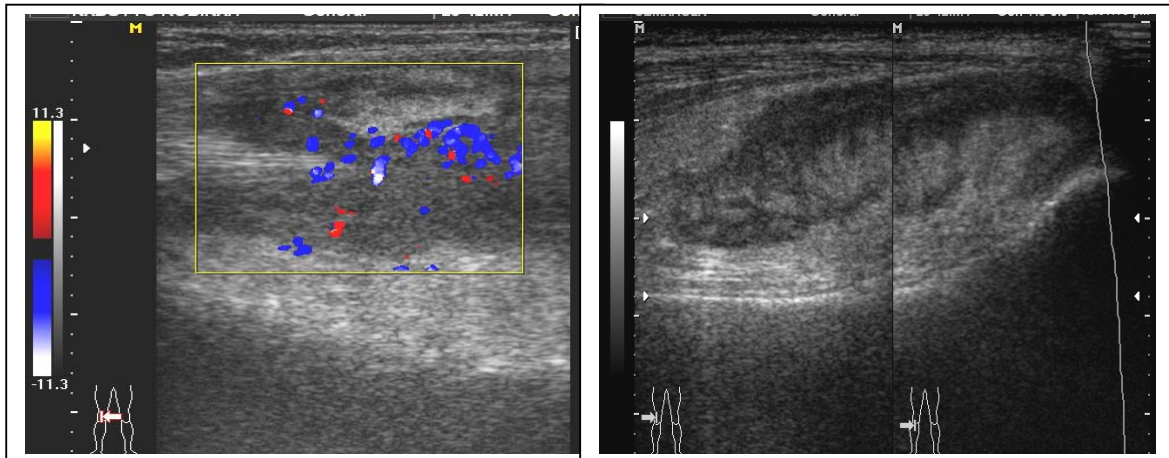


Figure 2A

Figure 2B

Fig 2A shows a markedly thickened suprapatella bursa. At colour Doppler imaging there is increased blood flow which is in keeping with suprapatella bursitis & fig 2B illustrates pannus in the suprapatella bursa in patient with osteoarthritis of the knee

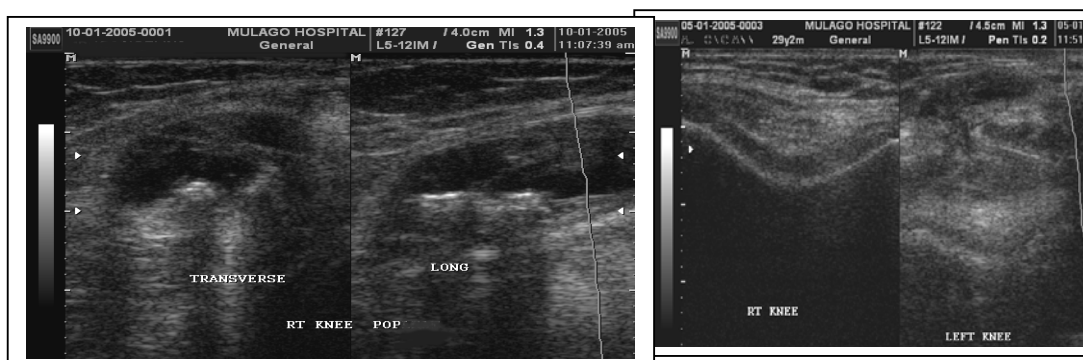


Fig 3A

Fig 3B

Figure 3A. Loose bodies in the Baker's cyst with posterior acoustic shadowing.

Figure 3B. Ill definition of the left anterior femoral hyaline cartilage. The right knee is normal

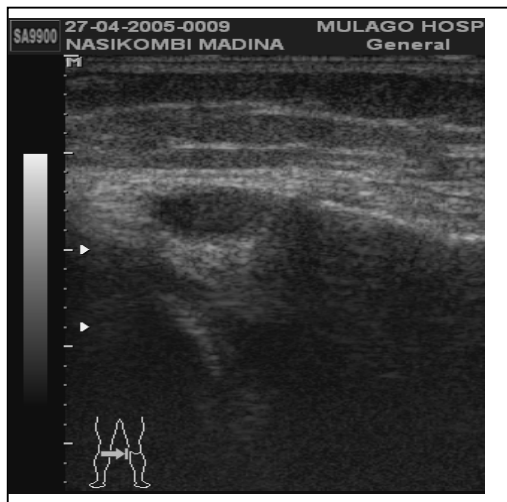
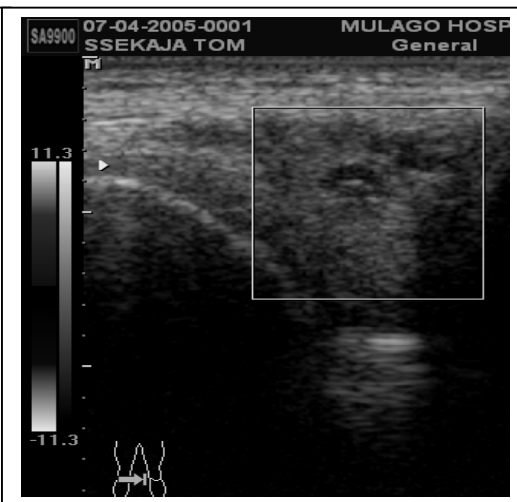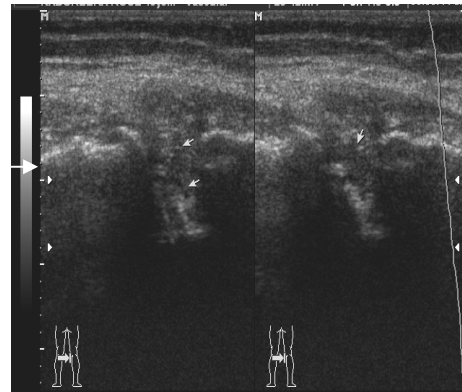
**Fig 4Ai****Fig 4A ii**

Fig 4Ai, demonstrate impalpable meniscal cyst in the base of the menisci & ii shows a blood vessel.

Fig 4B: show an ill-defined mixed echogenicity medial meniscus but predominantly hypoechoic, a crushed meniscus. The arrows are pointing at the small tears within the meniscus.

**Fig 4B**

Discussion

Ultrasound is an established modality in the diagnosis of knee disorders. In our series of 107 patients who had U/S of their knees, more females presented for U/S of the knee than males. This may be explained by the statistics of the Uganda population and housing census of September 2002, where the females 51.1 %³. At the same time, it is known that a number of women present with arthropathies following pregnancy, obesity and post-menopausal osteoporosis⁴.

Knee joint pain and swelling were found to be the commonest clinical presentations. This was similar to what was observed by Verena T. Valley et al⁵. However, we noted that clinical examination alone or attempted blind joint aspiration could not reliably provide diagnosis. For this reason sonography was employed and more information was obtained.

We observed that office workers 51(47.7%) had more knee disorders compared to the manual labourers 43(40.2%). There was a high prevalence of knee disorders among individuals of working age compared to children and students 13 (12.1%). It supports the findings of the prospective case-control study that surgically treated meniscal injury is associated with sporting activities especially soccer and rugby and with occupational kneeling and squatting⁶. In Uganda, rugby and soccer sports are dominated by the elite group who are also office workers. The children and students contributed only 12.1% of the total cases seen which is inversely proportional to the rest of the population of Uganda. Zero to fourteen years

contributes 50.6% of the Ugandan population according to Uganda Housing and population census 2002³. Most of the knee disorders increase with increasing age.

A spectrum of knee U/S findings were demonstrated. Although we found degenerative osteoarthritis occurred in patients of 40 years and above, this differed from Skimmer and Sherger⁷ who reported that it is usually uncommon in the age group 41-50. However Uganda has a relatively young age population than in developed countries. In cases of patients less than 40 years who had knee osteoarthritis, there was previous traumatic injury to the knees 5-10 years before the onset of knee symptoms. U/S was able to detect early degenerative processes where plain radiographs were reportedly normal.

In septic arthritis, the fluid frequently had a hypoechoic appearance with internal echoes (particulate appearance)⁸. All patients with septic arthritis had knee arthrotomy to confirm the diagnosis. The effusions associated with chronic inflammatory arthritic conditions, such as rheumatoid arthritis (RA), were often difficult to differentiate from acute infective arthritis. One sonographic sign of infection versus a rheumatoid joint is a marked increase in intra-articular fluid without a concomitant increase in synovial thickness. The amount of joint effusion is proportionate to the amount of synovial thickening with flaring in rheumatoid arthritis⁸. However, septic arthritis cannot be ruled out based solely on the sonographic appearance^{9,10}. One case reported in this study had rheumatoid arthritis with positive radiographic features, U/S as well as a positive rheumatoid factor. Synovial hypertrophy or pannus, are most commonly seen in inflammatory arthritis, but can also be found in chronic infections (tuberculosis, brucellosis, Lyme disease, or fungal infection)⁸.

The suprapatellar effusions were seen in 25(23.3%) cases. Ultrasound has a high accuracy for identification and characterization of joint effusions^{11,12}. Ptasnik¹³ observed that the presence of increased flow on color or power Doppler imaging or tenderness during transducer palpation are indicative of an inflammatory state consistent with true bursitis. Infrapatellar bursitis was reported in 3 (2.8%) cases. Infrapatellar bursitis, "clergyman's knee," has been reported to be due to kneeling in the upright posture. It was characteristically noted that more females got the bursitis compared to males. This could be due to the fact that in most of our communities, females kneel when greeting or when performing most of the activities at home. The synonym suggests that this condition is common among the clergy.

Studies done by Ward et al¹⁴ have shown that identification of fluid between the semimembranosus and medial gastrocnemius tendons in communication with a posterior knee cyst indicates Baker's cyst with 100% accuracy. In this study, these features were demonstrated in all cases where the Baker's cyst was found. Among the complicated cysts, 2(1.9%) had pus which was confirmed at aspiration and later arthrotomy was done. The knee fluid aspirate in adults cultured staphylococcus aureus while in a neonate the cultures grew Escherichia coli. One (0.9%) case of a subcutaneous popliteal cyst mimicked Baker's cyst clinically. Sonography has been found useful in differentiating between deep venous thrombosis and ruptured Baker's cyst¹⁵. We saw one patient with a ruptured Baker's cyst. Rupture of a Baker's cyst frequently presents with the sudden onset of pain in the calf. In addition to this, the sonographic findings mimic DVT, however Doppler study of the popliteal vein was normal in this case.

Rasmussen¹⁶ found out that in acute tendonitis, the tendon appeared swollen and hypoechoic with loss of the fibrillar structure which correlated with our study findings. Calcifications may be seen in chronic cases. Two cases (1.9%) of Osgood-Schlatter disease were recorded in this study. One of the patient was 16 years a boy and the other 18 years, a girl. Literature shows that the disease predominates in adolescence between 11 and 15 years old¹⁶. In the study done by De Flaviis et al¹⁵ found out that the boys are affected more frequently than girls. Both our patients had a history of participation in sports and a rapid growth spurt as reported in literature. The condition is bilateral in 25% of patients. The cause of the condition is thought to be traumatic in origin, resulting in avulsion of fragments of cartilage and bone from the tibial tuberosity¹⁷. Three (2.7%) cases had partial tears of the quadriceps tendon. Two (1.9%) haematomas cases were associated with the tears. Our observations at U/S were similar to those described by Zeiss et al¹⁹ and Bianchi et al¹⁸.

When haematoma distorts the normal tendon architecture it allows identification of these injuries as reported by Takebayashi et al²⁰. Typical U/S appearances of ligament tears were demonstrated in 3 (2.7%) cases as described in literature²¹.

Meniscal cysts were identified in 3 (2.7%) cases. Literature reveals an underlying meniscal tear can be identified in some patients, communicating with the meniscal cyst²³. In our documentation, there were no sonographically detected meniscal cysts co-existing with tears. Various authors indicate the incidence of meniscal cysts varies from 1 to 20 %²⁴. Three (2.9%) cases of meniscal tears which were recorded in this study were a result from a fall on the knee. Reports reveal that majority of patients with meniscal tears are in their 20s²³. One patient was in the second decade and the other two were in the fourth and fifth decades respectively. Because the meniscus has such important functions in load bearing and stability of the knee, loss of this structure in the young is associated with significant degenerative changes which may be depicted on U/S in addition to meniscal pathology

Conclusion

The majority of patients at Mulago Hospital with knee pathology have degenerative disease. Ultrasound provides very useful information on the status of menisci, ligaments, tendons and muscles in low resourced country like Uganda where MRI is expensive and accessible only to a few. Knee recesses are best evaluated by US due to its ability to characterize masses as either fluid or solid. Application of Doppler study is imperative in cases of suspected ruptured cysts to differentiate them from DVT. Though U/S has its technical limitations, provides useful diagnostic information which is relevant to subsequent patient management.

References

1. Sharlene A., Teefey, William D., Middleton, Ken Yamaguchi et al: Shoulder sonography state of Art. Radiological Clinics of North America 1999; 767-784.
2. Mamix T., Van Holsbeeck, Patricia A., Kulowich, William R., Eyler, Joseph G., Craig Kahalil K., Shirazi, Ghiyath K., Habra. Ultrasound Depiction of Partial thickness tears of the rotator cuff. Radiology 1995; 197:443-446.
3. Uganda Housing and population census 2002
4. Hannan MT et al Risk for Longitudinal bone loss in elderly men and women. The Framingham Osteoporosis study. J bone Miner Res 200; 15:710-720
5. Verena T. Valley, MD and Sarah A. Stahmer, MD Targeted Musculoarticular Sonography in the Detection of Joint Effusions Academic Emergency Medicine Volume 8, Number 4 361-367
6. Andrish JT: Meniscal injuries in children and adolescents: diagnosis and management. J Am Acad Orthop Surg 1996; 4(5):231-7.
7. Harry B. Skinner, Joseph E. Scherger, Identifying structural hip and knee problems. Postgraduate medicine December 1999;106 : 7
8. Van Holsbeeck M, Introcaso JH, eds. Sonography of Bursae in Musculoskeletal Ultrasound. St Louis (MO): Mosby Year Book, 1991:91 – 121.
9. Archal GJ, van Holsbeeck MT, Raes M, et al. Transient synovitis of the hip in children: role of US. Radiology. 1987; 162: 825-8.
10. Ralle M, Gonzalez G, Pulpeiro JR, et al. Sonography of the painful hip in children: 500 consecutive cases. AJR. 1989; 152:579 -82.
11. Chhem RK, Beauregard G. Synovial diseases. Clin Diagn Ultrasound. 1995; 30:43 -57.
12. Richardson ML, Selby B, Montana MA, Mack LA. Ultrasonography of the knee. Radiol Clin North Am. 1988; 26: 63-75.
13. Ptasznik R. Musculoskeletal ultrasound: ultrasound in acute and chronic knee injury. Radiol Clin of North Am 1999; 37:797 -830.
14. Eric E. Ward, Jon A. Jacobson, David P. Fessell, Curtis W. Hayes and Marnix van Holsbeeck Sonographic Detection of Baker's Cysts Comparison with MR Imaging **AJR** 2001; 176:373-380

15. David A. Jamadar, Jon A. Jacobson, Sean E. Theisen, David R. Marcantonio, David P. Fessell, Smita V. Patel and Curtis W. Hayes Sonography of the Painful Calf: Differential considerations **AJR** 2002; 179:709-716
16. Rasmussen O.S Sonography of tendons, Scandinavian Journal of Medicine & Science in Sports 2000; 10: 360–364.
17. De Flaviis L, Nessi R, Scaglione P, et al. Ultrasonic diagnosis of Osgood-Schlatter and Sinding-Larsen-Johansson diseases of the knee. *Skeletal Radiol* 1989; 18:193 -197.
18. Bianchi S, Zwass A, Abdelwahab IF, Banderali A. Diagnosis of tears of the quadriceps tendon of the knee: value of sonography. *AJR Am J Roentgenol* 1994; 162:1137–1140
19. Zeiss J, Saddemi SR, Ebraheim NA., MR imaging of the quadriceps tendon: normal layered configuration and its importance in cases of tendon rupture. *AJR Am J Roentgenol* 1992; 159:1031–1034
20. Takebayashi S, Takasawa H, Banzai Y, et al. Sonographic findings in muscle strain injury: clinical and MR imaging correlation. *J Ultrasound Med* 1995;14:899 -905
21. Lee JI, Song IS, Jung YB, Kim YG, Wang CH, Yu H, Kim YS, Kim KS, Pope TL Jr. Medial collateral ligament injuries of the knee: ultrasonographic findings. *J Ultrasound Med.* 1996 Sep; 15(9):621-5.
22. Lantz, B. Singer KM. Meniscal cysts. *Clinics in sports medicine* 9 (3) 1990, 707-725
23. Maffuli N., Petricciuolo F., Pintore E., Lateral meniscal cyst: arthroscopic management. *Med Sci Sports Exerc* 23 (7) 1991, 779-782.
24. Henning CE. Current status of meniscus salvage. *Clin Sports Med* 1990;9:567-576