

## **Successful Treatment of High-Flow Priapism with Radiologic Transcatheter Embolization of The Internal Pudendal Artery: A Case Report**

**A.K. Eziyi<sup>1</sup>, A.M. El-Assmy<sup>2</sup>, T.A. Mohsen<sup>3</sup>.**

<sup>1</sup>Urology Unit, Department of Surgery Ladoke Akintola University of Technology Teaching Hospital (LTH) ,Fagbews Road, PMB 5000, Osogbo, Nigeria,

<sup>2</sup>Department of Urology, Urology and Nephrology Center, Mansoura University, 35516 El-Gomhoria Street, Mansoura, Egypt.

<sup>3</sup>Department of Radiology, Urology and Nephrology Center, Mansoura University, 35516 El-Gomhoria Street, Mansoura, Egypt..

*Correspondence to:* eziyi1@yahoo.com

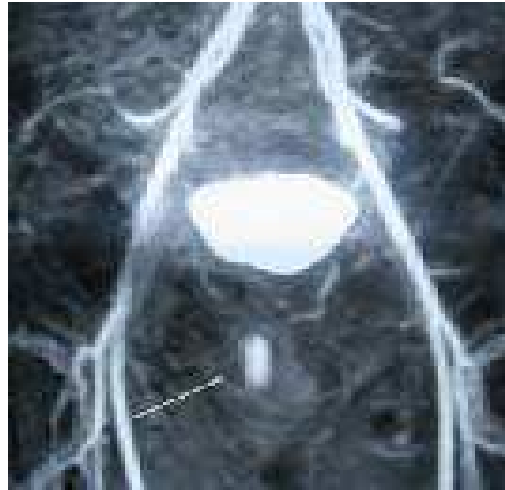**Priapism, a relatively uncommon disorder, is divided into ischemic (veno-occlusive, low flow) painful priapism and nonischemic (arterial, high flow) painless priapism.. We report our successful treatment of arterial priapism by means of radiologic selective transcatheter embolization of the internal pudendal artery using micro coil.**

### **Introduction**

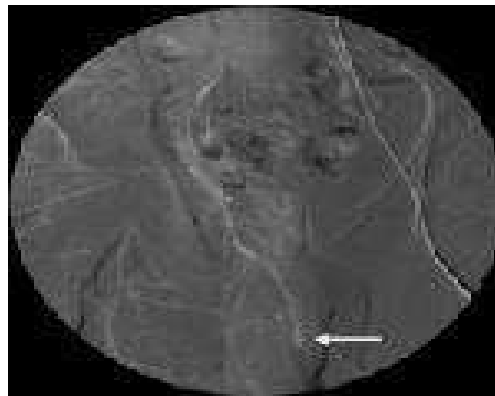
Priapism is a persistent penile erection that continues greater than 4 hours unrelated to sexual stimulation.<sup>1</sup> 'High-flow' priapism (HFP) is a rarely seen clinical entity that results from unregulated arterial inflow to the corpora cavernosa caused by a shunt between the arterial and lacunar system, which overwhelms venous outflow<sup>1</sup>. The reported incidence of post-traumatic HFP is nearly 6% of all prolonged erectile conditions.<sup>2</sup> It usually occurs following perineal or direct penile trauma and leads to painless nonischemic and prolonged erection. It has been reported as a complication of treatment of low-flow priapism(LFP)<sup>3</sup>, and Nesbitt operation<sup>4</sup> but the etiology is unknown in some cases.<sup>5</sup> It is rarely bilateral.<sup>6</sup> Generally there is delay of a few days between the trauma and the onset of priapism, depending on the severity of the arterial lesion<sup>2</sup>. Diagnosis usually involves gasometry of the cavernosal blood, duplex ultrasonography of the corpora cavernosa and angiography.<sup>7</sup> Selective angiography with internal pudendal artery embolization is the most common treatment.<sup>7</sup> We report a 22-year-old man who developed HFP that was successfully treated by means of radiologic selective transcatheter embolization of the internal pudendal artery using micro coil.

### **Case Report**

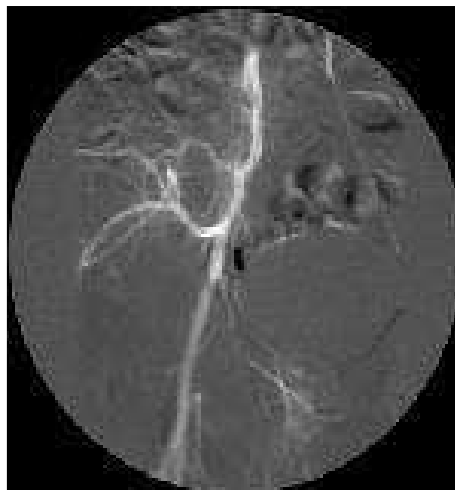
A 22 year man sustained perineal trauma following fall astride 10 days before presentation. No post-traumatic pain, haematuria or dysuria. He did not undergo any treatment for the trauma. Painless sustained penile erection developed 3 days after the trauma. The patient had no risk factors for priapism. On physical examination the corpora cavernosa were fully erect and not tender. He had scrotal haematoma that was not tender with grossly normal testes. Further physical examination was completely normal and normal laboratory tests (blood count, coagulation tests, urinalysis and renal function) were all normal. Cavernosal blood gas analysis yielded a PH of 7.41, PO<sub>2</sub> of 93.4mmHg, PCO<sub>2</sub> of 37mmHg. In the Magnetic Resonance Angiography (MRA) done the right cavernosium shows a cavity-like lesion with filling of contrast during arterial injection (arrows in figure 1). Picture was highly suggestive of post-traumatic cavernosinusoidal fistula. Diagnostic right internal iliac angiography with possible embolization was recommended. Selective Angiography of the right iliac and pudendal arteries via left transfemoral approach showed an evidence of small cavity filled contrast related to the right cavernosal artery with sinusoidal communication (figure 2).



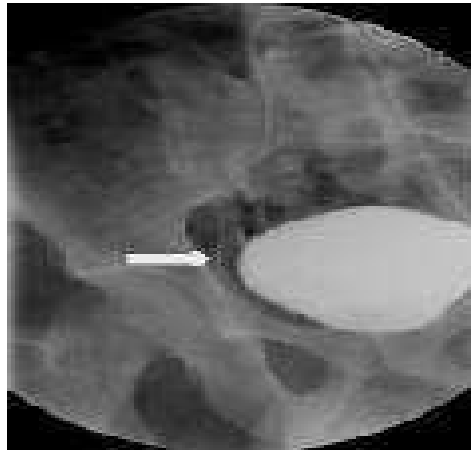
**Figure 1.** MRA: The right corpus cavernosium shows a cavity-like lesion with filling of contrast during arterial injection (arrows). Picture is highly suggestive of post-traumatic cavernosinusoidal fistula.



**Figure 2.** Selective Angiography of the right iliac and pudendal arteries via left transfemoral approach shows: An evidence of small cavity filled contrast related to the right cavernosal artery with sinusoidal communication.



**Figure 3.** Superselctive angiography of the feeding artery by embolization using delivery of the platinum microcoils was done.



**Figure 4.** Post embolization angiography showed complete closure of the lesion with no further filling.

He had selective angioembolization of the right pudendal artery using micro coil. The procedure started with intra-arterial digital subtraction angiography [IA-DSA] of the common iliac artery followed by selective catheterization of the internal iliac artery. The internal pudendal artery (arising from anterior division of internal iliac artery) was embolized using Platinum microcoils of 0.035 inch (Boston Scientific, Boston, MA, USA) and were delivered through the 6 French (F) angiographic catheter (Cobra II, Terumo, Osaka, Japan) [figure 3]. Complete detumescence of the penis occurred within minutes, figure 4. Follow-up after three years revealed no abnormality with good erectile function.

### Discussion

Priapism was first described in Pharaonic papyri.<sup>8</sup> Diminished blood efflux from the cavernous bodies with stasis was the only known pathophysiological mechanism for priapism till 1960 when Butt et al<sup>9</sup> described the first case of HFP. In the last 42 years only 202 cases have been published, most of them as case reports.<sup>10</sup> HFP is caused by increased flow into the corpora cavernosa. The blood from a lacerated cavernosal artery flows directly into the cavernosal sinusoids and bypasses the regulatory helicine arterioles. During episodes of penile nocturnal tumescence the clot that is formed earlier in the injured artery is disturbed and this is the likely reason for the delayed onset of priapism after the traumatic event.<sup>2</sup> The excess arterial inflow is followed by stretching of the corporal sinuses causing penile erection. Because venous inflow is not compromised tissue ischemia does not occur. It has been found that about 70.5% of all reported cases of HLP result from trauma (as in our case report) or iatrogenic laceration of a penile artery<sup>4</sup>. Other causes are idiopathic<sup>5</sup>, Fabry's disease<sup>11</sup>, malignant erosion of the penile arteries, drug abuse and intracavernous injection of Prostaglandin E1. Stuttering priapism changing to HFP in a patient with sickle cell anemia has been reported.<sup>12</sup> HFP can coexist with LFP.<sup>13</sup> HFP occurs in children and adults under 55years of age, and our patient is 22 years.<sup>10</sup>

Usually there is a delay of a few days between the trauma and the onset of priapism as in our patient whose erection started three days following perineal trauma. The classical feature of arterial priapism is a painless erection of the cavernous bodies with the corpus spongiosum remaining flaccid and this was the main clinical finding in our patient. Since transformation from LFP to HFP can occur, it should be considered in the differential diagnosis of patients with LFP in whom treatment fails. Piesis or compression sign, which is perineal compression with a thumb, leads to immediate detumescence in HLP unlike in LFP, was not demonstrated in our patient.<sup>7</sup> Blood gas testing and colour duplex ultrasound are currently the most reliable diagnostic methods of distinguishing LFP from HFP.<sup>1</sup> Blood aspirated from the corpus cavernosum in patients with LFP is hypoxic and therefore dark, while blood from the corpus in

cavernosum in patients with HFP is normally oxygenated and therefore bright red with the blood gases similar to the gases of arterial blood. In our patient gasometry of the blood from the corpora cavernosa were identical with the arterial blood. Colour duplex ultrasonography in patients with LFP have little or no blood flow in the cavernosal arteries while patients with HFP have normal to high blood flow velocities in the cavernosal arteries. It is noninvasive, highly sensitive and specific for detecting arterial-lacunar communication.<sup>1,7</sup>

Penile arteriography in HFP helps to identify the presence, site and size of a cavernosal fistula (rupture helicine artery). In MRA and selective angiography done for our case the right cavernosium shows a cavity-like lesion with filling of contrast during arterial injection (arrows in figures 1 and 2) which was highly suggestive of post-traumatic cavernosinusoidal fistula.

Treatment for HFP varies from watchful waiting<sup>7</sup> to mechanical compression with ice packs<sup>10</sup>; aspiration, intracavernous administration of alpha-adrenergic agents<sup>9</sup>, embolization<sup>4,7,12,14,15</sup> or even open surgery with ligation of the artery concerned<sup>10</sup>. HFP can resolve without treatment and in one case report a patient suffered HFP for 31 years without any subsequent impotence.<sup>15</sup> The disadvantages of watchful waiting are possible structural alterations resulting from excessive arterial inflow which may lead to impotence, as well as social and psychological difficulties related to the condition and should be discouraged.<sup>7</sup> It is possible that persistent high-oxygen tension associated with chronic erection for many years leads to irreversible cavernous tissue damage.<sup>15</sup> Ciampalini et al<sup>5</sup> believe that the option of watchful waiting could be hazardous, because when fibrosis with subsequent impotence occurs it is irreversible. Takao et al<sup>14</sup> advised that if priapism does not resolve after 3 weeks, that highly selective embolization should be considered for it appears difficult for a fistula with clot to close spontaneously after three weeks<sup>1</sup>.

Selective angiography with internal pudendal artery embolization is the most common form of treatment because of the high success rate.<sup>4,7,12,14,15</sup> Absorbable materials autologous blood<sup>7</sup> or gelatine sponge<sup>9</sup> lead to transient occlusion of the cavernous artery for about 1 to 2 days which later recanalizes but has the disadvantage of significant recurrence rate. In case of recurrence use of nonabsorbable materials like coils, particles, microballoons help to avoid recurrence<sup>15</sup>. The advantage of coil, which was used for our patient, is that they can be placed exactly into the branch supplying the arteriocavernosal fistula. Many workers have reported successful treatment of HFP with coil.<sup>7</sup> Microballons usage requires larger diameter catheter. Use of particles has the possible danger of peripheral spread and subsequently unintentional peripheral embolization with necrosis. Superselective angiography of the feeding artery by embolization using delivery of the platinum microcoils was done for our patient (figure 3) and post embolization angiography showed complete closure of the lesion with no further filling (figure 4).

Complications of embolization are rare and include penile gangrene, persistent erectile dysfunction, gluteal ischaemia, purulent cavernositis and perineal abscess. Our patient did not develop any of the complications since on follow-up for two and half years.

We conclude that radiologic selective transcatheter embolization with micro coil is a successful treatment option for high-flow priapism.

## References

1. Montague DK, Jarow J, Broderick GA American Urological Association Guideline on the management of priapism. *J. Urol* 2003; 170:1318-1324
2. Winter CC, McDowell G Experience with 105 patients with priapism. Update review of all aspects. *J Urol* .1998;140: 980–983.

3. Rodriguez J, Cuadrado JM, Frances A High-flow priapism as a complication of veno-occlusive priapism: two case reports. *Int J Impot Res* 2006;18:215-217.
4. Liguori G, Garaffa G, Trombetta C et al. High- flow priapism(HFP) secondary to Nesbit operation: management by percutaneous embolization and colour Doppler-guided compression *Int J Impot Res* 2005 ;17:304-306.
5. Ciampalini S, Savoca G, Buttazzi L et al High-flow priapism: treatment and long-term follow-up. *Urology* 2002;59: 110–113.
6. Lee YC, Shen JT, Shih MC et al Chen CC, Chou YH, Huang CH. Bilateral superselective arterial microcoil embolization in post-traumatic high-flow priapism: a case report. *Kaohsiung J Med SCI* 2003;19: 79–83.
7. Hetzichristou D, Salpiggidis G, Hatzimouratides K et al. Management strategy for arterial priapism: therapeutic dilemmas. *J. Urol* 2002;168:2074-2077.
8. Shokier AA, Hussein MI The urology of Pharaonic Egypt. *BJU Int* 1999;84:755-6.
9. Burt FB, Schirmer HK, Scott WW A new concept in the management of priapism. *J.Urol* 1960;83:60-63.
10. Kuefer R, Bartsch G Jr, Herkommer K et al Kramer SC, Kleinschmidt K, Volkmer BG. Review: Changing diagnostic and therapeutic concepts in high-flow priapism. *Int Res* 2005;17:109-113.
11. Foda MM, Mahmood K, Rasuli P et al. High-flow priapism associated with Fabry's disease in a child: a case report and review of literature. *Urology* 1996;48:949-52.
12. Abdelshafy M, Kamal M, Mo'men A et al. An erectile phenomenon of Stuttering low flow priapism changing into refractory high-flow type in a patient with sickle cell anemia. *AJU* 2007;5:59-62.
13. Ilkay AK, Levine LA Conservative management of high-flow priapism. *Urology* 1995;46:419-24.
14. Takao T, Osuga T, Tsujimura A et al. Successful superselective arterial emolization for post-traumatic high-flow priapism. *Int J Urol* 2007 ;14:254-256.
15. Hakim LS, Kulaksizoglu H, Mulligan R et al. Evolving concepts in the diagnosis and treatment of arterial high flow priapism. *J. Urol* 1996;155:541-8.