

## **Chronic Subdural Haematoma Complicating Spinal Anaesthesia: A Case Report And Review of Literature**

**J.C. Byiringiro<sup>1</sup>, M. Perez<sup>1</sup>, C. Serrano, D.H. Kagabo<sup>2</sup>, T.Twagirumugabe<sup>3</sup>, P. Kyamanywa<sup>1</sup>**

<sup>1</sup>Department of Surgery, Butare University Teaching Hospital – National University of Rwanda P.O. Box 217 Butare, Rwanda, <sup>2</sup>Department of Medicine, King Faisal Hospital, P.O. Box 2534 Kigali, Rwanda, <sup>3</sup>Department of Anaesthesiology and Critical care, Butare University Teaching Hospital – National University of Rwanda P.O. Box 217 Butare, Rwanda

*Correspondence to:* Dr. J.C. Byiringiro, Email: [jcbyiringiro@yahoo.fr](mailto:jcbyiringiro@yahoo.fr).

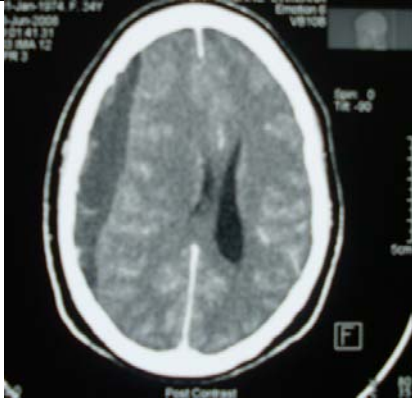
**Subdural haematoma is a rare but serious complication of dural puncture. We report a case of chronic subdural haematoma, which occurred following spinal anaesthesia for elective caesarean section. A 34-year-old multiparous woman presented with a post-dural puncture headache (PDPH) following spinal anaesthesia. The headache was non-responsive to analgesics, bed rest and rehydration. CT-scan was done and showed a large right fronto-parietal subdural hematoma. This was drained successfully with complete recovery. Prolonged and severe post-dural puncture headache may be the only clinical indicator of post-spinal anaesthesia intracranial complications, and should be promptly investigated.**

### **Introduction**

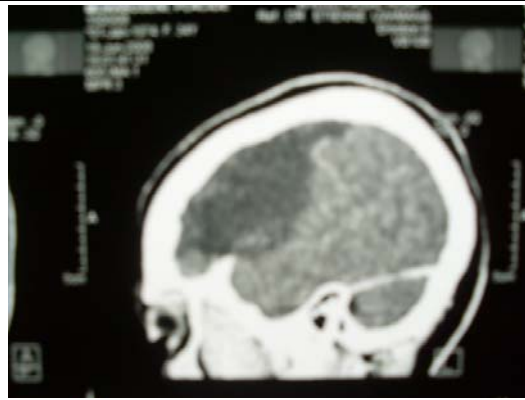The use of spinal anaesthesia especially for obstetric surgery, has been promoted in resource-poor settings. Spinal anaesthesia is also a major component of day case surgery. It is thus important to appreciate some of its common and not so common complications. Headache is a recognized complication of lumbar punctures, especially for spinal anaesthesia. Other complications include back pain, radicular lesions, epidural abscesses and meningitis<sup>1</sup>. Classically, the post-dural-puncture headache (PDPH) is posture dependent, mild and usually responds to increased fluid intake, bed rest and analgesics. Rarely, PDPH may be a result of cranial subdural haematoma formation or intracerebral haemorrhage, which can be fatal if neglected<sup>2-6</sup>. The present report describes a case of intracranial subdural hematoma formation following spinal anaesthesia for caesarean section. Here, we emphasize the importance of suspicion, early diagnosis and appropriate treatment of this serious complication in patients presenting with non-postural PDPH, especially in resource-poor settings where computed tomography (CT) may not be easily available.

### **Case Report**

A 34-years old multiparous woman was admitted to the department of surgery complaining of headache. She had undergone a fifth elective caesarean section under spinal anaesthesia in a district hospital 35 days earlier. The patient's pregnancy had evolved normally, having received the routine prenatal care. The patient had no history of neurological disease, migraine, coagulopathy, or head injury before or after the spinal anaesthesia, she denied the intake of chronic treatment or using tobacco or alcohol. There was neither onset of labour nor attempt of vaginal delivery prior to the admission. The spinal anaesthesia was reportedly achieved without technical difficulties with a 22G Quincke needle and the anaesthetic level was appropriate. Caesarean section was performed without any intra-operative complication. Two days after the procedure, the patient complained of an intense generalized headache with no objective fever or signs of meningeal irritation. A diagnosis of PDPH was made and accordingly, she was given analgesics, oral hydration, and bed-rest. By the fifth day, the patient showed improvement and was discharged home. One week later, the patient was brought back to the same hospital complaining of severe headaches that were not relieved by analgesics and lying down.



**Figure 1**



**Figure 2.**

**Figure 1:** CT scan coronal view of right subdural hematoma with midline shift.

**Figure 2:** Sagittal view: subdural hematoma occupying the fronto-parietal area.

She was readmitted and later transferred to the University Teaching Hospital in Kigali (CHUK) where a cranial computed tomography scan (CT) was done, revealing a large right fronto-parietal subdural haematoma (Figures 1 and 2).

The patient was then transferred to the University Teaching Hospital of Butare (CHUB) for further management. On examination, the patient was afebrile, alert and well orientated in time, place and person. The pupils were equal and normally reacting to light, and no focal signs were noted. Blood profile and chemistry were normal. An emergent trepanation was done and evacuation of the hematoma was performed. The patient's condition steadily improved and she was discharged home on post operative day 6 without headache or fever.

## Discussion

Intracranial subdural hematoma is an exceptionally rare but life-threatening complication of spinal anaesthesia<sup>2-8</sup>. Intracranial haemorrhages after dural punctures have been reported in few reports and most of these are subdural haematomas<sup>12,3,4,6-14</sup>. The true incidence of subdural haematoma formation following lumbar puncture remains obscure, as most of these patients are probably managed without investigation<sup>10</sup>.

Intracranial subdural hematoma formation has been reported after dural puncture with persistent leakage of cerebrospinal fluid (CSF). However, the exact pathophysiological mechanism is not known. One possible explanation is that CSF leakage reduces intraspinal as well as intracranial pressure. The altered CSF dynamics may result in a caudally-directed movement of the spinal cord and brain, which in turn stretches the pain-sensitive structures, dura, cranial nerves and bridging veins<sup>11</sup>. Cerebral veins drain into dural sinuses that are adherent to the inner table of the skull. Electron microscopic studies have shown that the bridging veins are more fragile in the subdural space than in the subarachnoid space<sup>15</sup>. It is presumed that CSF leakage via a dural fistula created may cause a caudal displacement of the brain, which in turn pulls and tears the bridging vessels, resulting in a subdural haemorrhage and haematoma formation.

Dehydration may further increase the risk of imbalance between CSF loss and production<sup>11</sup>. Dehydration-induced reduction of brain volume could also lead to subdural haemorrhage. Low intracranial pressure, as a result of peri-operative dehydration, promotes excessive blood congestion in the bridging veins with consequent dilatation and increasing tension of the vessels, which are further stretched by a downward displacement of the brain, and consequently more vulnerable to rupture with the intracranial movement of the brain within its coverings<sup>11</sup>. Within a

week of its formation, the hematoma is covered by an outer membrane beneath the dura, and by 3 weeks an inner membrane forms between the haematoma and the arachnoid. The subdural haematoma enlarges because the capsule acts as an osmotic membrane, facilitating the diffusion of more water into the haematoma<sup>10</sup>. The flow across the membrane, as cited by Acharya, occurs as a result of an increase in osmotic pressure from a breakdown of haemoglobin molecules<sup>10</sup>.

Cerebral atrophy increases the risk of rupture of bridging veins especially when associated with low CSF pressure, but it is very common in old patients<sup>9</sup>. Our patient was not too old (34 years) and there were no signs of brain atrophy on the CT scan. In addition, many authors believe that pregnancy increases the risk of stroke<sup>16</sup>. The bridging veins may rupture after a sudden increased pressure during labour and delivery<sup>15</sup>, due to venous congestion during pregnancy. A pre-existing aneurysm may also rupture by the same mechanism. But for the case reported here, there was neither onset of labour nor attempt of vaginal delivery prior to the admission.

PDPH is more frequent when Quincke spinal needles of large sizes are used (20 to 22 gauges, 20% to 40% incidence; 24 to 27 gauges, 5% to 12% incidence)<sup>17</sup>. Lower incidences of PDPH of up to 5% have been reported with the use of Whitacre and Sprotte spinal needles. The high cost of these needles compared to the Quincke needle however, makes them unaffordable for many centers<sup>17</sup>. The patient in this study received spinal anaesthesia by a 22G Quincke needle which is a relatively big needle. Though, subdural hematoma<sup>2</sup> and intracerebral haemorrhage<sup>5</sup> have been reported even with very small spinal needles<sup>6,10,12-13</sup>. The incidence of SDH following spinal anaesthesia has been minimized with the use of 29G needles<sup>18</sup>. Evans<sup>17</sup> reports that when using a Quincke needle, bevel insertion parallel to the longitudinal dural fibres reduces the risk of headache by 50% compared with perpendicular insertion. The diagnosis is complicated by the fact that the symptoms are similar to those of a PDPH, which in the puerperium has several differential diagnoses, including pregnancy-induced hypertension, meningitis, migraine, brain tumours, subarachnoid haemorrhage, subdural hematoma, cerebral venous thrombosis, or non specific causes<sup>19</sup>. Over time, features of persistent PDPH change and/or reappear later and may be accompanied with new neurological symptoms.

It is essential to establish a differential diagnosis as early as possible to rule out other possible causes to prevent serious and life-threatening complications such as the subdural hematoma. Subdural haematomas complicating lumbar puncture may resolve spontaneously or with conservative measures but can be catastrophic, as evident from some of the reported deaths<sup>2,12,14</sup>. In the recent literature review, 20 of 25 cases of subdural hematoma after spinal anaesthesia were managed surgically [9], but for most of these cases, the diagnosis was made when the patients presented focal signs; at this time, surgical management is the only possible solution while epidural blood patch (EPB) could be an alternative if the diagnosis was done early by loss of the postural character of headaches [9]. According to Berkel some of PDPH improving under routine EPB could possibly be unrecognized subdural haematomas [13]. In the case described here, the haematoma was large enough to warrant an emergency surgical decompression and recovery was complete.

## Conclusion

Severe and progressive headache following spinal anaesthesia should be regarded as a warning sign of an intracranial complication. Early neurosurgical consultation in these patients is recommended to facilitate early diagnosis and prompt intervention so as to minimize morbidity and mortality. A high level of clinical suspicion and early radiological evaluation are necessary for improved outcome. The anaesthesiologists should inform the clinicians of this rare but catastrophic complication of spinal anaesthesia. The use of smaller spinal needles should be encouraged to minimize the incidence of PDPH and SDH.

### Acknowledgements:

Our thanks are addressed to Dr. P. Karumugabo MD for providing vital information about the patient.

### References

1. Alilou M, Halefadi S, Caidi A, Kabbaj S, Ismaili H, Maazouzi W. Une nouvelle observation d'hématome sous-dural chronique intracrânien au décours d'une rachianesthésie. *Ann Fr Anesth Reanim* 2003; 22:560–1
2. Acharya R, Chhabra SS, Ratra M, Sehgal AD. Cranial subdural hematoma following spinal anaesthesia – A case report with review of the literature. *Br J Anaesth* 2001; 86:893–895
3. Vaughan DJA, Stirrup CA, Robinson PN. Cranial subdural haematoma associated with dural puncture in labour. *Br J Anaesth* 2000; 84:518–520
4. Velarde CA, Zuniga RE, Leon RF et al. Cranial nerve palsy and intracranial subdural hematoma following implantation of intrathecal drug delivery device. *Regional Anaesth Pain Med* 2000; 25:76–78
5. Mantia AM. Clinical report of the occurrence of an intracerebral hemorrhage following post-lumbar puncture headache. *Anesthesiology* 1981; 55:684–685
6. Cantais E, Behnamou D, Petit D, Palmier B. Acute subdural hematoma following spinal anaesthesia with a very small spinal needle. *Anesthesiology* 2000; 93:1354-6.
7. Blanloeil Y, Chabbert C, Lehot JJ. Hématome sous-dural lors d'hypotension intracrânienne : une complication à connaître, reconnaître, prévenir et traiter. *Ann Fr Anesth Reanim* 2003;22:275–7.
8. Dardik A, Perler BA, Roseborough GS, Williams GM. Subdural hematoma after thoracoabdominal aortic aneurysm repair: an underreported complication of spinal fluid drainage? *J Vasc Surg* 2002;36:47–50
9. Zeidan A, Farhat O, Maaliki H, Baraka A. Does postdural puncture headache left untreated lead to subdural hematoma? Case report and review of the literature. *Int J Obstet Anesth* 2006;15:50–8.
10. Acharya R. Chronic subdural haematoma complicating spinal anaesthesia. *Neurol Sci* 2005; 25:348–350.
11. Lu C H, Ho S T, Kong S S, Cherng C H, Wong C S. Intracranial subdural haematoma after unintended durotomy during spine surgery. *Can J Anaesth* 2002; 49: 100–102.
12. Tafer N, Perrier V, Racioppi L, Biaisi M, Quinart A, Revel P, Sztark F. Hématome sous-dural aigu intracrânien après rachianesthésie traité par blood patch. *Ann Fr Anesth Reanim* 2008; 27: 160–162.
13. Berkel Y G, Colakoglu S, Atakan T Y, Büyükkirli H. Intracranial subdural hematoma after spinal anesthesia. *Int J Obst Anesth* 2005; 14: 159–162.
14. Blake DW, Donnan G, Jensen D. Intracranial subdural haematoma after spinal anaesthesia. *Anaesth Intens Care* 1987;15:341–342
15. Yamashita T, Friede RL. Why do bridging veins rupture into the virtual subdural space? *J Neurol Neurosurg Psychiatry* 1984; 47: 121–7.
16. Sharshar T, Lamy C, Mas J L. Incidence and causes of strokes associated with pregnancy and puerperium. *Stroke* 1995; 26: 930–936.
17. Evans R. W. Special Report: Complications of Lumbar Puncture and their prevention with atraumatic lumbar puncture needles. *Neurol* 2000;55:909–914
18. Flaaten H, Rodt SA, Vamnes J et al. Post-dural puncture headaches: a comparison between 26 and 29 G needles in young patients. *Anaesthesia* 1989; 44:147–149
19. Stocks GM, Wooller DJA, Young JM, Fernando R. Postpartum headache after epidural blood patch: investigation and diagnosis. *Br J Anaesth* 2000; 84: 407-10