

**Omental Torsion Mimicking Acute Appendicitis: A Case Report.**

Ntakiyiruta Georges.

Kibogora Hospital, RWANDA Email: [georgentakiyiruta@yahoo.co.uk](mailto:georgentakiyiruta@yahoo.co.uk)

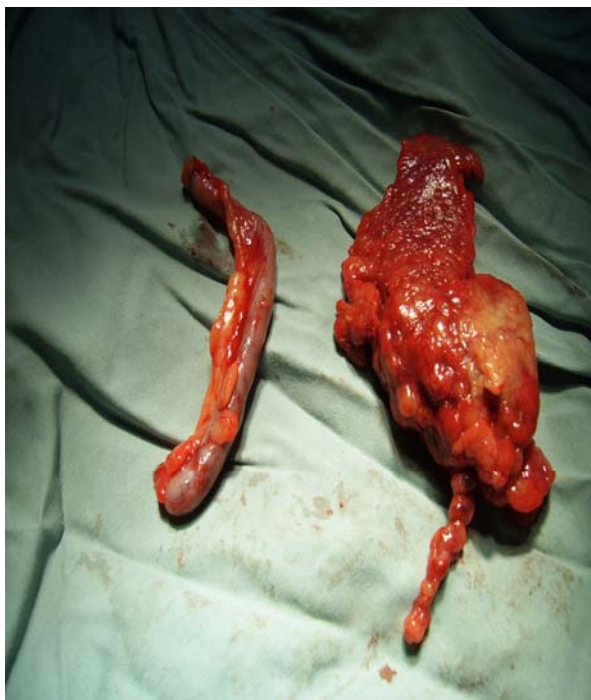
**This review discusses a 38 year old patient with all the signs and symptoms of acute appendicitis. At surgery a normal appendix and serosanguinous fluid were observed. Further routine exploration disclosed a twisted omentum. This segment was excised. Patient recovered quickly. There is a need for exploration of the abdomen when preoperatively diagnosed acute appendicitis is not found.**

**Case Report**

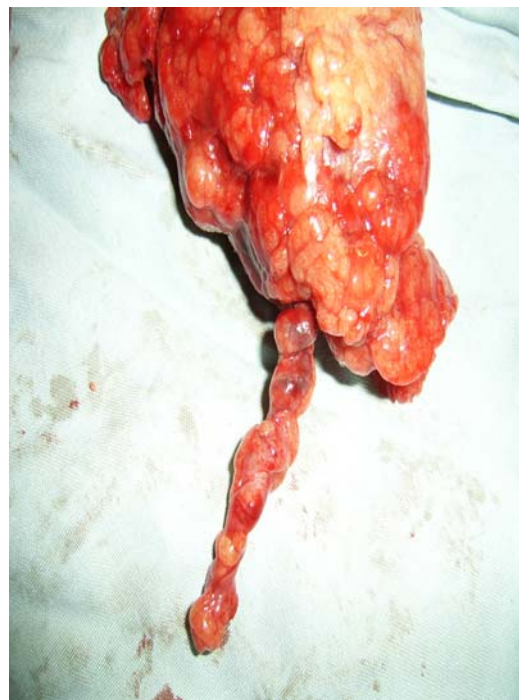
A 38 year old male presented to the emergency unit of Kibogora mission hospital with a 3days history of right lower quadrant abdominal pain, nausea, low grade fever and malaise. On examination, he was a healthy rather overweight man and mildly febrile (37.5°C). Per abdomen, there was RLQ tenderness with rebound tenderness. He had positive Mac Burney point and a positive Rovsing's sign. Digital rectal examination elicited tenderness in the pouch of Douglas.

His WBC was 8,650/mm<sup>3</sup>. Abdominal ultrasound was not done. A diagnosis of

Appendicitis was made and the patient prepared for surgery. A transverse muscle splitting Lanz incision was made. At operation a normal appendix was found. At further exploration, a thickened structure was palpated in the RIF and there was some serosanguinous fluid. This was exteriorized. It was a thickened, congested segment of omentum. It has twisted several times on its pedicle. The twisted omentum was easily ligated and excised. Appendectomy was also performed in the usual way (Figs 1&2). Postoperative period was uneventful and rapid. Patient was discharged on the 3<sup>rd</sup> postoperative day.



**Figure 1**



**Figure 2.**

## Discussion

Omental torsion is a condition in which a segment of the organ twists on its long axis. Blood supply to the twisted segment is compromised. Omental infarction will result if torsion is not relieved. Omental torsion is not very common<sup>1,2</sup>. Less than 400 cases have been reported. Omental torsion is commonly misdiagnosed preoperatively as acute appendicitis<sup>2,4</sup>. The precise aetiology of primary omental torsion is not clear. There are however some predisposing factors including anatomical variations and irregular distributions of omental fat especially in obese patients. Sudden postural change, large meals, violent exercise, hyperperistalsis, vibration and abdominal trauma have been advocated as precipitating factors<sup>1,2</sup>.

When the omentum twists around a pivotal point, venous return is initially compromised in the distal segment. This becomes congested and edematous with extravasation of a serosanguinous fluid in the peritoneal cavity. Arterial occlusion will follow resulting in omental infarction and necrosis. Omental torsion usually presents as a localized acute abdominal pain. Nausea and fever are frequent. Omental torsion can mimic the common causes of acute surgical abdomen<sup>2</sup>. Some cases have presented as acute cholecystitis, acute appendicitis and twisted ovarian cysts<sup>2,4</sup>.

Preoperative diagnosis is difficult and most of the diagnoses are made at surgery. Investigations are seldom performed preoperatively because the diagnosis of acute appendicitis is so obvious<sup>2</sup>.

At laparotomy, the finding of free serosanguinous fluid and normal appendix should alert the surgeon to the possibility of torsion of omentum or other epiploic appendage<sup>2</sup>.

Acute appendicitis is reportedly the commonest emergency abdominal operation in different regions. However when a surgeon is faced with clinical features of this very common surgical problem, whenever possible further investigation is needed to rule out conditions like omental torsion because conservative management is also an option and probably much safer in such cases. But when those investigations are not available and a preoperatively diagnosed acute appendicitis is not found at laparotomy, active search for the cause is needed. Some patients may be labeled negative appendectomy when they actually have primary omental torsion.

## References

1. Wen-Chan Yeow, Mohan V Jayasundera, Graham Hool and Rajalingam Sinniah. Acute abdomen due to omental torsion. *MJA* 2005; 183(4):212
2. Tarek M. Al-Jaberi, Kamal I. Gharaibeh, Rami J. Yaghan. Torsion of abdominal appendages presenting with acute abdominal pain. *Ann Saudi Med* 2000; 20(3-4): 211 - 213
3. Ibtisam Al-Bader, Ali Al-Said Ali, Khalid Al-Sharraf, Abdulla Behbehani. Primary omental torsion: Two case reports. *Medical Principles and Practice* 2007;16:158-160
4. Kimber CP, Westmore P, Hutson JM, Kelly JH. Primary omental torsion in children. *J Paediatr Child Health* 1996;32:22-4