

Incarcerated fallopian tube presenting in an incisional hernia : a case report

S Allopi MBChB (Natal),

B Singh FCS (SA),

J Moodley FCS (SA)

University of Natal, Durban, South Africa

Key words: Incisional hernia, incarcerated fallopian tube

Incisional herniation rarely follows a Pfannenstiel incision. A patient with an incarcerated fallopian tube complicating an incisional hernia, which was associated with a Pfannenstiel incision, is presented and discussed. Mechanisms responsible for this type of incisional hernia are outlined.

Even though the use of mass closure has significantly decreased the rate of burst abdomen following laparotomy to less than 1%, incisional hernias are still commonly encountered in general surgical practice¹. The contents of the hernia are usually small bowel and, less commonly, large bowel. Herniation of pelvic and solid abdominal viscera is extremely rare. To date, herniation of the fallopian tubes has not been reported. In this report, we present an incarcerated fallopian tube in an incisional hernia following a Pfannenstiel incision.

Case report

A 35-year-old patient presented to the surgical outpatient department with long-standing pain along the lateral aspect of a Pfannenstiel incision. This followed a caesarean section performed eight years previously at another institution. It was her second pregnancy. Details of the operation were unknown but she recalled the postoperative course as being uneventful. Her first pregnancy was successfully completed as a normal vaginal delivery.

The presenting pain was constant and localised and there were no associated gastro-intestinal symptoms.

The patient had no medical ailments of note, apart from secondary infertility following the second pregnancy. This had not been investigated.

Examination revealed an otherwise fit patient with a tender thickening along the right lateral aspect of the Pfannenstiel scar. There was no cough impulse. Because of these findings and her symptoms, she underwent surgical exploration of this area.

At surgery an ovoid cystic structure was noted. On inadvertent disruption of this, a tubular structure was encountered (Fig 1). This was traced back to a defect in the sheath and had the configuration of a fallopian tube. Further dissection revealed the right ovary and broad ligament which readily herniated via the defect. The new freed fallopian tube and

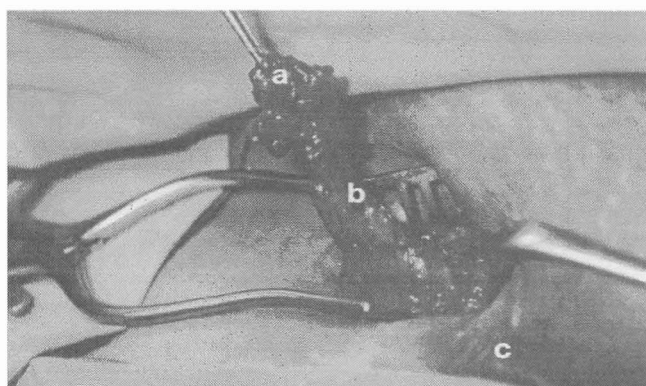


FIG 1 Operative findings depicting herniated ovary (a), fallopian tube (b) via defect in sheath (arrowed) along lateral aspect of the Pfannenstiel incision (c).

ovary were noted to be normal and, upon gynaecological advice, were returned to the pelvis. The incisional defect was repaired with a non-absorbable suture.

In the immediate postoperative period and three months subsequently, the patient was noted to be free of symptoms. Her secondary infertility is currently being investigated.

Discussion

Incisional hernias are a relatively common complication following abdominal surgery, the reported incidence varying between 2% and 11%^{2,3}. However, the incidence of incisional hernias following transverse incisions like the Pfannenstiel incision is much lower at up to 0.5%^{3,4,5,6}. The reason for this is that the skin, subcutaneous tissue and fascial defect are remote from the muscle defect which is covered by healthy non-incised tissue. Furthermore, the relatively avascular linea alba onto which the strong abdominal muscles insert, is not incised thereby minimising the risk of herniation from straining these muscles. The disposition of the scar facilitates healing. It runs along Langer's lines and is parallel to the fibres of the external oblique muscle allowing splitting of these muscles as opposed to a vertical incision. Venous and lymphatic disruption are negligible with this incision which promotes good wound healing.

In the patient discussed, the herniation may have been provoked by the inadvertent coaption of the right fallopian tube during the reapproximation of the wound thereby obviating approximation of the sheath or, less likely, failure to approximate the lateral edge of the sheath.

An under appreciated sequel of the Pfannenstiel incision is a sharp, activity-induced pain along the

scar or deeper in the abdominal wall. This is usually due to entrapment of the ilioinguinal or iliohypogastric nerve, or both³. Nerve entrapment may follow transection of the nerve with subsequent neuroma formation, its incorporation by suture or its tethering by scar tissue. The rarity of incisional hernias complicating this incision, and the potential of nerve entrapment, which is more likely, provokes a diagnostic dilemma to the attending physician. Failure to achieve symptomatic control with conservative measures warrants surgical exploration to attempt correction of the anatomic disruption.

The Pfannenstiel incision has the appeal of an excellent cosmetic result and an extremely low hernia rate. Nevertheless, attention to technical detail is mandatory given the complications of incisional hernias and the high recurrence rate following the first incisional hernia repair⁴. Appreciation of the related nerves is essential since it is more likely that entrapment of these will complicate a Pfannenstiel incision rather than the development of an incisional hernia.

References

- 1 Ellis H, Gajraj H, George CD. Incisional hernias: when do they occur? *Br J Surg* 1983; 70:290-291.
- 2 Santora TA, Roslyn JJ. Incisional hernia. *Surg Clin North Am* 1993; 73:557-570.
- 3 Luijendijk RW, Jeekel J, Storm RK et al. The low transverse Pfannenstiel incision and the presence of incisional hernia and nerve entrapment. *Ann Surg* 1997; 225:365-369.
- 4 Luijendijk RW, Lamén MHM, Hop WCJ, Wereldsma JCJ. Incisional hernia recurrence following "vest over pants" or vertical repair of primary hernias of the midline. *World J Surg* 1997; 21:62-66.
- 5 Tollefson DG, Russel KP. The transverse incision in pelvic surgery. *Am J Obstet Gynecol* 1954; 68:41-42.
- 6 Daversa B, Landers D. Physiological advantages of the transverse incision in gynaecology. *Obstet Gynecol* 1961; 17:305-310.