

Current indications for open Kuntscher nailing of femoral shaft fractures

A S Bajwa FCS(SA)ORTH

E Schnaid FCS(SA)ORTH

M E B Sweet MD PhD(med)

University of Witwatersrand, Johannesburg, South Africa

Key Words: Kuntscher nail, intramedullary nail, femoral fracture

We retrospectively reviewed 32 patients with fractures of the femoral shaft treated with open Kuntscher nailing. All fractures were simple transverse, short oblique or Winquist-Hensen type I and II comminuted diaphyseal fractures. Average operating time was 45 minutes (35 to 55 minutes). Patients were discharged from the hospital within 7 days of surgery. All fractures healed within 12-14 weeks and the union rate was 100%. One patient developed superficial wound infection. Two nails were too long proximally and two nails protruded into the knee joints. There were no rotational deformities nor shortening. One patient had limited knee flexion (less than 60°) and one fracture united in 8° varus. We concluded that open Kuntscher nailing is still indicated in the following situations: in hospitals with no traction table and image intensifier, in obese patients, in Grade I and II compound fractures, in polytrauma patients, in irreducible fractures and in patients with vascular injuries.

Introduction

Since the advent of closed interlocking nailing of the femur^{5,6}, open Kuntscher nailing² is no longer the common method of fixation of the femoral shaft. We have done a retrospective study on 32 patients treated by open Kuntscher nailing at Natalspruit Hospital, Johannesburg. We specifically documented complications such as infection, shortening, rotation, non-union and wound healing.

The aim of our study was to review the indications of open Kuntscher nailing in patients with femoral shaft fracture.

Patients and methods

We studied 32 patients with femoral shaft fracture treated with open Kuntscher nailing at Natalspruit Hospital, Johannesburg, between January 1994 and December 1994. There were 21 males and 11 females, four of whom were pregnant. The average age was 27 years (range 14 to 45 years). The right femur was fractured in 13 and the left in 19 patients. All fractures were simple transverse, short oblique and Grade I and II comminuted diaphyseal fractures³. There were 28 closed and four open fractures. Three patients had polytrauma, one of whom had a fractured femur and a grade IIIc open tibia-fibula fracture, which required above knee amputation primarily.

Technique

Patients were positioned in the lateral decubitus position on a standard operating table. A lateral skin incision was made and the fascia lata incised in the line of the skin incision. Vastus lateralis was retracted bluntly anteriorly from the intermuscular septum to avoid excessive bleeding. Fracture fragments were exposed and cleaned with minimum periosteal stripping. The nail length was measured with a guide wire passed through the canal of both fragments. The canal was reamed and an appropriate sized Kuntscher nail was inserted retrograde through the proximal fragment.

The fracture was then anatomically reduced under direct vision and the nail inserted into the distal fragment by punching. Rotation was corrected using the linea aspera as a marker. The nail was left protruding 2cm proximal to the greater trochanter to facilitate its later removal. The wound was closed routinely over a suction drain. The knee was passively manipulated through a full range of movements and the knee stability was recorded. No traction was used. The average operating time was 45 minutes (range from 35 to 55 minutes). Antibiotics were given for 24 hours and patients were mobilized non weight bearing on day three. The average postoperative hospital stay was seven days.

Results

All the wounds healed within ten days, except one in which cellulitis persisted for two weeks. There was no deep wound infection. All fractures healed in 10 to 12 weeks (Figs 1 & 2). Two nails were too long proximally and two nails protruded into the knee joint. There was no rotatory deformity or shortening. One fracture united in 8° varus which was clinically insignificant. No fat embolism occurred and no nails fractured.

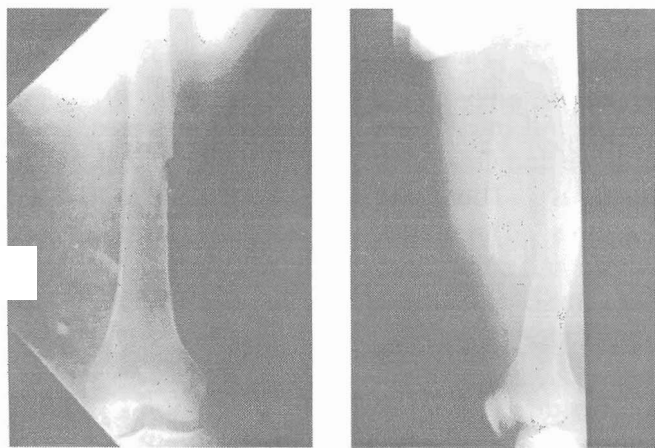


FIG 1 Radiographs of 30-year-old patient with transverse fracture of the shaft of the left femur; (a) anterior-posterior; (b) lateral views.

Discussion

When Gerhard Kuntscher introduced the nail in 1940, it was considered revolutionary in the management of femoral fracture. Open Kuntscher nailing of femoral fractures is no longer common in South Africa where closed interlocking nailing is considered the treatment of choice. Infection and non-union in the literature is reported to occur in between 1.5% and 10% of cases^{8,12}. In our series, the infection rate was 1.5%. This was superficial

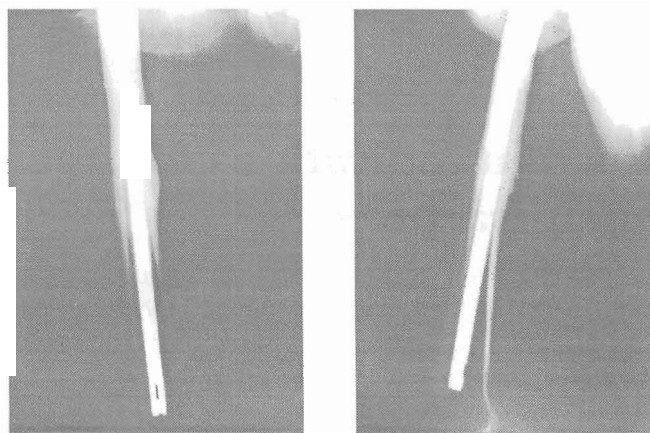


FIG 2 Same patient (as in Fig 1) radiographs 3 months after operation showing sound union of the fracture in good position, (a) anterior-posterior, (b) lateral views.

and caused delayed wound healing. It had possibly spread from the contralateral stump after above knee amputation. All the fractures united. There was no rotatory deformity as patients were not permitted to weight bear before fracture healing. Interdigitation of the fragments, the clover leaf shaped configuration of the nail, and secure fixation in the cancellous distal femur, prevent further rotation^{2,11}. In one patient, the fracture united in 8° varus (Fig 3). In this patient, the fracture was in the distal third of femur and the nail was too small. The nail did not fill the canal under compression, providing no stability. Nevertheless the varus position was clinically insignificant. There was no shortening of the leg.

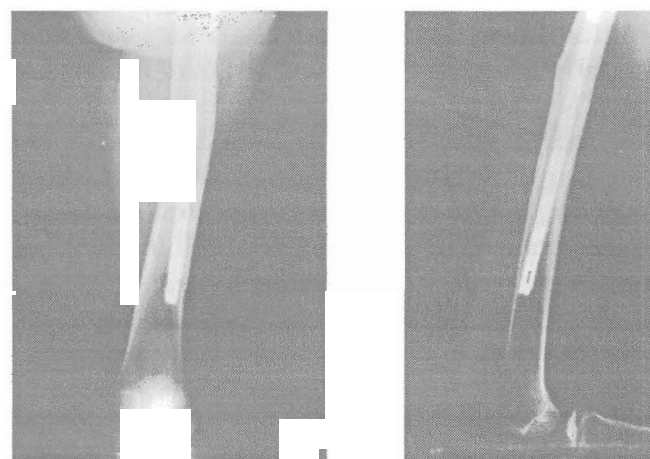


FIG 3 Radiographs of the femur of a 25-year-old patient show fracture healed in varus, (a) anterior-posterior, (b) lateral views.

This procedure was found especially useful in the following patients:

- 1 pregnant females, no screening is required, operative procedure is short, there is minimal

anaesthetic toxicity to the liver or foetus, children more than 11 years old. Damage to the trochanteric apophysis can be avoided¹³, in Grade I and II compound fractures of the femur if it is a low velocity injury and there is minimum or moderate contamination.

Although in our series all open fractures were subjected to delayed nailing following initial debridement, we agree with Chapman and Williams et al that these fractures can be fixed by primarily nailing without any increased morbidity^{5,6},

obese patients (Fig 4). These patients are very heavy around the hips and the diameter of the thigh decreases near the middle and distal thirds of the thigh. Inserting closed interlocking nails in these fractures requires much longer operating time and greater blood loss,

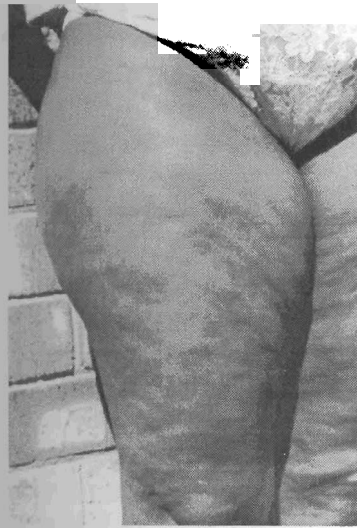

FIG 4

Illustrates that in obese patients, the diameter of the thigh decreases sharply at the middle of the thigh.

in polytrauma patients because the procedure is short and permits early rehabilitation, simple transverse, short oblique and Winquest-Henson Grade I and II comminuted fractures where shortening and rotational deformity is less likely³, and fractures with displaced fragments and soft tissue entrapments, such as the quadriceps muscle, which usually require open reduction⁸.

Although the surgical technique is no different from that described in the literature, special attention must be paid to blunt dissection. Complications such as infection and non-union can be controlled by minimal stripping of the periosteum of the fragments. Reaming of the distal 5cm of the femur should not

be performed, as this may lead to loosening of the nail and allow rotational instability. The length of the distal fragment should be measured over the thigh, up to the proximal pole of the patella to avoid penetration of the nail into the knee joint.

Conclusion

We believe that open Kuntscher nailing is still indicated in hospitals where a traction table or image intensifier is not available and in polytrauma patients who require early stabilization. Special indications are the pregnant female, in whom exposure of foetus to radiation can be avoided, obese patients and irreducible fractures. However, this procedure is not recommended for very comminuted fractures or when the fracture is in the distal third of the femur. Special attention to surgical technique minimizes excessive blood loss and rotational problems.

References

- 1 Sage FP. The second decade of experience with the Kuntscher medullary nail in the femur. *Clinic Orthop* 1968; 60:77-85.
- 2 Schatzker J. Open intramedullary nailing of the femur *Orthop Clinics* 1980; 11:623-631.
- 3 Hensen RAW Jr. Comminuted fractures of the femoral shaft treated by intramedullary nailing *Orthop Clinics* 1980; 11:633-646.
- 4 Browner BD. Pitfalls, errors and complications in the use of Kuntscher nails *Clinical Orthop* 1986; 212:192-208.
- 5 Chapman MW. The role of intramedullary fixation in open fractures *Clinical Orthop* 1986; 12:27-33.
- 6 Williams MM, Askins V, Hinkes EW. Primary reamed intramedullary nailing of open femoral shaft fractures *Clinical Orthop* 1995; 318: 182-190.
- 7 Wroblewesky BM, Browne AO, Hodgkinson JP. Treatment of fracture of the shaft of the femur in total hip arthroplasty by combination of Kuntscher nail and modified cemented Charnley stem. *Injury* 1992; 23:225-227.
- 8 Mahaisavari B, Songcharoen P. Soft tissue interposition in femoral fractures *J Bone Joint Surg* 1995; 77B:788-790.
- 9 Kuntscher G. The intramedullary nailing of fractures *Clinical Orthop* 1968; 60:5-12.
- 10 Taylor JC. Fractures of the lower extremity. In *Campbell's Operative Orthopaedics*, 8th edition, p 878. Ed. Crenshaw AH, 1992, St Louis, Mosby Books.
- 11 Bankston AB, et al. The biomechanical evaluation of intramedullary nails in distal femoral shaft fractures *CORR* No 276, March 1992.
- 12 Christensen NO. Technique, errors and safeguards in modern Kuntscher nailing. *CORR* No 15, March-April 1976.
- 13 Blackburn Z, Rang M. Femoral intramedullary nailing in the growing child. *J Trauma* 1984; 4:432-434.