

Bennett's fracture: a direct volar surgical approach

L N Gakuu MMed

Senior Lecturer

Department of Orthopaedic Surgery
University of Nairobi

S M Kanyi MMed

Lecturer

Department of Anatomy
Chiromo Campus
University of Nairobi

From cadaver dissections of the recurrent motor branch of the median nerve, we determined the exact relationship of its terminal branches at the base of the thumb. This enabled us to surgically approach the first carpometacarpal joint directly on the volar aspect for management of Bennett's fractures in 18 consecutive patients.

As compared with the different surgical approaches advocated and commonly used, the direct volar approach affords clear direct exposure of the intra-articular fracture at the base of the thumb so aiding appropriate reduction and fixation of the fracture. The proposed approach is safe and requires minimal dissection or soft tissue resection. The results were excellent and no case of nerve injury was encountered.

Introduction

A variety of fractures and dislocations occur at the base of the first metacarpal. The extra-articular fractures are usually transverse or short oblique across the base of metacarpal and are generally stable and easily treated conservatively by plaster splintage. The fracture described by Edward Hallaran Bennett in 1882, however, is an unstable oblique fracture entering the carpometacarpal joint at about the middle of the articular surface¹. There is a tendency for the large distal fragment to be displaced backwards and upwards upon the small

proximal fragment due to traction of the abductor pollicis longus muscle^{2,3}. The small fragment is thus left along the palmar aspect.

Bennett, in 1886, advocated closed reduction and splintage with plaster for four weeks⁴(Fig 1).

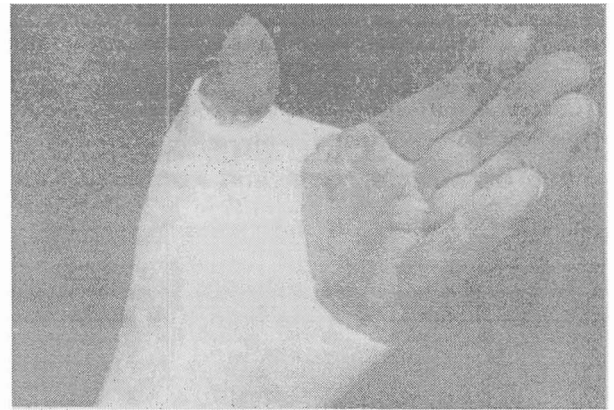

FIG 1 Plaster cast splintage for Bennet's fracture

Many methods of closed reduction and stabilisation have been suggested but found unsatisfactory due to resultant joint incongruity which leads to post-traumatic osteoarthritis^{5,6,7,8,9,10} (Fig 2). The aim of treatment should be exact reduction and restoration of the articular surface. There are various recommended methods of achieving proper anatomic reduction. Closed reduction and plaster was advocated by Bennett⁴ and Oosterboos⁶ and closed reduction and percutaneous pinning by Kahler¹¹. Open reduction and K-wiring^{12,13} or open reduction and miniaturised osteosynthesis using A-O instrumentation or external fixation^{14,15,16,17,3} have their advocates. Recently, Herbert Screw fixation has been used by Hruska¹⁸ and Chabon¹⁹.

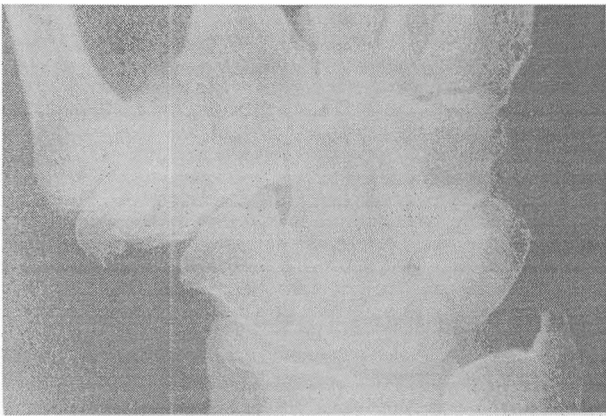


FIG 2 Severe post traumatic osteoarthritis in a patient whose articular surface congruency was not restored by conservative treatment

The recommended surgical approach was dorsal until 1950 when Wagner²⁰ modified the dorsal incision by extending it anteriorly at the level of the wrist crease thereby exposing the first carpometacarpal joint by mobilising the thenar muscles. Later, in 1953, Gedda and Moberg described a new skin incision made at the base of the thenar eminence without posterior extension⁸, whereby the first carpometacarpal joint is exposed by resecting and reflecting the thenar muscles distally. These incisions do not offer direct access to the anteriorly placed small proximal fragment and the extensive dissection of thenar muscles goes against the principle of preservation of the blood supply of the bone fragments and soft tissues, which is needed for proper healing²¹.

The main reason for the incisions described is to avoid injury to the recurrent branch of the median nerve. We, therefore, decided to familiarise ourselves with the nerve supply of the thenar muscles with special reference to the recurrent motor branch of the median nerve.

Materials and methods

We performed 15 cadaver dissections of the forearm, wrist and hand at the Department of Human Anatomy, Chiromo Campus, University of Nairobi. The median nerve was identified and exposed by dividing the superficial flexor muscles and brachioradialis. The median nerve was found entering the forearm from the cubital fossa between the two heads of pronator teres. It crosses anterior to the ulna artery and descends between the superficial and deep flexors. At the wrist the median

nerve is remarkably superficial lying medial to the tendon of the flexor carpi radialis and just deep to the palmaris longus tendon. The median nerve then passes through the carpal tunnel into the hand where it divides into the terminal branches. The thenar muscles are supplied by the motor recurrent branch of the median nerve which we found reaching the flexor pollicis brevis at the junction of proximal and middle thirds of the muscle. On entering the flexor pollicis brevis, the nerve divides into three branches one to the muscle (which spreads along the muscle), a second branch to the opponens pollicis (going deep to the muscle), and a third branch to the abductor pollicis brevis (Fig 3). The findings were consistent in all the dissections.




FIG 3 Muscles of the thenar eminence exposed by removal of the palmar fascia. Abductor pollicis brevis is superficial to flexor brevis and opponens pollicis. The recurrent branch of the median nerve is seen entering the thenar muscles

Based on these findings, 18 consecutive patients with Bennet's fractures were operated on via a direct volar approach with the incision based on the first carpometacarpal joint (Fig 4).

OPERATIVE TECHNIQUE

A skin incision is made 2cm radial and parallel to the thenar crease over the first carpometacarpal joint (Fig 4). The subcutaneous tissues are dissected to

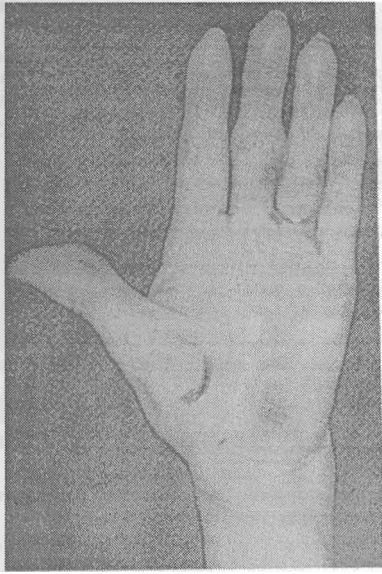


FIG 4 The surgical incision lies directly over the volar aspect of the first metacarpophalangeal joint

expose the palmar fascia thereby exposing the muscles of the thenar eminence, mainly the abductor pollicis brevis. The thenar muscles are split longitudinally along the direction of their fibres by blunt dissection thereby exposing the first carpometacarpal joint which is easily identified due to ballooning of the capsule by the underlying haematoma. The capsule is then incised to expose the fracture which is reduced and fixed with a K-wire (Fig 5), or with mini-fragment A-O screws (1.5mm or 2mm) (Fig 6). The incision is closed in layers and the thumb splinted in an aluminium splint for three weeks before being gently mobilised under supervision of the physiotherapists.

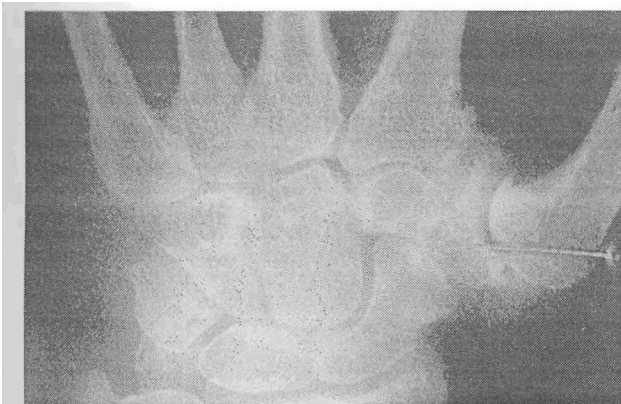

FIG 5 Method of fixing a Bennett's fracture with a Kirschner wire

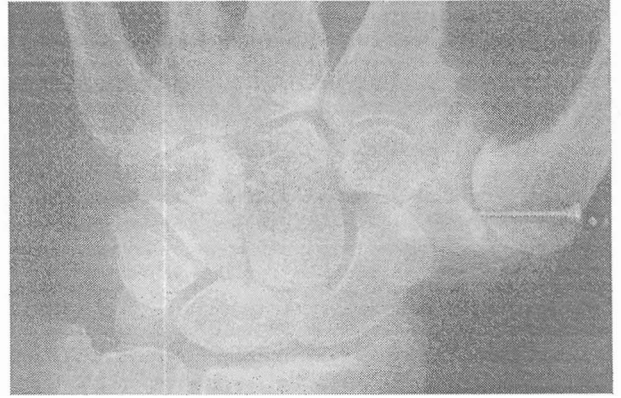


FIG 6 Method of holding a Bennett's fracture with a 2mm A-O screw

Results

The experience gained from the cadaver dissections enabled us to find the natural course of the median nerve across the forearm with particular reference to its recurrent motor branch to the thenar eminence. We found safe direct volar access to the first carpometacarpal joint and thereby obtained exact reduction of the fractures. Good reduction was obtained in all 18 patients with restoration of the function of the thumb. The results were good in terms of range of joint movements and radiographic appearance and there was no case of nerve injury encountered.

Discussion

The nature of Bennett's fracture makes visualization of the small proximal fragment which is usually anterior, difficult through the commonly used dorsal approach. The volar approach has been thought difficult and dangerous for fear of injury to the recurrent motor branch of the median nerve which supplies the thenar muscles²². The experience gained from our cadaver dissections showed that it is safe to approach and expose the Bennett's fracture anteriorly. This approach gives good exposure facilitating direct reduction and stabilisation with K-wires or lag screws from the mini-fragment set.

This is a much easier and more direct approach than that described by Gedda and Moberg⁸ which involves resection of the thenar muscles from their insertion. These fractures are commonly seen in young patients, usually under 40 years of age, and the end result, if poor, has major social repercussions²³ leading to a poor grip which may grossly affect the performance of manual work. This

direct volar approach is recommended because it allows easy exposure and minimal trauma to the soft tissues.

References

- 1 Bennett E H. Fractures of metacarpal bones. *Dublin J Med Sci* 1882; 73:72-75.
- 2 Cooney W P, Chao E. Biomechanical analysis of static forces in the thumb during hand function. *J Bone Joint Surg* 1977; 9A:27-36.
- 3 Muller M E, Allgower M, et al *Manual of Internal fixation*. Abridged A-O manual Limited 3rd Edition. New York, Springer Verlag 1992; 480.
- 4 Bennett E H. On the fracture of the metacarpal bone of the thumb. *Br Med J* 1886; 2:2-13.
- 5 Breen T F, Gelberman R, et al Intra-articular fractures of the basilar joint of the thumb. *Hand Clin* 1988; 4:491-501.
- 6 Oosterbos C J, deBoer H. Non-operative treatment of Bennett's fracture: A 13-year follow up. *J Orthop Trauma* 1995; 9:23-27.
- 7 Timmenga E J, Blockhuis T J, et al. Long term evaluation of Bennett's fracture. A comparison between open and closed reduction. *J Hand Surg* 1994; 19:373-7.
- 8 Gedda K O, Moberg E. Open reduction and osteosynthesis of so called Bennett's fracture in carpometacarpal joint of thumb. *Acta Orthop Scand* 1953; 22:249-257.
- 9 Gedda K O. Proceedings, British Orthopaedic Association: Studies on Bennett's fracture: anatomy, roentgenology and therapy. *Acta Chir Scand (Suppl)* 193. 1954:771.
- 10 Thurston A J, Dempsey, S M. Bennett's fracture: A medium to long term review. *Aust NZ J Surg* 1993; 63:120-123.
- 11 Kahler D M. Fractures and dislocations of the base of the thumb. *J South Orthop Ass* 1995; 4:69-76.
- 12 Badger F C. Internal fixation in the treatment of Bennett's fracture. *J Bone Joint Surg* 1956; 38B:771-3.
- 13 Green D P, O'Brien R et al. Fractures of the thumb metacarpal. *South Med J* 1972; 65:807-814.
- 14 Crawford G P. Screw fixation of certain fractures of the phalanges and metacarpals. *J Bone Joint Surg* 1976; 58A:487-492.
- 15 Brazier J, Monghanghab M. et al. Articular fractures of the base of the first metacarpal. Comparative study of direct osteosynthesis and closed pinning. *Ann Chir Main Memb Super* 1996; 15:91-9.
- 16 Hein V, Pfeiffer K M et al *Small fragment manual*. Technique recommended by ASIF Group. New York, Springer Verlag 1986.
- 17 Ruedi T, Burri. et al. Stable internal fixation of fractures of the hand. *J Trauma* 1971; 11:381-389.
- 18 Hruska I, Kubes, R. Personal experience with use of the Herbert Screw in orthopaedics and traumatology. *Acta Chir Orthop Traumatol* 1993; 60:81-87.
- 19 Chabon S J, Siegel D B. Use of Herbert bone screw compression jig to reduce and stabilise a Bennett fracture. *Orthop Rev* 1993; 22:97-99.
- 20 Wagner C J. Methods of treatment of Bennet's fracture dislocations. *Am J Surg* 1950; 80:230-231.
- 21 Mast J, Jacob R, Ganz R. *Planning and Reduction Technique in fracture surgery*. Berlin, Heidelberg, New York, Springer 1989; 450.
- 22 Papanathassion (1968) As quoted in *Gray's Anatomy* 37th Edition New York Churchill Livingstone 1989; 1133.
- 23 Surzur P, Rigault M, et al. Recent fractures of the base of the first metacarpal bone. A study of a series of 138 cases. *Ann Chir Main Memb Super* 1994; 13:122-34.