

# A plastic operation for scrotal filariasis

L D Stirling FRCS  
Dar es Salaam, Tanzania

**Key words:** scrotal filariasis, plastic repair

**An operation is described for the relief of elephantiasis of the scrotum, with particular attention to minimising haemorrhage and to restoring normal functional ability of the genitalia.**

## Introduction

### MORBID ANATOMY

In most patients suffering from scrotal filariasis, the scrotum is grossly enlarged by lymphoedema of the skin and subcutaneous tissues, which usually affects also the body of the penis and the outer layer of the prepuce (if any), so that the penis is completely buried in the scrotum. The corpora of the penis, however, and the inner layer of the prepuce remain always unaffected. The testicles are usually somewhat swollen and enclosed in large hydroceles but they have otherwise a normal appearance. The co-existence of elephantiasis of the legs, although occasionally seen, is unusual. This is difficult to explain. Conversely, patients with severe elephantiasis of the legs rarely have scrotal involvement. Occasional scrotal cases are seen where the penis is not involved, and likewise there are cases where only the penis is swollen, with no involvement of the scrotum; but these are rare.

### Patients and methods

I treated 150 patients with scrotal filariasis between 1935 and 1964 in the rural hospitals of Lulindi, Ndanda, Mnero, and Mango Districts of Southern Tanganyika (now Tanzania). All the patients came from the Lukuledi and Mbwemkuru valleys, where

filariasis (*Filaria bancrofti*) is endemic, except for one patient who came from Lake Nyasa. The author himself, travelling extensively in that area, suffered a mild attack which responded to medical treatment, but all the cases described here were severe, with scrotal masses up to 40lbs weight.

### OPERATIVE TECHNIQUE

The aim of surgery is a plastic and functional restoration of the scrotum and penis, which is furthered by making use of the small but adequate amount of unaffected skin available. Resection of the elephantoid mass becomes then only secondary, with no premature cutting into it. The operation has thus four stages:

- 1 the formation of the new scrotum,
- 2 the liberation and re-clothing of the penis,
- 3 the liberation and re-housing of the testicles, and
- 4 the resection of the redundant mass of elephantoid tissue.

Planned in this way the operation is straightforward. Bleeding is minimal and a good functional and even cosmetic result is obtained. Essential points to note are:

- 1 There is always a small amount of unaffected skin at the top of each side of the scrotum, and this is just enough to cover the testicles. This is skin from the groins which has been gradually dragged down by the weight of the scrotal mass, and so the larger and heavier the mass, the more skin becomes available.

2 as the inner layer of preputial skin is never affected but is increased in extent by the dragging down, it always provides enough cover for re-clothing the penis, except in the rare cases where the penis stands out as a cylinder of the elephantoid tissue (see below).

3 haemorrhage is easily controlled by careful dissection of the skin-flaps, and entirely prevented during the stage of resection by securing the vessels at their source at the neck of the scrotum.

#### SKIN PREPARATION

The elephantoid scrotum is difficult to clean and, whatever method is used, the condition of the tissues and the proximity of the anus to the posterior end of the wound makes some degree of infection almost inevitable. Routine antibiotic cover is therefore recommended.

#### ANAESTHESIA

Spinal anaesthesia up to thoracic 10 level confers every advantage for this operation and has proved entirely satisfactory without any supplement. (Chlorpromazine makes a good premedication, and ephedrine (30mg im) is injected at the time of the spinal puncture.

#### POSITIONING OF THE PATIENT

The patient lies normally on the table, with the mass resting on the closely adducted thighs. As the scrotum is rolled from side to side, or even up on to the abdomen, its weight acts as an excellent tractor (Knott<sup>4</sup>) fully exposing the area of the incisions. In a very fat patient, or one with elephantiasis of both legs as well, it may be necessary to abduct the legs widely, flex the knees, and support the feet on stools, (as recommended by Knott) in order to get adequate access to the posterior end of the wound. This is not necessary in most cases and the stool tends to get in the surgeon's way. (At one time I used a sterilised block and tackle, rigged on a cross-bar supported on lithotomy crutches for raising the mass and exposing the operation area, but I gave this up as it proved unnecessary for scrota of average size). The lithotomy position, as originally advocated by Manson, does nothing to facilitate the operation but rather the reverse, and should be avoided, as also Manson's scrotal tourniquet, which is unnecessary, unhygienic, troublesome to apply and remarkably ineffective. However, a **large** myomectomy screw may be driven into the bottom of the scrotum and

held by an assistant who can then control the mass very nicely. A domestic corkscrew is rarely strong enough.

#### THE SCROTAL FLAPS

The upper and lateral aspects of the scrotum are inspected and carefully palpated to determine the extent of unaffected skin above the area of frank elephantiasis, and flaps are then marked out as generously as possible. Skin that can be picked up between finger and thumb, without any rubbery feeling, can be regarded as "healthy".

The incisions begin in front of and rather below the pubes, at the point (A in figure 1) where the dorsum of the penis is to be attached. They curve round in an arc on either side till their extremities are distant from A by rather more than the estimated width of the penis. From these two points (BB in figure 1) they are carried downwards in even curves on the sides of the scrotum, as already marked out, and meet again in the mid-line at the back, at an acute angle but as far in front of the anus as possible.

The right-hand flap is now raised as follows: the incision is first made lightly throughout its length, and then cautiously deepened about its middle, as this is the area where the layers are most easily defined. The dartos, much thickened, is carefully divided until an interval is found exposing the

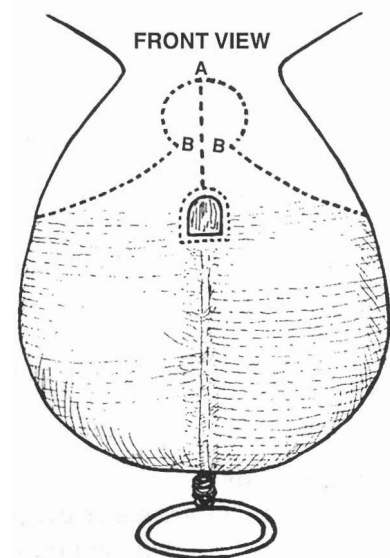


FIG 1 *The incision from the front*

external spermatic fascia. Only oozing should come from the tissues so divided. In this part of the scrotum the interval mentioned is very easily defined and is followed upwards and downwards, dividing the dartos by snipping with Mayo's scissors and taking great care to avoid the large and numerous vessels which lie immediately beneath it. In this way haemorrhage may be kept within reasonable limits. Any larger vessel that may be accidentally divided is easily picked up with forceps. At both ends of the incision the tissues are more densely adherent, and their separation therefore causes rather more oozing, although the vessels met here are smaller.

When bleeding is controlled, the flap of skin and dartos is further raised by gentle separation from the spermatic fascia with a large moist swab. This is usually very easy if the right layer has been defined. The scrotum is stripped from the flap rather than the flap from the scrotum, in order to minimise trauma to the flap, which is either held in a large moist swab or retracted with skin-hooks. This dissection should be carried as high up as possible, partly to provide adequate flaps for the new scrotum and also to obtain new lymphatic drainage, as emphasised by Connell. As the flap is raised, the vessels supplying it will be exposed; they are large and easily injured. They must be carefully preserved to ensure the vitality of the flap.

When the right flap is completely reflected, all bleeding points are secured and the flap is wrapped in a large pad soaked in ice-cold normal saline and placed so as to be free of pressure or distortion. The raw surface of the scrotum, however, has been kept covered throughout with warm moist pads, and any bleeding vessels on it are simply left clamped, as they will be all divided higher up in due course. The surgeon then moves to the patient's left side, and raises the left-hand flap in the same way.

#### LIBERATING THE PENIS

The surgeon works again from the right. When the penis is completely buried, as is often the case, the thick skin overlying it is first slit longitudinally from above downwards, starting from the semicircular incision already made round its base. This cut may well be made with diathermy, to avoid bleeding, as all this skin will be discarded.

The two halves of this redundant skin are then seized with volsella and stripped from the underlying penis, which is easily identified under the fascia and can be mobilised by gentle dissection with a finger, care being taken to preserve the dorsal vein. The skin incision is then prolonged carefully downwards until the margin of the inner skin of the prepuce is found. It is always thin and smooth, and is now divided by a circular cut right round the end of the penis, which is then completely separated. The attachment of the fraenum is often tough and must be divided by the knife, with ligation of one or more vessels.

The penis is now lifted from its bed and carefully freed by gentle finger dissection on its ventral aspect, as far back as may be judged necessary to secure a mobile organ. At this stage it is advisable to pass a large sound into the bladder to verify the position of the urethra. In the deeper part of the wound it is often surprisingly superficial, and could easily be damaged by too free dissection or ligation. The sound should not be left in situ, as subsequent manipulations will disturb it, with possible damage to the urethral mucosa. It may be passed again, however, as necessary and at least finally before closing the wound.

The penis being now sufficiently mobilised, the inner preputial skin is everted over it and will normally be found to cover it very nicely. The penis is wrapped in gauze and laid aside.

#### LIBERATING THE TESTICLES

The surgeon now thrusts the blades of a blunt-pointed pair of scissors through the spermatic fascia at the side of the neck of the scrotum, as high up as possible, and opens them widely. A finger inserted into this slit at once encounters the spermatic cord. In fact, the cord often presents spontaneously as soon as the slit is made. It is rapidly separated and hooked out by the finger, and then secured in a loop of gauze which is given to an assistant to hold. While the assistant makes gentle traction upwards, the surgeon's finger follows the cord down into the scrotum until it reaches the testicle, usually enveloped in a hydrocele, which is separated by sweeping movements of the finger until it can be bought up and delivered through the slit. The testicle is then wrapped in a warm moist gauze and laid aside, the hydrocele being left intact at this stage. Difficulty may be encountered in separating the

lower pole of the testicle owing to a tough fibrotic remnant of the gubernaculum testis. This may be divided by long blunt-pointed curved scissors passed blindly and guided by the finger.

If access to the testicle is difficult, the dense bands of fascia and vessels lateral to the spermatic cord should be divided between clamps as high up as possible. This allows a considerable dropping down of the scrotal mass, leaving the testicle partially exposed. Where the scrotum is very large it may still be impossible to reach the testicle with a finger, and the whole hand must be inserted. This may require wide division of all the layers on the front of the scrotum, which should be done with the diathermy knife as otherwise bleeding is profuse. (Clamps are liable to slip, as the blubbery tissues here may be up to two inches thick).

Alternatively, Connell's method may be used. After both cords have been isolated, the entire pedicle is clamped and divided, and the testicles then dissected out of the separated mass. This method is also advisable in those cases where old inflammation, with abscess of the scrotum, or previous palliative operations, have left a grossly adherent testicle. If the testicle is not only adherent but diseased it is better removed; provisional consent for this should therefore always be obtained beforehand. The cavity from which the testicle was removed is now packed with a large pad to check oozing, and the surgeon then delivers the left testicle in the same way, from the left side.

#### THE RESECTION

All important structures being now out of the way, the huge pedicle of the elephantoid mass is divided into sections between large strong clamps (Fig 2). The temptation to include too much of the pedicle in a large clamp must be resisted, or there will be difficulty and even danger with the ligatures. When division of the pedicle is complete, the whole mass is removed, allowing free access to the wound. The tissues held in the clamps are transfixed and tied with strong ligatures, and any remaining bleeding points picked up. When dividing and transfixing the pedicle, the proximity of the urethra, as already mentioned, and also of the rectum, must be borne in mind.

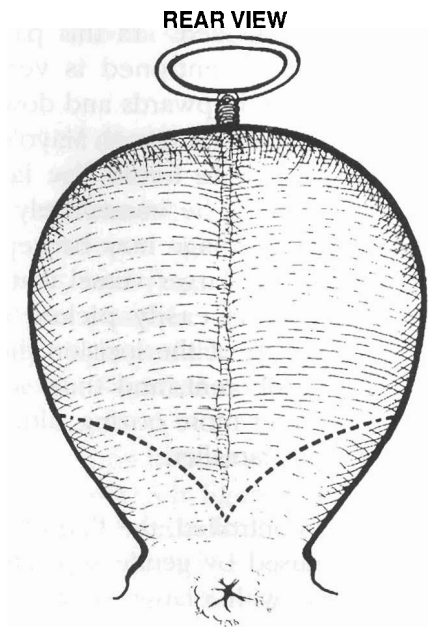


FIG 2 *The incision viewed from the back*

#### THE CLOSURE

The testicles are inspected, and any bleeding arrested. The hydroceles usually present are incised, emptied, and the tunica vaginalis everted after Jaboulay's method. If the incisions in the tunica are made through a bloodless part and kept small (only just large enough for the testicle to slip through) there is no need for any retaining sutures. The testicles are again temporarily wrapped in moist gauze. The two scrotal flaps are now approximated from behind forwards. A sharp hook is inserted in the lower angle of the wound and drawn well forward, and the skin edges are united with Michel's clips. No stitches to the dartos are needed, as the flaps lie well together in their full thickness and always unite well. When rather more than half the wound is closed the testicles are inserted in their proper position and closure is continued until points B and B are approximated (Fig 3). A well-marked angle at B on each side, ensures good apposition here. Otherwise a troublesome gap is likely, which will delay healing. The cut edge of the inner preputial skin, now at the base of the penis, is stitched to the semi-circular wound edge, which now becomes a complete circle, and reconstruction is complete.

SKIN FLAPS

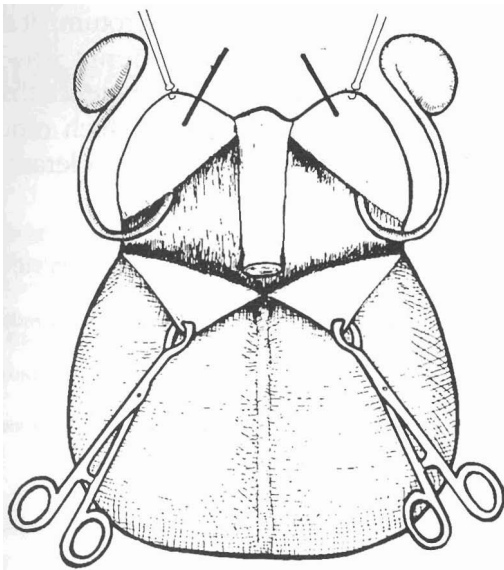


FIG 3 Dissection of the scrotal tissue

A corrugated rubber drain is inserted low in the scrotal wound, as with every care there is always considerable oozing. Adhesive dressings are applied, and secured in position with a T-bandage over a generous pad of cotton wool. Manson advised tying in a catheter but I have never found this necessary and it is better avoided.

#### ABNORMAL PENILE INVOLVEMENT

In a few cases, the penis is not involved and can be left alone but in a few others, quite rarely, instead of being buried, the penis protrudes as a solid cylinder of elephantoid tissue. In such cases it must be flayed completely, and if the patient was circumcised there is likely to be no inner preputial skin available to cover it. Split-skin grafts must then be taken from the thigh and wrapped round the penis. These are secured with a sterile one-inch woven bandage and take well.

#### POSTOPERATIVE CARE

Morphine is given postoperatively rather than pethidine, to prevent erection and maintain constipation. The drain is removed after 36 hours. Alternate clips are taken out on the sixth day, and the remainder as soon as possible after this. The patient is kept constipated until the seventh day at least, to avoid soiling the wound where it approaches the anus. He is then relieved with an

REPAIR COMPLETED

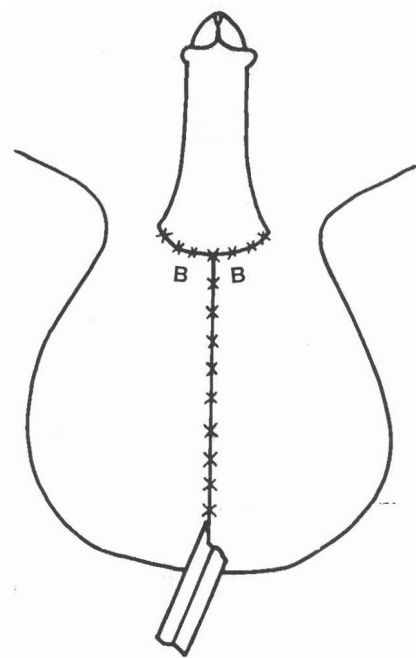


FIG 4 The final closure

enema. Early ambulation is not only desirable but is much appreciated by a patient who has been relieved of an intolerable load.

#### Results

All the patients had good anatomical restoration but it was difficult to assess the physiological response as the patients came from far and follow-up was, in most cases, impossible. There was one postoperative death, from shock. This occurred early in the series before the technique of avoiding excessive haemorrhage was fully developed. No recurrences were seen.

#### Discussion

The classical operation for filariasis of the scrotum was that of Manson<sup>1</sup>. That was followed by that of Connor<sup>2</sup>. In both of these operations the scrotum was bisected and then totally resected after extracting the testicles and spermatic cords. Emphasis was placed on the removal of every scrap of lymphoedematous tissue, for fear of recurrence. This procedure was followed by burying the testicles in the groins and then clothing the penis with Thiersch skin-grafts. Both these expedients have obvious disadvantages and both those operations caused alarming haemorrhage which was very little

affected by Manson's scrotal tourniquet. In 1932, Connell of Tanga (later of Dar es Salaam) published his alternative operation designed to avoid these difficulties<sup>3</sup>. He showed that if dissection was carried deeply between the groins and the perineum, new lymphatic drainage was established which relieved the lymphoedema and so allowed some of the scrotal tissue to be used for re-construction without fear of recurrence of elephantiasis. He also made use of the inner preputial skin (always much elongated by the weight of the scrotal mass) to clothe the penis. He did not, however, do an anatomical reconstruction of the scrotum but simply left enough tissue hanging down to cover the testicles with what he called "a collar". This was a rather lumpy and

untidy affair, hardly calculated to satisfy a patient (or his wife) who wanted a good cosmetic reconstruction of both penis and scrotum. It should be appreciated that most patients are more concerned with their anatomical impotence than with the mass of unwanted tissue, of which otherwise they have often become remarkably tolerant.

### References

- 1 Manson-Bahr P H *Manson's Tropical Diseases* 10th ed, London, Cassel & Co Ltd 1935; 716-717.
- 2 Connor F P *Surgery in the Tropics* Edinburgh and London J & A Churchill, 1929; 205-220.
- 3 Connell W K. The operative treatment of the elephantoid scrotum *Br J Surg* (1932) 19:651-658.
- 4 Knott, in *Manson's Tropical Diseases* 10th ed, London, Cassel & Co Ltd 1935:7.7.