

# Anatomical basis of low back pain and its treatment by rhizolysis

R C Miralles MD PhD\*, J Carbelledo MD\*\* and A Ruiz MD PhD\*

\*Hospital Sant Joan and School of Medicine, Universitat Rovira i Virgili, Reus, Spain and

\*\*Hospital Central de Maputo, Mozambique

**Key Words:** Back pain, anatomy, lumbar spine, rhizolysis

**The authors' approach to the management of low back pain is reported. The relevant anatomy of the nerves and joints is assessed, especially the dorsal ramus of the spinal nerve. The criteria for radiological evaluation of the painful area are described and the use of articular infiltration as a diagnostic tool is recommended. In appropriate cases, rhizolysis may be performed which can be of considerable benefit. It is a fast, inexpensive and, now, safe technique. We review 64 cases with a follow up of three years. The good-to-excellent results were 87.8%.**

## Introduction

Low back pain (LBP) is a considerable socio-economic problem, not just in developed countries. It has been estimated that as many as 85% of people in the western world<sup>1,2</sup> are afflicted with some degree of LBP at some time in their lives; frequently during the most productive years between the ages of 25 and 60. At a younger age the pain is usually mild but, subsequently, the back pains become more severe and sciatica more frequent.

In most cases LBP is transient. Of the patients with

acute LBP, 90% improve within two months. This percentage declines to 2%-3% after six months and 1% after a year. Those patients that recover face a 60% recurrence rate over the following two years.

Individual risk factors for development of LBP have been identified in the classic description by Kirkaldy Willis<sup>3</sup>, but we firmly believe that increased lordosis and leg length are important factors as well. (Table I)

TABLE I Individual risk factors associated with the development of low back pain

<i>Positive association</i>	<i>Questionable association</i>	<i>No association</i>
Increasing age	Stature	Gender
Marked scoliosis	Obesity	Body mass index
Poor health	Trunk strength	
Lack of fitness	Psychiatric illness	
Smoking		
Psycho-social problems		
Drug abuse		
Headaches		
Neck pain		
Angina pectoris		
Stomach pains		
Leg length		
Increased lordosis		

In chronic back pain, some of the established factors are alcoholism, psycho-social problems, poor education, very heavy or sedentary jobs, lack of physical activity and hyperlordosis. Many of these patients suffer severe depression.

### Economic Impact

In the USA, 65% of individual health dollars are spent on back injuries. It has also been noted that only 10% of back problems are responsible for 80% of the back-related expenses. In 1976, it was estimated that the cost to the economy was 14 billion dollars a year. In 1988, this estimate was 40 billion dollars, but the American Association of Orthopaedic Surgeons arrived at an estimate of 80 billion if the cost of continuous use of pharmaceuticals, braces, physiotherapy, loss of productivity and time-loss were added<sup>3</sup>. The percentage medical costs and compensation payments for LBP was 33% medical, 22% for the temporary disability and 45% for permanent disability. In short, LBP could affect the quality-of-life of almost anybody and, consequently, the economies of all countries.

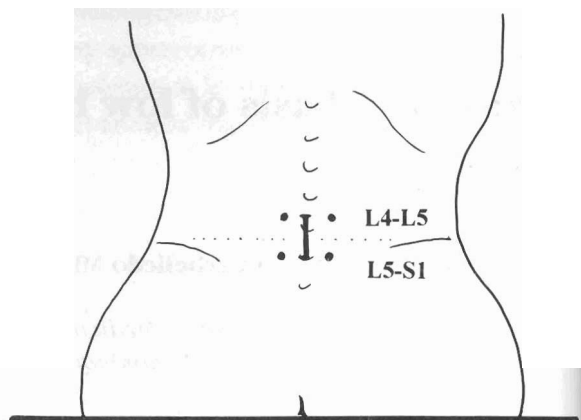
### The Authors' Approach To Low Back Pain

The first aspect to be considered must be the origin of the pain<sup>4,5</sup>. At the base of the vertebrae sensation is via the meningeal branch (also termed the sinovertebral nerve of Luschka) of the spinal nerve and the dorsal ramus of the spinal nerve<sup>6</sup>. The dorsal ramus emerges from the spinal nerve, proceeds backwards over the transverse apophysis and descends via the base of the zygoapophyseal joint while passing under the mamillo-accessory ligament. It divides into an internal (articular) branch, a middle (muscular) branch and an external (cutaneous) branch. Consequently, the dorsal ramus supplies the interapophyseal joints (two nerves at each joint), the posterior arch, the aponeurosis and paravertebral muscles as well as an extensive cutaneous region (Fig 1). The meningeal branch also emerges from the intervertebral foramen but it turns back inside the spinal canal to supply the posterior part of the annulus peripherally as well as the anterior part of the dura. The lesion, if affecting only the meningeal branch, cannot be identified from a clinical examination and, since it is usually light and transient, can be ignored.

FIG 1 Schematic representation of the dorsal ramus:

A) AR = anterior ramus DR = dorsal ramus

B) distribution of the medial ramus of the dorsal ramus in two zygoapophyseal articulations



When serious, it is superimposed on the ventral ramus and dorsal ramus lesions, hence, although the specific effect of the meningeal branch lesion may not be identifiable, the overall clinical manifestations may be effectively diagnosed.

The pain transmitted by the dorsal ramus is usually of articular origin<sup>5,7</sup>, and it is characterised by: pain associated with extension of the spine and increasing with hyperextension, no pain in flexion, pain radiating to the lower extremity in 50% of cases, but never crossing the ankle region, unaffected motor and sensory activity in the lower extremity, and pain and muscle spasm relieved by peri-articular anaesthetic blockade.

When the ventral ramus is affected (because of radicular compression, for instance, by a herniated lumbar disc), there is a segmental neurologic (sensory, motor and reflex) alteration. The most frequently injured roots are those associated with L5 or S1. The lesions ought to be correctly classified as being irritative (radiating pain, dysaesthetics and diminution of reflexes) or deficitary (motor and reflex deficit) since different treatments would apply. When the ventral ramus and dorsal ramus lesions coexist (as happens in osteoarthritis together with radicular compression due to spinal stenosis) it is termed a mixed ramus lesion and it is important to

differentiate as to which ramus lesion prevails as well as whether the ventral ramus lesion is irritative or deficitary.

In our experience<sup>4</sup>, the dorsal ramus is affected in 80% of cases, the ventral ramus in 9% and both rami in 11% of all lumbar pain. It is of interest to note that 8 out of 10 cases of radiating lumbar pain are of articular origin.

Once the pain source has been clinically identified, it becomes necessary to conduct further explorations to determine the aetiology and to arrive at definitive diagnoses.

The patient's posture should be explored in a standing position. Conducted in the frontal plane, the observations may indicate pelvic frontal tilt (resulting from different leg lengths); in the lateral plane, that of any existing hyperlordosis while, in the transverse plane, scoliosis (vertebral rotation) may be detected.

Radiographic examination should always include an anterior/posterior (AP) static view, a lateral dynamic view and two oblique projections. From the AP view, aspects such as the different heights of the iliac edges can be measured as well as the presence of morphological alterations associated with the orientation of the joints, for example the *de Anquin* anomaly (mega spinous apophysis of L5 and congenital fissure of the posterior arch of S1). Also, advanced osteoarthritis could be evaluated in this projection.

In the lateral projection, congenital canal stenosis would be indicated by the presence of short pedicles while the overall relationship between flexion and extension could provide indications of instability (spur traction) or lysis. A large osteophyte is a stabilising element and would not be of major concern but would direct attention to the posterior osteophyte as the cause of the osteoarthritis.

From the two oblique projections, the presence of spondylolysis could be assessed and the beginning of the arthritis quantified by the presence of superior, inferior or overall narrowing. Dorsal ramus lesions of young patients would be the results of anomalies

of posture (pelvic tilt and hyperlordosis) or orientation (anisotropy) while dorsal ramus lesions in adults would be the result of osteoarthritis.

A CT scan is not indicated in the initial exploration but would be if suspicion of radicular compression or canal stenosis exists.

### Articular Infiltration

The most useful diagnostic tool is articular infiltration. It is conducted with a 5ml syringe containing a mixture of methylprednisolone and 2ml svedocain and is introduced via a 22-gauge needle. The L4-L5 joint is found level with corresponding points on the iliac crests, 2cm outward and either side of the mid-line while the L5-S1 joint is located 2cm directly below (Fig 2).

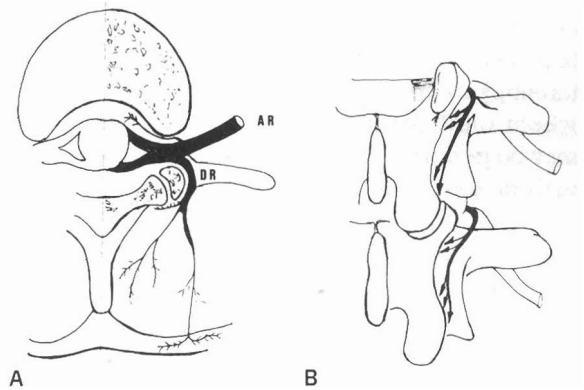


FIG 2 External reference for the placement of the infiltrations at L4-L5 and L5-S1

The "arch" sign (pain in spinal hyperextension while pressure is applied at this spot) is a very useful indicator of the articular point. Sometimes radiographs are indispensable at this stage for correct positioning, because the joints may not be located exactly at the painful spot.

The pain and muscular spasm disappear in a few minutes and a progressive improvement begins within 24 hours of the infiltration. Usually, the infiltration is repeated for two successive weeks and the patient's opinion is sought regarding improvement (approximate percentage) and

duration of pain free periods. Usually improvement is <50% with the first infiltration, >50% with the second and between 80% and 100% with the third.

If the diagnosis had been unequivocal but improvement with infiltration small, the infiltration needs to be conducted under radioscopic guidance so as to ensure intra-articular puncture.

The treatment is pathophysiological but, nevertheless, attempts must be made to rectify posture, to lengthen the lower extremities and to correct the hyperlordosis. Physiotherapy, in conjunction with additional electrotherapy (if required) and a low back pain education programme, considerably improve the prognosis.

Patients for whom rhizolysis would be indicated are those in whom infiltration has been clearly effective (although of transient duration), who have had postural correction (work, sports and relaxation training) as well as muscular re-education but in whom disability has persisted<sup>8</sup>. The denervation may be performed with chemicals (alcohol, phenol), with radiofrequency<sup>9</sup> or with temperature<sup>10</sup>.

Phenolization of the dorsal ramus is a relatively easy technique in which a mixture of phenol and glycol is injected into an intra- or periarticular site under radioscopic guidance. In the experience of the author, the results are very variable and success rarely >50%. An alternative method (described here) is that of thermocoagulation.

### Patients and methods

Patients of any age who had clear, but transient improvement with infiltration of the dorsal ramus<sup>11</sup> were recruited. The procedure was conducted aided by an automatic thermocoagulation rhizotome (ALAR Internacional, Vitoria, Espana). The equipment has two parts: the identifier and the coagulator (Fig 3).

The identifier module has three controls to assess:

#### Impedance

Tissue resistance values are used to identify the position of the nerves. When the needle is placed at a distance of 5mm from the nerve the dial should indicate between 300 and 400 ohms; the preferred value being about 350 ohms. An impedance of 700

ohms or more indicates bone proximity while the value for fat impedance is less than 250 ohms. Since all nerves have the same impedance it is necessary to actively stimulate the nerve so as to recognise the dorsal ramus.




FIG 3 Rhizotome. Coagulation module at the right side Identifier module at the left side

### Motor Stimulation

The stimulation is gradually increased from 0 to 100 mV until a paravertebral muscle spasm is provoked. Should the needle be placed near the ventral ramus, leg musculature will contract.

### Sensory Stimulation

Progressively increased from 0 to 100 mV, the stimulation attempts to reproduce the same type of pain that the patient customarily feels. No generalised pain is produced but, merely, his own local and/or radiating pain.

The rhizolysis procedure is performed under radioscopic guidance in the surgical theatre with the patient under local anaesthesia (Fig 4).

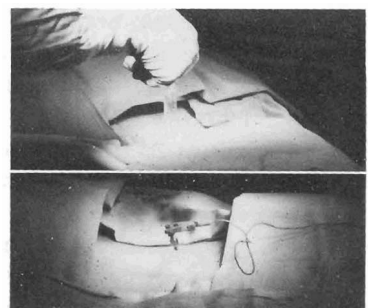


FIG 4 With the patient prone, a superficial, paravertebral infiltration is made and electrodes put in place.

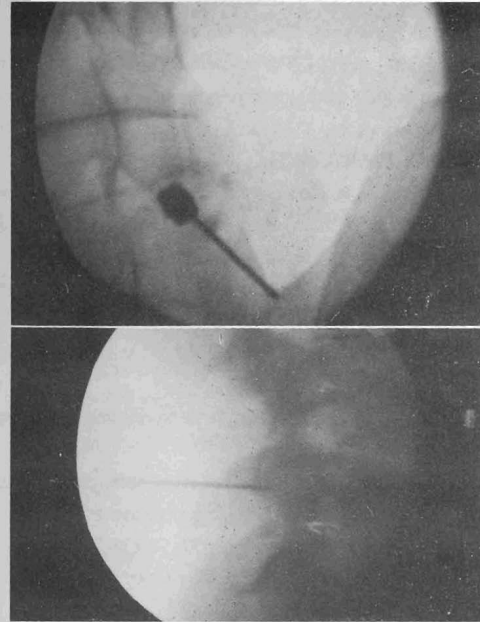


FIG 5 Superior border of the transverse apophysis and sacrum identification. Needles placed close to articular apophysis.

The patient is prone and the best view of the zone for coagulation is sought. The transverse apophysis needs to be clearly identified (Fig 5). Local anaesthesia is applied using a short needle that is normally used for cutaneous, subcutaneous and aponeurosis tissue since a deeper infiltration could anaesthetize the dorsal ramus and, hence, preclude important information on motor and sensory stimulation being obtained.

The position of the dorsal ramus is identified above the transverse apophysis in the articular base.

Once the posterior branch has been unequivocally located, the automatic coagulation, which takes four minutes, may proceed. Meanwhile the patient feels a modest increase in pain which is not excessive since analgesia is concurrent with the coagulation. In our experience, in only two cases was the coagulation procedure stopped due to severe pain.

To pre-empt immediate inflammatory reaction, 1ml of methylprednisolone is placed in each coagulation point.

The usual points selected for bilateral coagulation are L4-L5 and L5-S1, but with this procedure, coagulation at any level, even cervical, can be performed.

### Results

To date, rhizolysis has been conducted in 80 cases; 38 females and 42 males, aged 29 to 89 years (mean 53.7 years). All have been bilateral except in four cases in which the symptoms indicated only unilateral involvement.

In the initial part of the study involving 50 cases, local corticoids were not used post-rhizolysis in 25 cases and results were compared with the subsequent 25 cases in which corticoids were used. Indications were clear that corticoid therapy was necessary to preclude complications arising in the first week post-rhizolysis.

Of the 64 patients with one, two, or three years of follow-up examination, the percentage of patients with "no-to-slight pain" had progressed from 51% in the first year to 64% in the third year of follow-up. The percentage of patients with "tolerable pain" (but able to continue with their usual activities) had progressed from 14% in the first year to 24% in the third year of follow-up. The percentage of patients without improvement had decreased from 34% in the first year to 14% in the third year of follow-up.

These results may prove to be even better with the introduction of a parallel low back pain education programme in conjunction with physiotherapy for abdominal and paravertebral muscle training.

### Discussion

When the origin of the pain is known, together with a definite aetiological diagnosis, the preference is for the use of non-surgical treatment. Infiltration in or around the joint gives good results and, being quick and easy, is economically desirable as well. However, it is of note that this treatment has not attracted a consensus of opinion on the efficacy of this treatment<sup>12,13</sup>. A critical factor in an improved prognosis may be the use, as in this report, of the option of repeated infiltration.

Rhizolysis/thermo-coagulation of the dorsal ramus, although slightly more demanding technically, gives good results especially in those patients in whom infiltration has not been successful. Injection of corticosteroids at the site of coagulation precludes inflammatory reaction.

It is consistently noted that during the sensory stimulation part of the thermo-coagulation procedure, the patient's original type/level of pain is reproduced including that beyond the ankle region. Considering that no posterior primary ramus ever supplies skin or muscles of a limb in any vertebra, this poses an anatomical conundrum, a possible explanation for which is that the pain impulse is transmitted to the medulla and, via the medulla, to the extremities. This hypothesis would need further investigation.

In conclusion, thermocoagulation of the dorsal ramus has considerable advantages over the surgical alternatives. Further, the treatment may pre-empt arthrodesis in over 50% of osteoarthritic patients. However, rhizolysis *per se* may not be used as a diagnostic tool since it is unable to predict which patients would subsequently need arthrodesis.

We thank Dr Peter R Turner of SciMed Plus, Reus, Spain for his editorial assistance and help with preparation of the manuscript.

## References

1 Bergenudd H, Nilsson B. The prevalence of locomotor complaints in middle age and their relationship to health

- and socio-economic factors *Clin Orthop* 1994; 308:264-270
- 2 Waddell G. Low back disability; a syndrome of Western civilisation *Neurosurg Clin N Am* 1991; 2:719-738.
- 3 Cassidy J D, Wedge J J. The epidemiology and natural history of low back pain and spinal degeneration In Kirkaldy-Willis W H ed. *Managing Low back pain* New York Churchill Livingstone 1988; 3-14.
- 4 Miralles R C, Garcia-Almagro E. Valoracion clinica del paciente con dolor de espalda in: Monografias Liade eds *Dolor agudo y cronico*. Madrid Matgraf 1990; 107-111.
- 5 Miralles R C. Historis natural del dolor lumbar *Medicina Integral* 1990; 16:436-437.
- 6 Bogduck N, Wilson A S, Tynan W. The human lumbar dorsal rami *J Anat* 1982; 134:383-389.
- 7 Mooney V, Robertson J. The facet syndrome *Clin Orthop* 1976; 15:149-156.
- 8 Bogduck N, Long D. The anatomy of so-called articular nerves and their relationship to facet degeneration in the treatment of low back pain *J Neurosurg* 1979; 51:172-177.
- 9 Burton C V. Percutaneous radiofrequency facet denervation *Appl Neurophysiol* 1976; 39:80-86.
- 10 Brechner T. Percutaneous cryogenic neurolysis of the articular nerve of Luschka *Reg Anaesth* 1981; 6:18-22.
- 11 North R B, Han M, Zahurak M, Kidd D H. Radiofrequency lumbar facet denervation: analysis of prognostic factors *Pain* 1994; 57:77-83.
- 12 Carrette S, Marcoux S, Truchon R, Grondin C, Gagnon, Allard Y, Latulippe M A. Controlled trial of corticosteroid injections into facet joints for chronic low back pain *N Engl J Med* 1991; 325:1002-1007.
- 13 Lilius G, Laasonen E M, Myllynen P, Harilainen A, Gronland G. Lumbar facet joint syndrome *J Bone Joint Surg* 1989; 71B:681-684.