

## **Pre axial polydactyly: Our experience at the Rift Valley Provincial General Hospital, Nakuru, Kenya.**

**P. Oduor, S. Mak'Anyengo**

<sup>1</sup>Dept. of surgery, Egerton University, <sup>2</sup>Rift Valley Provincial General hospital

**Correspondence to:** Oduor P. Email address [oduorpr@gmail.com](mailto:oduorpr@gmail.com)

**Background:** Preaxial polydactyly is either complete or partial duplication of the thumb. It is most common in white and oriental populations, occurring in 1:3000 births. It is considered to be uncommon in Africans with post axial polydactyly being the most common type of polydactyly.

**Methods:** This was a prospective study over a 2 year period from January 2011 to December 2012. The study setting was the Reconstructive Surgery outpatient clinic at The Rift Valley Provincial General Hospital, Nakuru. The patients who presented to the clinic with preaxial polydactyly were recruited into the study. The demographics of these patients were obtained. The type of deformity, surgical procedure performed and outcome were documented.

**Results:** Most of the patients presented at the age of 6 months and above. The commonest type of presentation was Wassel Type IV. One of the patients had bilateral preaxial polydactyly with multiple malformations. In all the patients operated on, excision of the radial digit with reconstruction of the radial collateral ligament was performed. Two of the patients required extensor tendon transfer. All had a good post operative outcome.

**Conclusion:** Preaxial polydactyly is not common. In surgery for preaxial polydactyly careful consideration of anatomy, functional outcome and cosmetic appeal is required.

**Keywords:** Bilhaut–Cloquet . Polydactyly .Thumb duplication

### **Introduction**

The incidence of pre-axial polydactyly in Kenya has not been reported in literature. A few cases of pre-axial polydactyly have presented at the Rift Valley Provincial Hospital in Nakuru Kenya. A prospective study was carried out to determine the pattern of presentation of this congenital anomaly at the Rift Valley Provincial Hospital. Our study also sought to determine the types of anatomical deformities present in these patients as well as their surgical management.

Pre-axial polydactyl refers to complete or partial duplication of the thumb. This congenital abnormality is usually unilateral. It is more common in white and oriental populations with a reported prevalence of 1 in 3000 births<sup>1</sup>. The supernumerary thumb is more of an aesthetic issue than a functional disability<sup>2, 3</sup>. Pre-axial polydactyly can be associated with other congenital abnormalities<sup>1, 2, 3</sup>.

### **Literature review**

Thumb duplication is classified within the International Federation of Societies for Surgery of the Hand (IFSSH)/Swanson classification of congenital anomalies of the hand and upper limb as a "duplication" (group III) (Table 1)<sup>4,5</sup>.

**Table 1.** IFSSH/Swanson Classification of Congenital Anomalies of the Hand and Upper Limb

I	Failure of Formation
II	Failure of Differentiation
III	Duplication
IV	Overgrowth
V	Undergrowth
VI	Congenital Constriction Band Syndrome
VII	Generalised Skeletal Abnormalities

Polydactyly is defined as a congenital hand malformation characterized by the duplication of digits<sup>4</sup>. Polydactyly is classified anatomically based on the position of the duplicated digit(s)<sup>4</sup>. This can be pre-axial (duplication of the thumb), central (duplication of the index, middle or ring finger), post-axial (duplication of the little finger) and ulnar dimelia<sup>4</sup>.

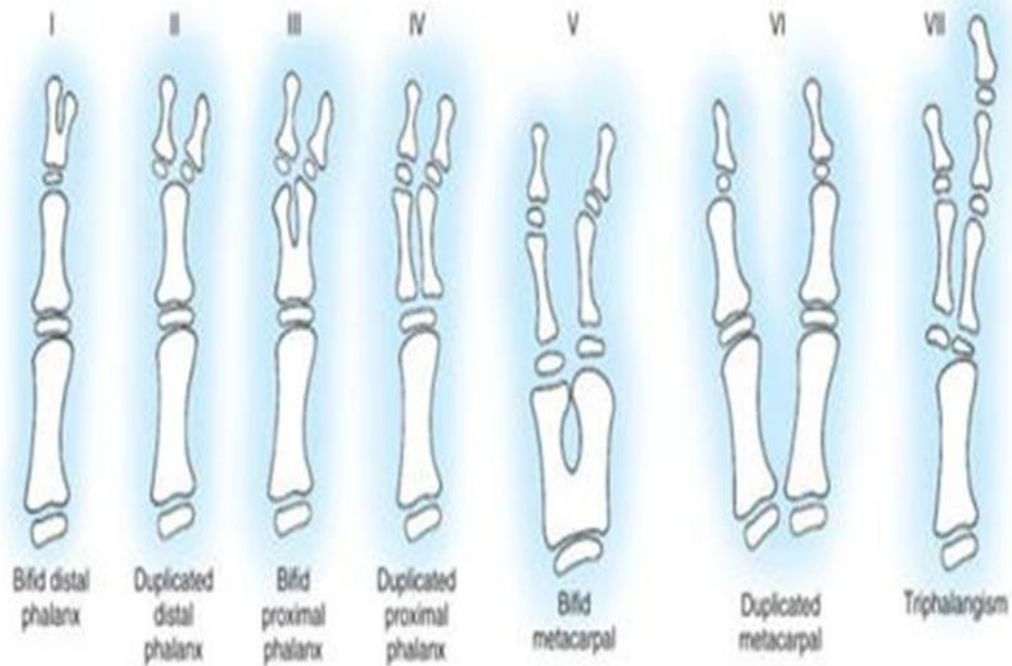
The development of the upper extremity in the embryo begins at 4 weeks gestation and achieves anatomical maturity at 8 weeks gestation. Embryological development is controlled by three signaling centres, transcription factors, proteins, and receptors. The signaling centers involved are the apical ectodermal ridge (AER), the zone of polarizing activity (ZPA) and the wingless type signaling centre (WNT)<sup>1</sup>. Thumb duplications are a failure of formation and/or differentiation affecting the radial/ulnar axis of the hand plate. The primary signal centre involved is the ZPA in the posterior part of the developing limb bud. Sonic Hedgehog protein (SHH), which is expressed in the ZPA, plays a major role in determining radial-ulnar characteristics. Abnormal expression of other morphogens such as Hox genes, Bone Morphogenic protein and Gli-3 are involved in the development of thumb duplications<sup>6</sup>.

Polydactyly results from heterogenous mechanisms. There are 39 genetic mutations that have been associated with polydactyly. These gene disorders can be single or multiple. Chromosomal abnormalities such as Down's syndrome have also been implicated. Environmental factors such as exposure to thalidomide, rubella and alcohol can result in polydactyly. All in all, 40% – 60% of polydactyly cases have an unknown etiology<sup>1</sup>. Most commonly, pre-axial polydactyly occurs unilaterally although it can occur bilaterally<sup>2, 3, 4</sup>. Though rarely associated with other syndromes and usually occurring as an isolated deformity, association with other congenital abnormalities has been reported<sup>2, 3, 4</sup>.

The spectrum of clinical presentation will range between a skin tag on the radial aspect of the hand to subtle widening of the thumb to complete duplication of the thumb<sup>1, 4</sup>. The duplicated thumb may or may not be hypoplastic though most commonly, it is<sup>1, 4</sup>. The duplicated thumb may be in the same plane as the other digits<sup>4</sup>. Typically a fibrous interconnection joins the thumbs<sup>4</sup>. The muscles innervated by the ulnar nerve tend to be attached to the ulnar most thumb and those innervated by the median nerve tend to be attached to the radial most thumb [4]. Collateral ligaments are shared between the thumbs. The neurovascular bundles may either

be shared or duplicated. Pre-axial polydactyly is best described using the Wassel classification, which describes seven classes<sup>2,4</sup>. (Figure1)

## Wassel classification



**Figure 1.** Wassel Classification

Various studies have been done to document the incidence of polydactyly and other congenital hand malformations. Few of these studies have been done in Africa. Even fewer studies document the incidence of pre-axial polydactyly specifically in Africa.

Pre-axial polydactyl has been estimated to account for 6.6% of all hand deformities<sup>7</sup>. This malformation is commonly unilateral and can sometimes be associated with other congenital abnormalities. The worldwide incidence of pre-axial polydactyly has been estimated at 1 in 3000 births<sup>8,9</sup>. It has been documented to be more common in Caucasian and Asian populations<sup>8,9</sup>. In the Middle East, a study carried out at the King Saud University Hospital in Riyadh, Saudi Arabia that sought to document the distribution of types of thumb duplication reviewed 228 hands. They noted that the most common type was Wassel type IV (33.8%) and the least common was Wassel type I (0.4%). 11.4% (26 hands) did not fit into the classic Wassel types. They included 18 rudimentary duplications, two thumb triplications, and five thumb

duplications with symphalangism. One of their conclusions stated that the pattern of distribution was in keeping with international literature with regard to the frequency of the various Wassel types<sup>10</sup> (Table 2).

**Table 2.** The distribution of various Wassel types in terms of incidence

WASSEL TYPE	PERCENTAGE
TYPE I	5.1
TYPE II	16.0
TYPE III	9.0
TYPE IV	44.2
TYPE V	13.5
TYPE VI	3.2
TYPE VII	9.0

A retrospective study published in Turkey in 2006 documented the number of patients who underwent surgery due to thumb duplication between 1983 and 2003 at an orthopedic and trauma clinic. A total of 72 patients were seen with thumb duplication during this period. Of these, 67 patients underwent surgery. 41 were females, 26 were males. The average age of operation was 2.5 years<sup>11</sup>. The Congenital Malformations Committee of the International Federation of Societies for Surgery accumulated data from seven centres in the United Kingdom, the United States and Japan in 1982. They reported a general incidence of 11 in 10,000 for all congenital hand abnormalities<sup>4</sup>. Giele et al<sup>4</sup> reported an incidence of 1 in 506 in Australia. In this study, 46% of those reported with congenital hand abnormalities had another non-hand anomaly.

A retrospective study published in the South African Medical Journal in 1982 which sought to document the incidence of all congenital abnormalities in the black population of South Africa determined that polydactyly was the commonest congenital abnormality (10.4 per 1000)<sup>12</sup>. Familial associations have been observed in certain cases. Mutations of certain genes regulating the development of digits can be transmitted genetically with varying penetrance<sup>13</sup>.

Surgical management is most often indicated for functional and cosmetic purposes. Current guidelines recommend that surgical correction be done in the first year of life with revisions between 8 and 10 years of age<sup>4,14</sup>. It is important to realise that even if the duplicated thumb is hypoplastic and seemingly redundant, simple excision rarely improves function. The aim of surgery is to create a mobile thumb with a good axis, good stability and a good cosmetic result<sup>15</sup>. Prior clinical examination takes note of the soft tissue bulk, integrity of the nail folds, mobility and stability of the joints and stability of the ligaments<sup>6</sup>. Investigations that are helpful for the pre-operative evaluation include plain postero-anterior and lateral X-rays as well as magnetic resonance imaging (M.R.I.). Plain X-rays should include the opposite upper limb for comparative purposes. M.R.I is helpful with regard to delineating cartilaginous morphology and other soft tissue anomalies<sup>6</sup>. The thumb to be excised is determined at this stage. The most dominant thumb may not necessarily be the one to be preserved<sup>6</sup>.

Principles of management hinge on: removal of the extra digit and reconstruction of the retained thumb as well as correction of the anatomical deviations that are likely to cause thumb deviation and/or instability. Post Operative splinting and physiotherapy are also mandatory<sup>4,6</sup>.

<sup>14</sup>. It is important to note that thumb function represents 40% of hand function and the simple resection of one of the two thumbs may impair hand function<sup>16</sup>. Post-operative complications include late angular deformities and joint instability. These may be managed by corrective closing wedge osteotomy or arthrodesis <sup>4,14</sup>. Other post-operative complications are infections, deformities, scar contractures, stiffness and loss of sensation<sup>4</sup>. More severe forms (Wassel III to VII) are more likely to be associated with complications <sup>4</sup>.

Though infrequent, some cases of pre-axial polydactyly have been reported at the Rift Valley Provincial Hospital in Nakuru Kenya. The aim of our study was to determine the frequency of occurrence of pre-axial polydactyly at our reconstructive surgery clinic and to identify the types of anatomical deformity present in these patients.

### **Patients and Methods**

The study design was a prospective study. The setting was the Reconstructive Surgery Clinic at the Rift Valley Provincial General Hospital, Nakuru. The patients who presented to our surgical clinic with pre-axial polydactyly over the two year period (January 2011 to December 2012) were included in the study. The demographics of these patients were obtained. The type of deformity, the surgical procedures performed as well as the outcomes were documented.

### **Results**

A total of 9 patients were seen at our reconstructive surgery clinic over the study period (Table 3). 55.6% presented at less than one year of age. 22.2% were between 1 and 5 years of age at presentation. 22.2% were above 5 years of age at presentation. The Male to female ratio was 1.25:1. Wassel types II and IV were the commonest presenting types at 33.3% and 55.6% respectively.

The other type noted was Wassel type III (11.1%). A third (33.3%) had associated malformations. Patient IFO (Figures 2-7) had a bilateral Wassel type II pre-axial polydactyly. This patient had polydactyly affecting both his feet, a cleft palate and constriction bands with auto amputation of the digits.

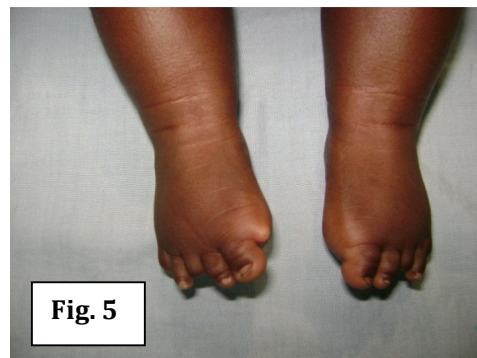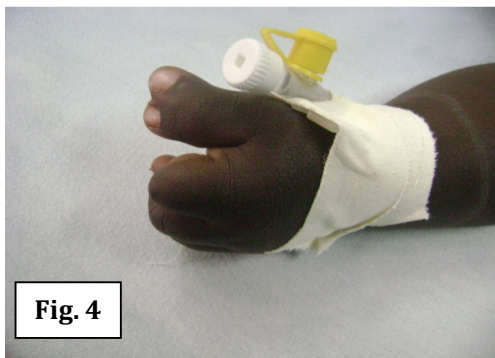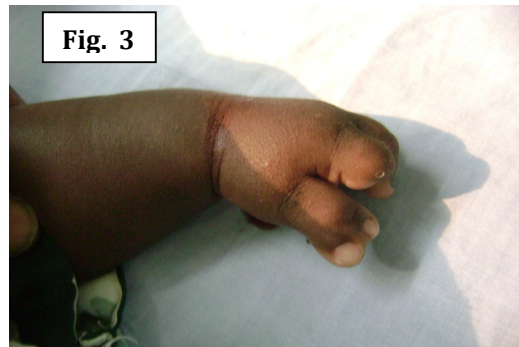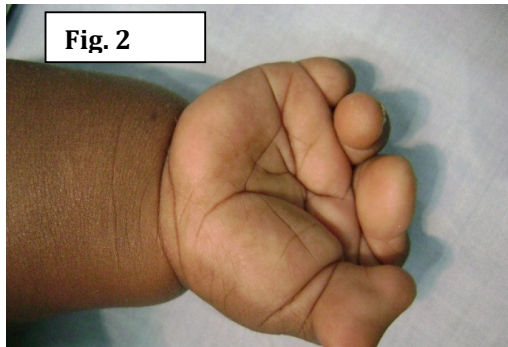Patient CW (Figures 8-11) had a Wassel type II pre-axial polydactyly with an associated abnormal extensor tendon attachment of the thumb. Patient T W (Figures 12-15) had a Wassel type IV pre-axial polydactyly with associated abnormal extensor tendon attachment as well as an abnormal thenar muscle attachment. Surgery resulted in a relatively smaller thumb compared to the rest of the fingers. In retrospect the patient would have benefited from a Bilhaut Cloquet Procedure (which consists of resection of the central part of the tissues of both thumbs and union of the other parts) which would have resulted in a thumb of normal width.

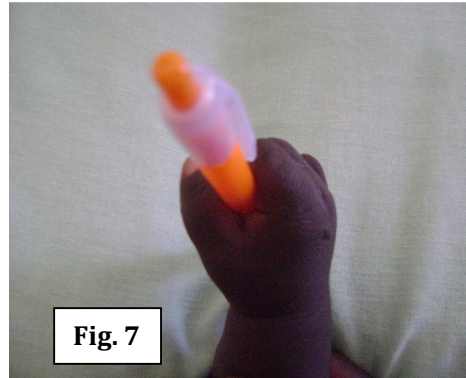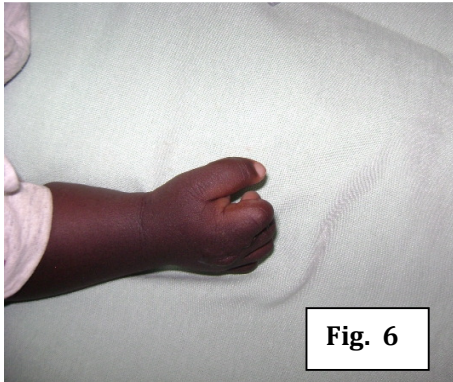
Patient AO (Figures 16-18) had a Type IV defect for which a Bilhaut Cloquet procedure was performed. Collateral ligament reconstruction was the commonest surgical strategy used (77.8% of patients). It was used on all Wassel types. The patients with abnormal extensor tendons had the extensor tendons reconstructed.

**Table 3.** Summary of Cases under Review

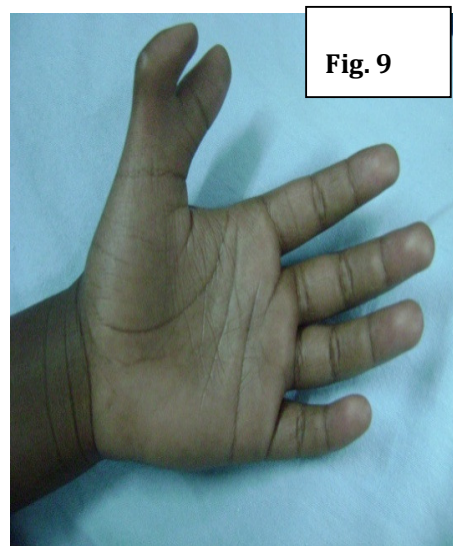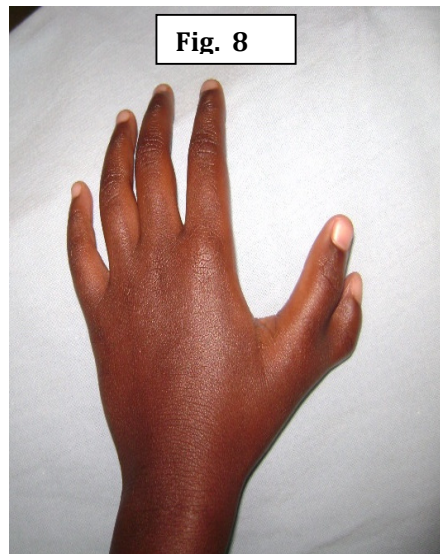
Name	Age at Surgery	Sex	Wassel Type	Associated Malformation	Surgical Strategy
SA	6/12	F	II	None	Collateral ligament reconstruction
CW	5	M	IV	None	Collateral ligament reconstruction
IFO	1.5	M	II	Polydactyly both feet, constriction bands with auto amputation, cleft soft palate	Collateral ligament reconstruction
JNW	0.5	M	IV	None	Collateral ligament reconstruction
TW	4/12	F	III	None	Collateral ligament reconstruction
AW	6/12	F	II	Abnormal extensor tendon attachment	Extensor tendon and collateral ligament reconstruction
JN	5/12	M	IV	None	Collateral ligament reconstruction
AO	3/12	M	IV	None	Bilhaut Cloquet procedure
CM	6	F	IV	Abnormal extensor tendon and thenar muscle attachment	Extensor tendon, thenar muscle tendon and collateral ligament reattachment

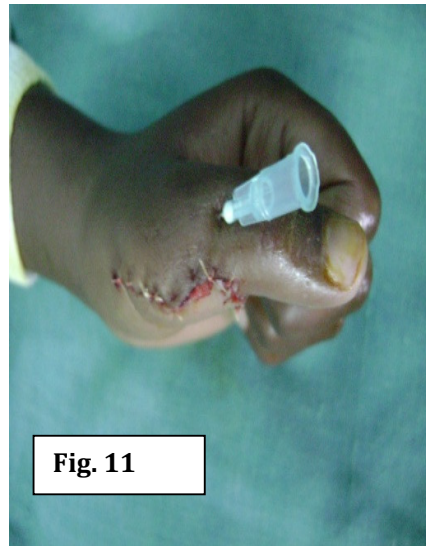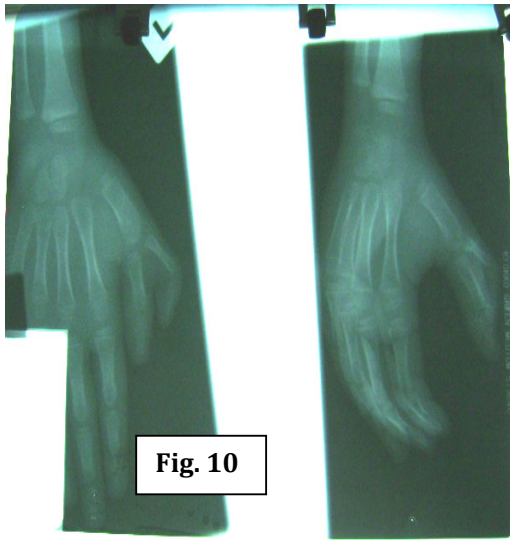
**Patient IFO**



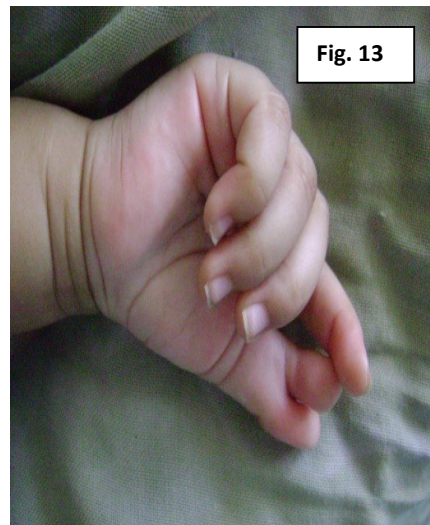
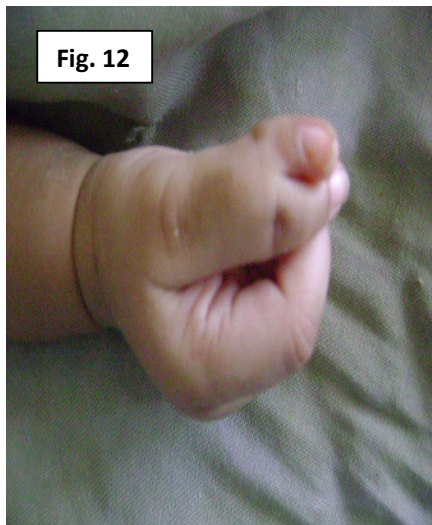
Patient CW

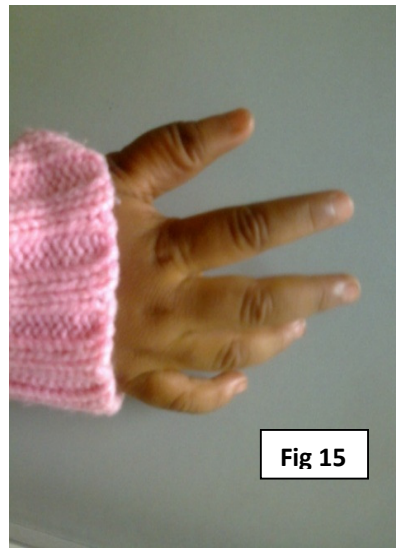
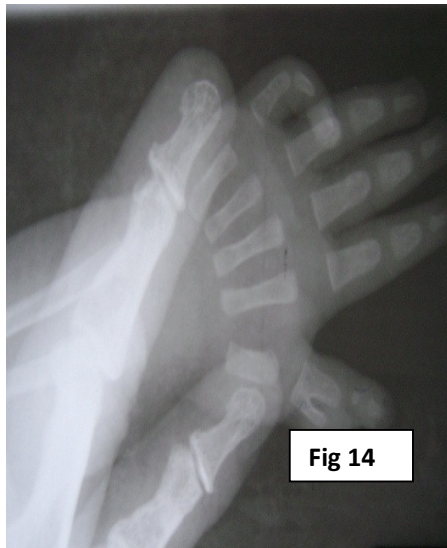


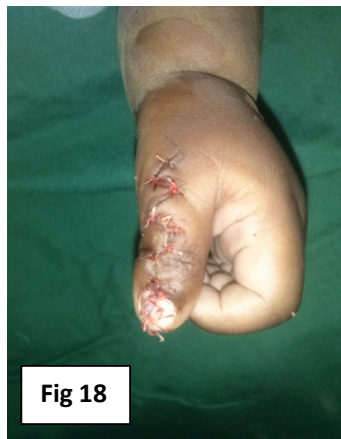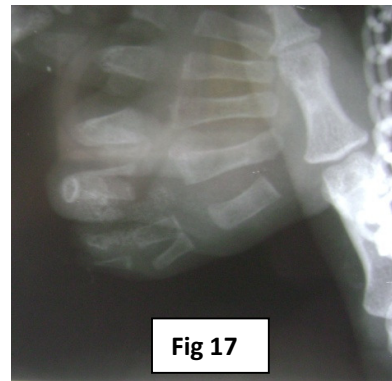
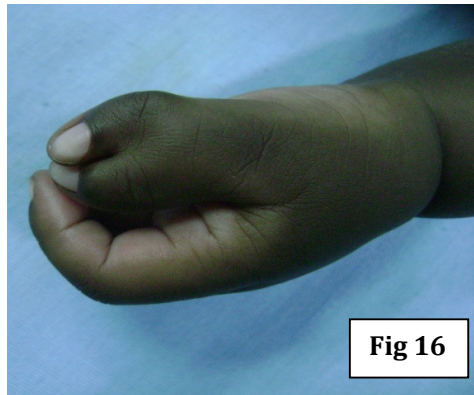**Patient TW**







**Patient A0**



6

## Discussion

Pre-axial polydactyly has been found to be more common in white and oriental populations with a reported prevalence of 1 in 3000 births <sup>1</sup>. There are no studies on the incidence of this condition in Kenya. At our clinic, we had only 9 patients over a period of 2 years, indicating that this condition is not very common.

The time of presentation to a surgical centre depends on the awareness of the parents on the availability of surgical expertise for correction of this deformity. Studies performed elsewhere indicate an average age of presentation of 2.5 years <sup>11</sup>, though guidelines indicate that surgery should be performed in the first year of life since the grip thumb-second finger appears when the child is about 1-year of age <sup>4, 14, 15</sup>. We had most of our patients presenting early, hence having the surgery performed at a mean age of 1.7 years though most of the patients were operated on within the first year of life.

A study done at King Saud University in Saudi Arabia noted that the Wassel type IV deformity was the commonest at 33.8% <sup>10</sup>, which corresponded with international literature. Our results were also in keeping with these studies where we had Wassel IV (55.6%) as the commonest. The association of pre-axial polydactyly with other malformations has been documented <sup>7</sup>. We had one patient who had multiple other congenital malformation, cleft of the soft palate, polydactyly in both feet and constriction bands with auto amputation involving some of the fingers of both hands and the toes of both feet.

In planning for surgery a simple radiological examination is usually adequate <sup>6</sup>. In all our patients the only radiological investigation performed was an X-ray of the hand affected. This combined with the clinical examination was of help in classifying the deformity according to the Wassel classification and also assist in planning the surgery. We performed collateral ligament reconstruction in all our patients except for one where the Bilhaut Cloquet procedure was performed. This reconstruction is necessary for maintaining joint stability which is of necessity in surgery for pre-axial polydactyly <sup>6</sup>.

## Conclusion

Pre axial polydactyly is not common in our environment. This malformation offers a challenge in deciding which digit should be removed. The reconstruction requires an appreciation of the anatomical deformities present. The surgical management of polydactyly has evolved from simple ablation of extra digit to well planned surgical management with careful consideration of anatomy, functional outcome and cosmetic appeal.

## References

1. Watt A, Chung K. Duplication. *Hand clin.* 2009 May; 25(2): 215-227.
2. Wassel HD. The results of surgery for polydactyly of the thumb. *Clin Orthop Relat Res.* 1969 May - Jun; 64: 175-193.
3. Tada K, Yonenobu K, Tsuyuguchi Y, Kawai H, Egawa T. Duplication of the thumb: A retrospective review of two hundred and thirty-seven cases. *J Bone Joint Surg Am.* 1983; 65: 584-98.

4. Jobe MT, editor. Congenital Anomalies of the Hand. In: Canale ST, Beaty JH, editors. Campbell's Operative Orthopaedics. 11th ed. Mosby; 2008. P4367 – 4418.
5. Swanson AB. A Classification for Congenital Limb Malformations. J Hand Surg Am. 1976; 1(1): 8–22.
6. Tonkin MA. Thumb Duplication: Concepts and Techniques. Clin Orthop Surg. 2012 March; 4(1): 1–17.
7. Naasan A, Page RE. Duplication of the thumb. A 20-year retrospective review. J Hand Surg Br. 1994 Jun; 19(3): 355-60.
8. Maillot M, Fron D, Martinot-Duguennoy V, Herbaux B. Results after surgical treatment of thumb duplication: a retrospective review of 33 thumbs; J Child Orthop. 2007 Jul; 1(2): 135–141.
9. Kumar S. An unusual bifid first metacarpal. Indian J Orthop. 2010 Aug; 44: 227-9.
10. Al-Qattan MM. The distribution of the types of thumb polydactyly in a Middle Eastern population: a study of 228 hands. J. hand surg., Eur. vol. 2010 Mar; 35(3): 182-7.
11. Ozalp T, Coskunol E, Ozdemir O. Thumb duplication: an analysis of 72 thumbs. [Turkish] Acta Orthop Traumatol Turc. 2006. 40(5): 388-91.
12. Kromberg JG, Jenkins T. Common Birth Defects in South African Blacks. S Afr Med J. 1982 Oct 16; 62(17): 599-602.
13. VanderMeer JE, Afzal M, Alyas S, Haque S, Ahituv N, Malik S. A Novel ZRS Mutation in a Balochi Tribal Family with Triphalangeal Thumb, Pre-Axial Polydactyly, Post-Axial Polydactyly, and Syndactyly. Am J Med Genet A. 2012 Aug; 158A: 2031–2035.
14. Mennen U, editor. The Hand Book. 2nd ed. Pretoria: J.L. Van Schaik; 2003.
15. Guero S, Haddad R, Glicenstein J. Surgical treatment of duplication of the thumb. Apropos of 106 cases. Ann Chir Main Memb Super. 1995; 14: 272–283
16. Townsend DJ, Lipp EB Jr, Chun K, Reinker K, Tuch B. Thumb duplication, 66 years' experience – a review of surgical complications. J Hand Surg [Am]. 1994; 19: 973–976.