

Imaging Findings and Management of Paediatric Pulmonary Hydatidiosis in an Ethiopian Referral Hospital.

S. Sisay¹, T. Amezene², H. Tadesse², D. Zewdneh¹, Y. Gorfu¹, E. Wakjira¹, A. Mong³

¹Department of Radiology, School of Medicine, Addis Ababa University, Addis Ababa, Ethiopia

²Department of Surgery, School of Medicine, Addis Ababa University, Addis Ababa, Ethiopia

³Department of Radiology, The Children's Hospital of Philadelphia, Perelman School of Medicine, University of Pennsylvania, Philadelphia, USA

Correspondence to: Amezene Tadesse, Email: amezenet@yahoo.com

Background: *Pulmonary hydatidosis is a rare disease, which may be seen in paediatric patients. The aim of this study was to describe the clinical and imaging features and present the surgical outcome of pediatric pulmonary hydatidosis in Ethiopia.*

Methods: *Clinical charts and imaging findings including chest radiographs, chest ultrasounds, CTs and MRIs of intra-operatively proven pediatric pulmonary hydatidosis cases were reviewed.*

Results: *A total of 10 paediatric cases (4 females, 6 males) with pulmonary hydatidosis were identified. Their age range was 3-12 years. Presenting symptoms included cough, chest pain and shortness of breath. Four patients were from urban central Ethiopia and 6 from rural parts of the country. All had history of contact with dogs. All imaging modalities, chest radiographs, chest ultrasounds, contrast enhanced chest CTs and MRIs, demonstrated well-defined cystic intra-parenchymal lesions. All chest x-rays showed well defined smooth walled lesions. Two chest CT scans revealed minimal post-contrast rim enhancement. All 3 patients with chest ultrasound were found to have double walled cystic masses. Two patients had postoperative complications: one developed pneumothorax and the other nosocomial infection.*

Conclusion: *Pulmonary hydatidosis in children is uncommon in Ethiopia. Imaging reveals well defined cystic intra-parenchymal pulmonary lesions. Clinicians, and in particular radiologists, should be aware of pulmonary hydatidosis, even in a pediatric population and consider it in the appropriate clinical setting in the differential diagnostic consideration of cystic intra-pulmonary lesions.*

Introduction

Hydatid disease (HD) is a zoonotic infection of humans caused by the Echinococcus tapeworm. There are two types of echinococcus infections: Echinococcus granulosus, the more common type and Echinococcus multilocularis (alveolaris)¹. HD continues to be a significant health problem in the underdeveloped world where people have extended contact with animals. It is most prevalent in sheep- and cattle-raising countries, notably in the Middle East, Australia, and the Mediterranean². HD is endemic in Ethiopia, causing significant morbidity and mortality. Several reports from different parts of Ethiopia indicate that hydatid cysts are prevalent in livestock^{3,4,5,6}.

Though HD may develop in almost any part of the body, most cysts occurs in the liver (59-75%). Pulmonary hydatidosis (PH) accounts for about 15%–25% of pulmonary lesions². The treatment is primarily surgical. We report 10 surgically proven PH from Ethiopia and review the literature.

Patients and Methods

This is a faculty based retrospective review of 10 consecutive patients who were admitted and operated for pulmonary hydatidosis in the department of surgery, Tikur Anbesa Teaching Hospital. The card numbers of patients were retrieved from the surgical ward patient admission registry and operation room patient registry books from 2012 to 2014. Only patients operated in TAH were included in the study. Age, sex, clinical presentation, surgical treatment, operative findings, postoperative complications, and immediate and 6month' postoperative clinical follow-up were recorded. Chest X-Rays, chest ultrasound, chest CT and chest MRI performed with and without intravenous contrast media were reviewed. Size, location and contrast enhancement pattern of the cysts were recorded. Abdominal ultrasound and hematological results were noted.

Results

Ten pediatric cases of PH were identified. Their ages ranged from age 3 to 12 years. There were 4 female and 6 males. Four patients were from urban central Ethiopia (Addis Ababa, and Adama); the remaining 6 were from rural parts of the country (Arsi, Bale and Dejen). All had a history of close contact with dogs. Patients presented with various symptoms that included cough in 9 patients, chest pain in 7, fever in 2, weight loss in 3, shortness of breath (SOB) in 4 and recurrent chest infection in 1 patient. The patient who presented with recurrent chest infection had bacterial pneumonia for which he was treated with antibiotics. On physical examination all of the patients had decreased air entry and dullness on percussion on the ipsilateral side of the cyst.

Nine patients had plain chest radiographs, 3 had chest ultrasound, 6 had pre and post-contrast chest CT scans, and 1 had chest MRI. Imaging shows well defined, smooth, thin walled homogenous unilocular fluid-density cystic lesions without septations, daughter cysts or calcification. Cysts ranged in size between 6 cm and 13 cm in diameter (Figures 1, 2 & 3). Minimal peripheral contrast enhancement was identified in 2 of 6 chest CT scans.

Two of the patients who were presented with cough, SOB and fever had well defined cystic lesions with echodebris and double wall on chest ultrasound. Cysts were predominantly solitary (8/10), with 3 in the left upper lobe, 1 left lower lobe, 1 right upper lobe, 2 in the right middle lobe, and 1 right lower lobe. One case was bilateral; another demonstrated multiple cysts involving both lobes of the left lung. The patient with superinfection had leukocytosis but the rest of the patients had normal laboratory and abdominal ultrasound findings. Excision of small cysts involves a posterolateral thoracotomy through which the cyst is removed in toto (Figure 4a). Pneumonostomy is reserved for larger cysts and involves minithoracotomy, in which an incision is made

through lung parenchyma overlying the cyst. Cystic fluid is aspirated and the endocyst removed (Figure 4b). A Foley catheter is inserted for further drainage, and the cavity is left open to the atmosphere with lung expansion expected within 10-21 days, at which time the catheter is removed.

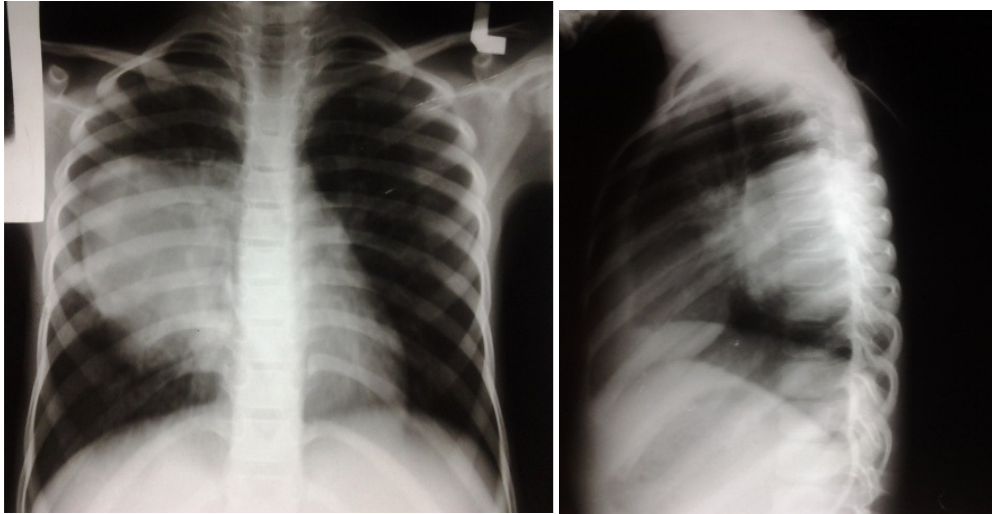


Figure 1.Pre operative PA and lateral radiographs show a well-defined intraparenchymal lesion in the right hemithorax.

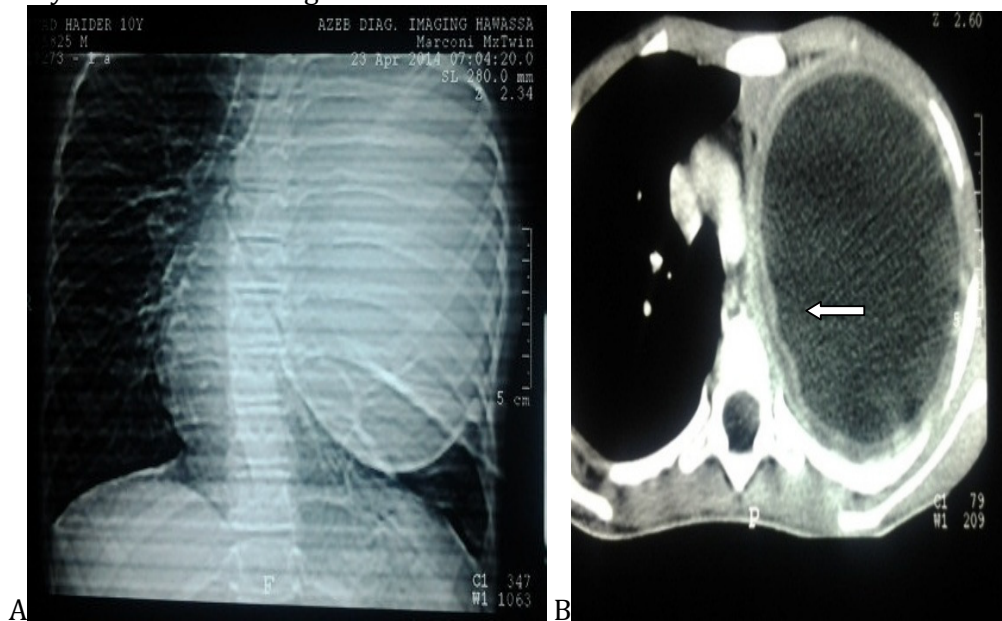


Figure 2.Scout radiograph and axial post contrast CT scan showing a well-defined intraparenchymal cystic lesion with detached wall (arrow).

Pathology Report: Histopathologic examination with standard H and E stain showed laminated (acellular) layer (a) and germinal layer with hydatid scolices (b). (Figure 5).

Post-operative recovery was uneventful with the exception of one pneumothorax (Figure 6) and one nosocomial infection. Post-operative chest radiographs (with six month follow-up) showed significant radiologic improvement in all patients (**Figure 7**).

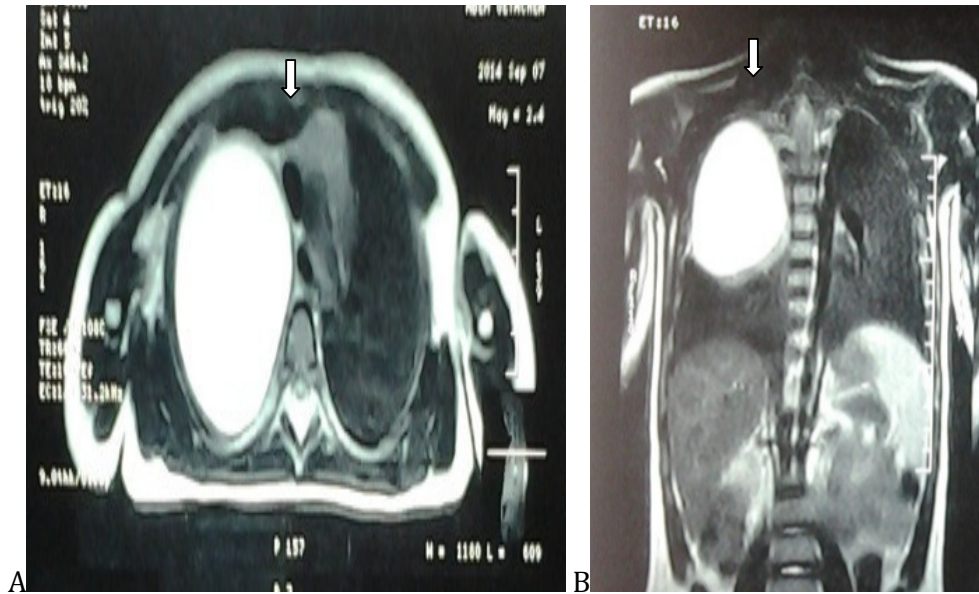


Figure 3. T2W axial and coronal chest MRI demonstrate right upper lobe well defined cystic lesion (arrow).

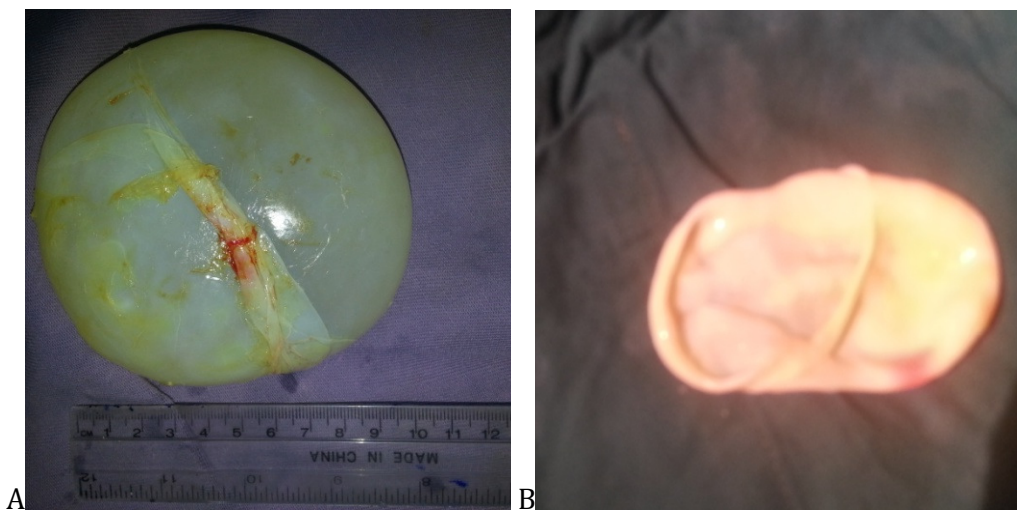


Figure 4. Cyst after surgical removal in two different patients: cyst removed in toto (a) and endocyst removed with minithoracotomy (b).

Table 1: Summary of the Clinical History, Imaging Findings, Treatment and Post operative Condition of the Patients.

Case	Age(year)/Sex	Presentati on	CXR	CT/ MRI	Treatment	Post op condition	Remark
1	3/M	Cough of 3months	-	T1WI hypointense and T2WI hyperintense signal intensity mass over the right upper lobe, no enhancement on post contrast study	Right thoracotomy	Good	
2	5/F	Chest pain of 01month	Right middle lung field well defined lesion with smooth wall	Right middle lobe well defined cystic lesion with no contrast enhancement	Minithoracotomy&pneumonostomy	Pneumothorax	Pneumothorax treated and improved
3	6/M	Cough of 2months	Left upper and middle lung field well defined lesion with smooth wall	Well defined cystic lesion with detached membrane and minimal rim enhancement	Minithoracotomy&pneumonostomy	Good	
4	6 ⁶ / ₁₂ /F	Cough, chest pain & SOB of 02 weeks	Right lower lobe well defined cystic mass	Right lower lobe well defined cystic mass, has no contrast enhancement	Minithoracotomy&pneumonostomy	Good	
5	8/M	Cough, chest pain, SOB& fever of 01 month	Left upper lobe well defined lesion with collapsed membrane and air filled cavity	-	Minithoracotomy&pneumonostomy	Good	Chest ultrasound-infected hydatid cyst
6	9/M	Cough, chest pain & weight loss of 03 years , fever	Two well defined cystic lesions involving upper & lower lobes	-	Left thoracotomy	Hospital acquired pneumonia	Chest ultrasound-5x7cm cystic lesion with echodermis and double wall
7	10/M	Recurrent cough	Right middle lung field well defined lesion with smooth wall	Well defined cystic lesion with minimal rim enhancement	Minithoracotomy&pneumonostomy	Good	
8	10/M	Cough, chest pain & SOB of 45 days	Left upper lobe well defined cystic mass	Left upper lobe well defined cystic mass with no contrast enhancement	Minithoracotomy&pneumonostomy	Good	Chest ultrasound-large cystic mass with double wall
9	10/F	Cough, chest pain, SOB & weight loss of 01 year	Well defined cystic mass over the left middle lung field	Left lower lobe well defined cystic mass	Left thoracotomy	Good	
10	12/M	Cough, chest pain & weight loss 04 months	Bilateral upper lobe well defined cystic lesion, right is larger.		Right thoracotomy	Good	Chest ultrasound-bilateral cystic mass with double wall

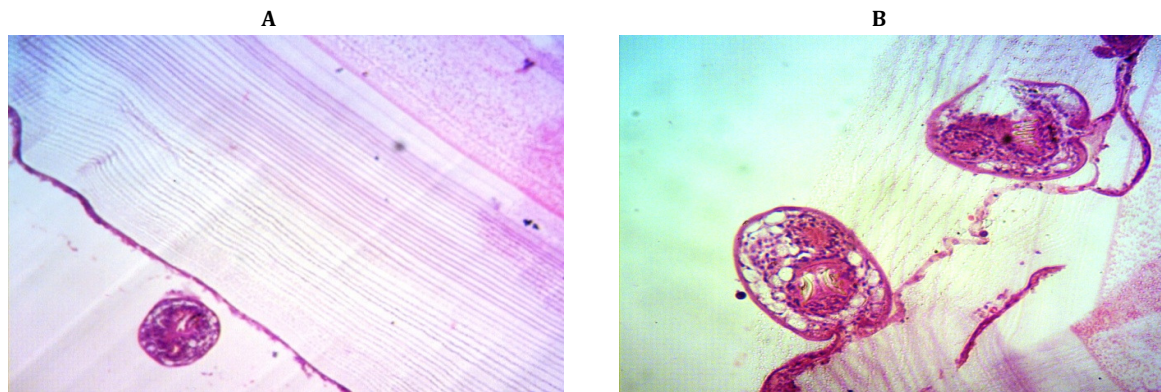


Figure 5. Histopathologic examination with standard H and E stain

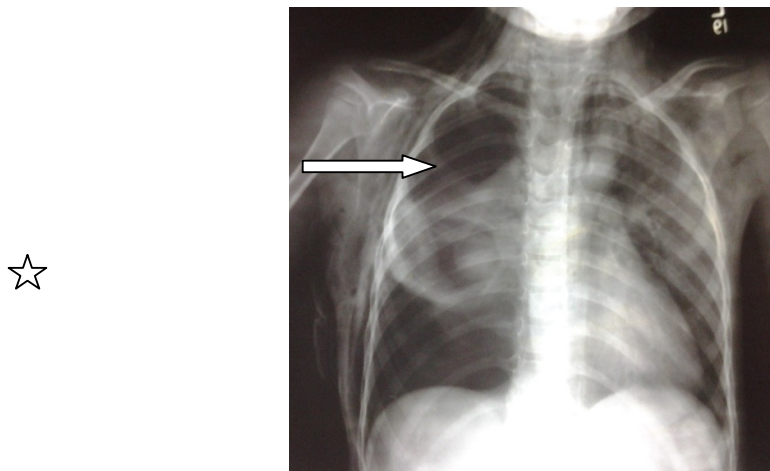


Figure 6- Post OP CXR showing pneumothorax (arrow). Surgical bed (star).

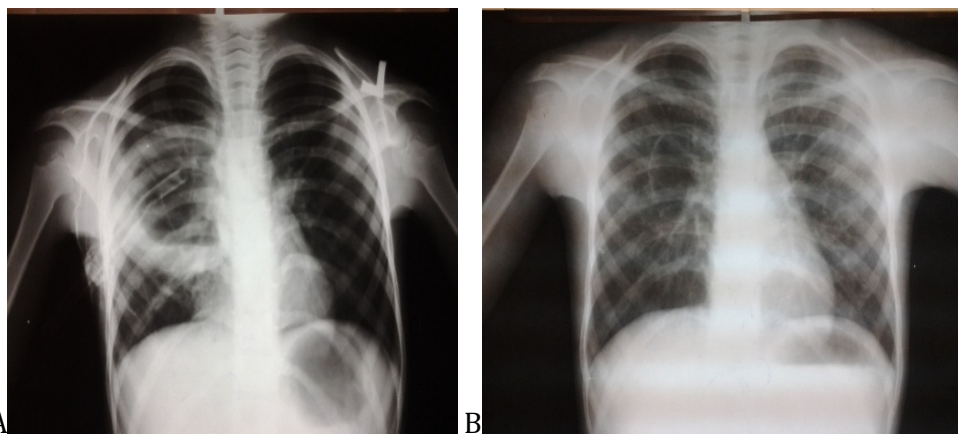


Figure 7- Immediate and 6 month follow up radiograph of the same patient demonstrate radiologic improvement with near total resolution of post-operative findings at six months.

Discussion

Hydatid disease is commonly seen in children and young adults and involves the lung in 15%–25% of cases. In the hydatid lifecycle, dogs and other definitive hosts become infected upon ingesting organs of other animals that contain either intact hydatid cysts or proto-scolices released from recently ruptured cysts. Dogs infected with *Echinococcus* tapeworms pass eggs in their feces, and humans become infected through fecal–oral contact, particularly in the course of playful contact between children and dogs. Indirect means of contact via soil, water, and contaminated vegetables, or through intermediary vectors such as flies and other arthropods may also result in human infections⁷. Socioeconomic and cultural characteristics are among the best defined risk factors for human infection, such as wide-ranging dogs living in close quarters with people, unsanitary slaughter of livestock and unsanitary living conditions⁴.

Cystic echinococcosis imposes serious medical and economic disabilities on affected communities through the economic burden associated with infection in livestock as well as the disability and treatment costs associated with infection in humans⁸. Many human infections are asymptomatic, and hydatid cysts are frequently observed as incidental findings at autopsy or detected by abdominal ultrasound or chest radiographs obtained for other reasons. In symptomatic patients, the severity of symptoms is extremely variable and never pathognomonic. The particular manifestations are determined by the site of localization of the cysts, their size, and whether they have ruptured or become superinfected⁷. The slowly growing hydatid cyst may be well tolerated by the human host until it becomes large enough to impinge upon adjacent structures or rupture. Sudden coughing attacks, hemoptysis, and chest pain are the most common clinical symptoms⁹. Cyst rupture, often resulting from trauma, may cause a variety of immediate or delayed sequelae. Mild to severe anaphylactoid reactions (and, occasionally, death) may follow the sudden massive release of cyst fluid. In the lungs, ruptured cyst membranes may be evacuated entirely through the bronchi or retained to serve as a nidus for bacterial infection. Intact pulmonary hydatid cysts may cause no symptoms, but leakage or rupture may cause chest pain, coughing, dyspnea, or hemoptysis. Hydatid membranes may be expectorated, sometimes resulting in spontaneous cure. Our cases showed no imaging evidence or surgical findings of cyst rupture.

The differential diagnosis of a cystic lesion in the pediatric chest is broad, and includes such entities as bronchogenic cysts, cavitory tuberculosis, and abscess, though the presence of a cyst-like mass with a history of exposure to sheep or dogs in areas where *E. granulosus* is endemic supports the diagnosis of HD. Noninvasive confirmation of the diagnosis can usually be obtained by immunologic techniques. Cross-sectional imaging with CT, US, or MR help to further describe lesions and delineate their extent.

While cysts are reported to be multiple in 30% and bilateral in 20% of the cases, in our series only 1 case involved both upper lobes and 1 case demonstrated multiple cysts within one lung. Calcification in pulmonary cysts, not seen in our series, is very rare, seen in 0.7% of cases (10). Centrally located cysts are usually rounded, although more peripheral cysts may be oval or polycyclic. Uncomplicated pulmonary hydatid cysts

appear as well-defined masses and range in size from 1 cm to 20 cm¹¹, in line with our series. The two cases in our series with superinfection demonstrated oval shape, detached internal membrane, and internal debris.

Conclusion

PH should be included in the differential diagnosis of cystic lung lesions, particularly in pediatric populations in areas where hydatid disease is endemic. Patients with thoracic symptoms should be evaluated for PH initially with chest radiographs, as prompt diagnosis allows potentially curative surgical intervention. Cross sectional imaging may reveal complications such as rupture or superinfection.

References

1. R. Guerrant et al. Tropical Infectious Diseases. Echinococcosis. 144: 1304- 1315.
2. Diagnostic ultrasonic imaging. I. Rumack, Carol M. et al. Hydatid Disease. 2011; 4: 93-94.
3. Kebede W., Hagos A., Girma Z & Fikre, L. 2006. Echinococcosis hydatidosis and its prevalence, economic and public health significance in Tigray region, North Ethiopia. Tropical Animal Health Production, DOI 10.1007/s11250-008-9264-9.
4. Hagos, Yihdego, 1997. Hydatidosis: Prevalence and economic impact in bovine at Mekele municipal abattoir, zoonosis and infection in dogs. DVM thesis, Addis Ababa University, Faculty of Veterinary Medicine, Debrezeit, Ethiopia (unpubl.).
5. Fikre, Lobago, 1994. Echinococcosis / hydatidosis in Konso/ southern Ethiopia: assessment trail of its prevalence, economic and public health importance. DVM thesis, Addis Ababa University, Faculty Veterinary Medicine, Debre-Zeit, Ethiopia.
6. Adem A, Hagos B, Dereje G. Experience of surgical therapy in 72 patients with hydatidosis over a 10 year period. Ethiop Med J. 2005; 43(1):1-8.
7. H.T. Lutz, H.A. Gharbi. Manual of Diagnostic Ultrasound in Infectious Tropical Diseases. Ultrasound Diagnosis of Special Infectious and Parasitic Diseases. Echinococcosis. 2006; 3: 143- 154.
8. Torgerson PR: Economic effects of echinococcosis. Acta Trop. 2003; 85:113.
9. Dogan R, Yüksel M, Cetin G, et al. Surgical treatment of hydatid cysts of the lung: report on 1055 patients. Thorax 1989; 44:192-199.
10. Jerray M, Benzarti M, Garrouche A, et al. Hydatid disease of the lungs. Am Rev Respir Dis 1992; 146:185-189.
11. Balikian JP, Mudarris FF. Hydatid disease of the lungs: a roentgenologic study of 50 cases. AJR Am J Roentgenol 1974; 122:692-707.