

Omental Evisceration Following Bicycle Handlebar Injury

N.A. Lone¹, S.A. Salati²

¹Consultant Surgery, Khyber Hospital, Srinagar, India

²Assistant Professor, College of Medicine,
Qassim University, Saudi Arabia.

Correspondence to: Dr. Sajad Ahmad Salati, Email : docsajad@gmail.com

Introduction

Direct impact bicycle handlebar-related injuries pose a serious health risk to children and result in substantial health care costs¹. The trauma is generally blunt in nature and abdominal wall rupture leading to evisceration is rarely reported in literature².

Case Report

A 10 years boy was brought to the emergency department after having fallen onto his bicycle handle bar from the front. The abdominal examination revealed an obvious protrusion of omentum through a defect in the right lower quadrant about 4 cm infero-lateral to the umbilicus (Figure 1 A). The abdomen was explored under general anesthesia and due to effect of muscle relaxants, the omentum got reduced revealing the true extent of the abdominal wall defect (Figure 1B). Other injuries were ruled out and the defect was closed in layers. There were no complications in the postoperative period. The patient was discharged on the second postoperative day and the operation site was healthy (Figure1 C).

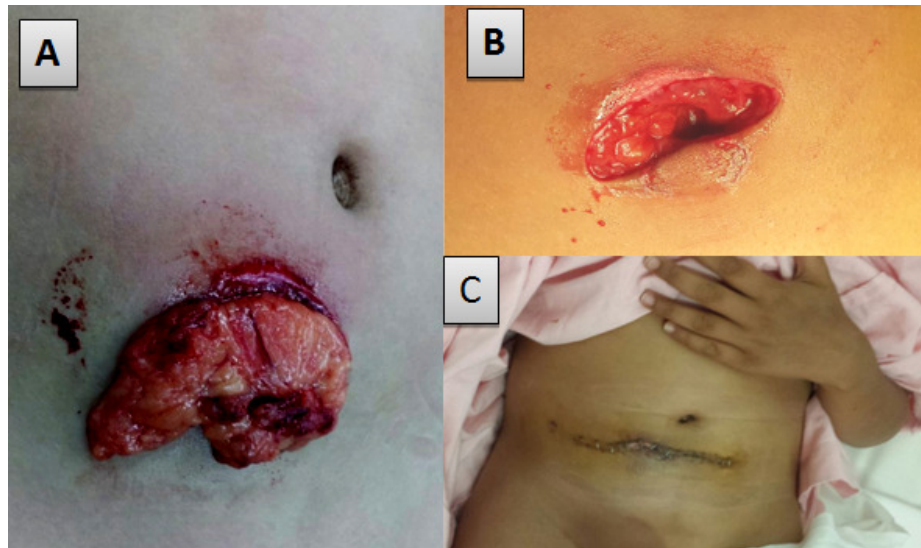

Figure 1. (A) Evisceration of omentum (B) Abdominal wall defect after reduction of eviscerated omentum (C) Surgical site on second post-operative day

Discussion

A child falling from a bicycle is a common scenario and can be regarded as a non-significant mechanism of injury with lateral falls as a low level of energy gets being distributed to a large area of the body or to an extremity. However, in the forward falls from a bicycle (as in our reported case the body gets struck in the torso against the bicycle handlebars (often bare or lacking protective equipment). The resultant focused impact over a small cross-sectional area, in combination with increased abdominal pressure as a result of the initial impact of the bicycle

creates a significant probability of injury to the abdominal wall and anterior viscera, including the liver, spleen, stomach, bladder, colon and small bowel³. Nadler et al⁴ compared the outcomes in children flipping from the bicycle over the handlebars (n = 160) with those sustaining direct impact from the handlebars (n = 61) and concluded that the children who suffered from handlebar injuries were more likely to require operative intervention (19/61 versus 28/160, p = 0.04) and had a statistically significantly longer length of hospital stay (3 days versus 1 day, p < 0.001). Cherniawsky et al⁵ in their retrospective analysis of 462 children admitted with bicycle related trauma, found the abdominal handlebar injuries in 9% of cases contributing to 19% of all internal organ injuries, and 45.4% of solid, 87.5% of hollow, 66.6% of vascular or lymphatic, and 100% of pancreatic injuries. They further postulated that the handlebar injuries were 10 times more likely to cause severe injury.

The injuries at times can manifest only with subtle clinical features and hence lead to delay in diagnosis and management, thereby increasing the morbidity and mortality^{5,6}. In the series by Cherniawsky et al, 50% of patients with handle bar injuries were misdiagnosed at their initial presentation. Winston et al⁷ studied the economic aspects of handlebar injuries in children and found that the estimated national costs in the United States associated with handlebar-related abdominal and pelvic organ injuries were \$9.6 million in total hospital charges, \$10.0 million in lifetime medical costs, \$11.5 million in lifetime productivity losses, and \$503.9 million in lifetime monetized quality-adjusted life-years.

Hence, it is stressed that the children reporting with an imprint or bruise made by the handlebar edge on the abdominal wall, or who present a clear history of injuries by a bicycle handlebar should be treated with utmost care³⁻⁶ and deemed as serious, until proven otherwise by proper evaluation, frequently repeated clinical examination and timely imaging. Prohibiting the use of bicycles with unpadding handlebars and requirements for safer handlebar designs with innovative soft padding like rubber handlebar helmets to avoid sharp cutting ends, may provide an avenue to prevent bicycle handlebar injuries primarily⁸ just as strategies and legislations for helmet utilization by bicyclists have proven to reduce the number of serious head injuries⁴.

References

1. Winston FK, Weiss HB, Nance ML, Vivarelli-O'Neill C, Strotmeyer S, Lawrence BA, Miller TR. Estimates of the incidence and costs associated with handlebar-related injuries in children. *Arch Pediatr Adolesc Med.* 2002; 156(9):922-8.
2. Minh Hung Nguyen, Adam Watson, Ed Wong. A 6-year-old boy presenting with traumatic evisceration following a bicycle handle bar injury: a case report. *Cases J.* 2009; 2: 6315.
3. Karaman I, Karaman A, Aslan MK, Erdogan D, Cavusoglu YH, Tutun O. A hidden danger of childhood trauma: bicycle handlebar injuries. *Surg Today.* 2009; 39(7):572-4.
4. Nadler EP, Potoka DA, Shultz BL, Morrison KE, Ford HR, Gaines BA. The high morbidity associated with handlebar injuries in children. *J Trauma.* 2005; 58(6):1171-4.
5. Cherniawsky H, Bratu I, Rankin T, Sevcik WB. Serious impact of handlebar injuries. *Clin Pediatr (Phila).* 2014; 53(7):672-6.
6. Lam JP, Eunson GJ, Munro FD, Orr JD. Delayed presentation of handlebar injuries in children. *BMJ.* 2001; 322(7297):1288-9.
7. Winston FK, Weiss HB, Nance ML, Vivarelli-O'Neill C, Strotmeyer S, Lawrence BA, Miller TR. Estimates of the incidence and costs associated with handlebar-related injuries in children. *Arch Pediatr Adolesc Med.* 2002; 156(9):922-8.
8. Clarnette TD, Beasley SW. Handlebar injuries in children: patterns and prevention. *Aust N Z J Surg.* 1997; 67(6):338-9.

Unusual Presentation of Invasive *Basidiobolus* mycosis as a Pelvic Mass in a 3-year-old Child: a Case Report

J. Trudea¹, G. Mwangi¹, J. Mathaiya², I. Githinji¹, C. Onyambu¹, E. Walong².

¹Department of Diagnostic Imaging and Radiation, University of Nairobi

²Anatomic Pathology Unit, Department of Human Pathology, University of Nairobi

Correspondence to: Dr. Mwangi Gladys, Email: gmwangi@yahoo.com

Background: Invasive fungal infection by agents of subcutaneous mycosis in immunocompetent patients is rare and therefore poses a diagnostic challenge. Zygomycosis is endemic in Africa, Asia and Latin America; but is rarely considered as a differential diagnosis in paediatric pelvic masses due to its non-specific clinical presentation and absence of established predisposing factors. This case report aims at increasing the clinical suspicion of this condition which leads to timely patient management.

Case Report: We present a case of a 3 ½ year-old boy who was referred to a tertiary teaching hospital in Kenya with what was thought to be a peri-anal abscess not responding to antibiotic treatment. Imaging studies revealed an infiltrating pelvic mass whose imaging features mimicked pelvic paediatric malignancies. The eventual diagnosis on histopathology was invasive zygomycosis caused by *Basidiobolus* species. The patient succumbed to the illness and autopsy confirmed the diagnosis.

Conclusion: Diagnosis of invasive zygomycosis requires a high index of suspicion. Clinical, radiological and pathological correlation is required for timely diagnosis and management. There are no reliable radiological features that distinguish these lesions from other paediatric malignancies.

Introduction

There are less than 1000 proven cases of invasive zygomycosis worldwide¹. Most of these cases have been reported within the last two decades, indicating its significance as an emerging disease^{2,3}. Since the microorganism is acquired through inhalation; paranasal sinuses and lungs are affected in a majority of cases (39% and 24% respectively)². Other systems affected are the skin (19%) and the gastrointestinal tract (7%)². Whereas there are few case reports of osteomyelitis and endocarditis; there has been no report of pelvic zygomycosis¹.

Zygomycosis is a group of filamentous fungi which consist of two orders, the *Mucorales* and the *Entomophthorales*². *Mucorales* are characterised by an acute angioinvasive infection in immunocompromised patients². *Entomophthorales*, which include *Conidiobolus* and the more common *Basidiobolus* species, is characterised by a chronic non-angioinvasive, subcutaneous infection of the thigh, buttock or trunk in immunocompetent individuals¹.

In East Africa, a review of 80 cases of zygomycosis (then referred to as phycomycosis) was performed in Uganda in 1976, which showed that 76% to 88% of the patients were less than 10 years of age⁴. In the review, the peculiar distribution of the disease was attributed to the use of 'toilet leaves' following defecation^{4,5}. *Basidiobolus ranarum* is found in decaying plant material, leaves of deciduous trees and soil within tropical and subtropical areas^{1,4}. We report a unique

case of pelvic basidiobolomycosis which mimicked a pelvic embryonal tumour in a Kenyan infant and presented a clinical and radiological diagnostic dilemma.

Case Report

A 3 ½ year-old boy was referred to a tertiary teaching hospital from a county hospital in Kenya with a peri-anal abscess of one-month history not responsive to antibiotic treatment. There was no history of fever, trauma, bowel or urinary symptoms. On physical examination, he was found to be normal in height and weight for age and afebrile. He had a soft, non-distended abdomen with no palpable mass. There was a warm, tender, perianal swelling which was discharging pus and inguinal lymphadenopathy. The child was immunocompetent. Surgical incision and drainage of the peri-anal abscess had been performed and intravenous metronidazole and ceftriaxone administered with no clinical improvement.

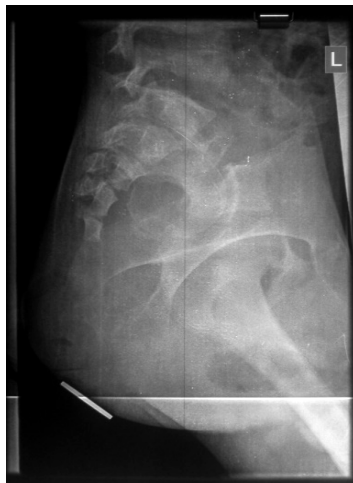

Figure 1. Lateral plain pelvic radiograph showing a soft tissue mass antero-inferior to the sacro-coccygeal bones. Visualized pelvic bones and femur are intact. (Radio-opaque marker on anal orifice)

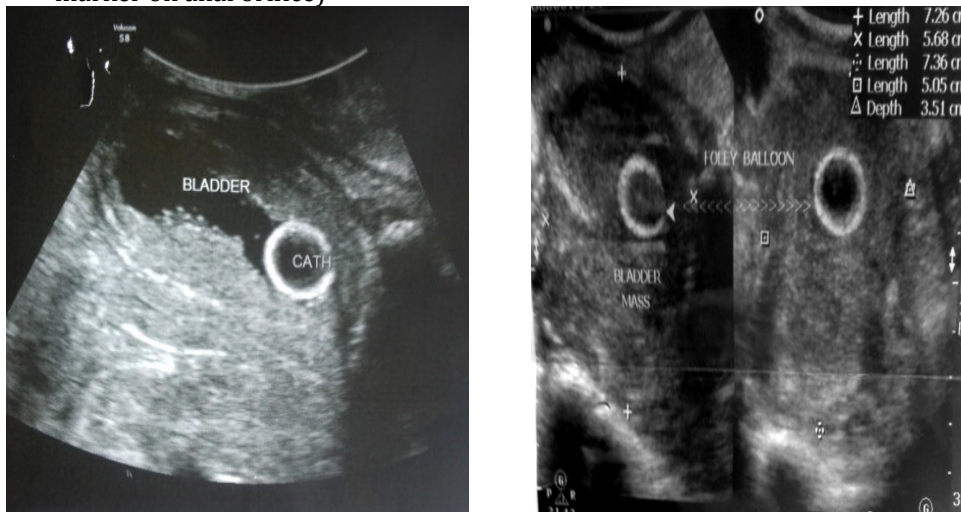


Figure 2A. Ultrasound images showing an isoechoic pelvic mass infiltrating the bladder and causing bladder wall thickening. Ballooned Foley’s catheter is seen in situ.

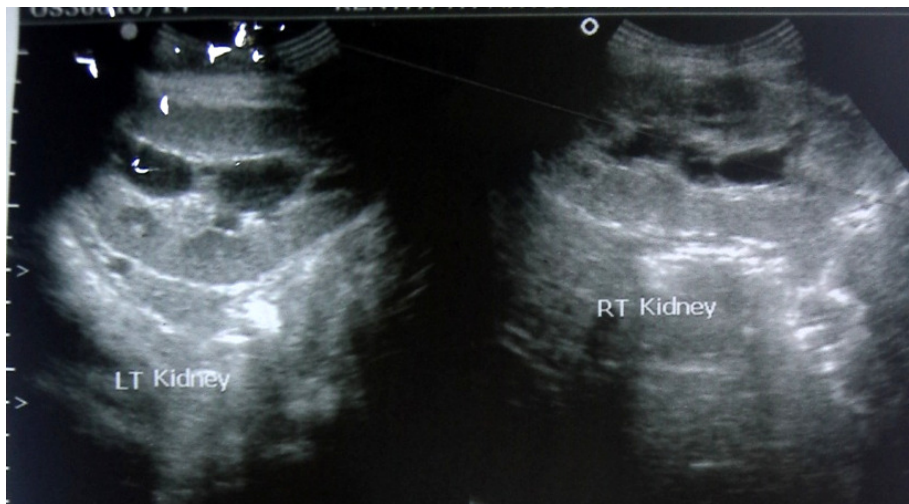


Figure 2B. Ultrasound images of the kidneys showing bilateral hydronephrosis more prominent on the left.

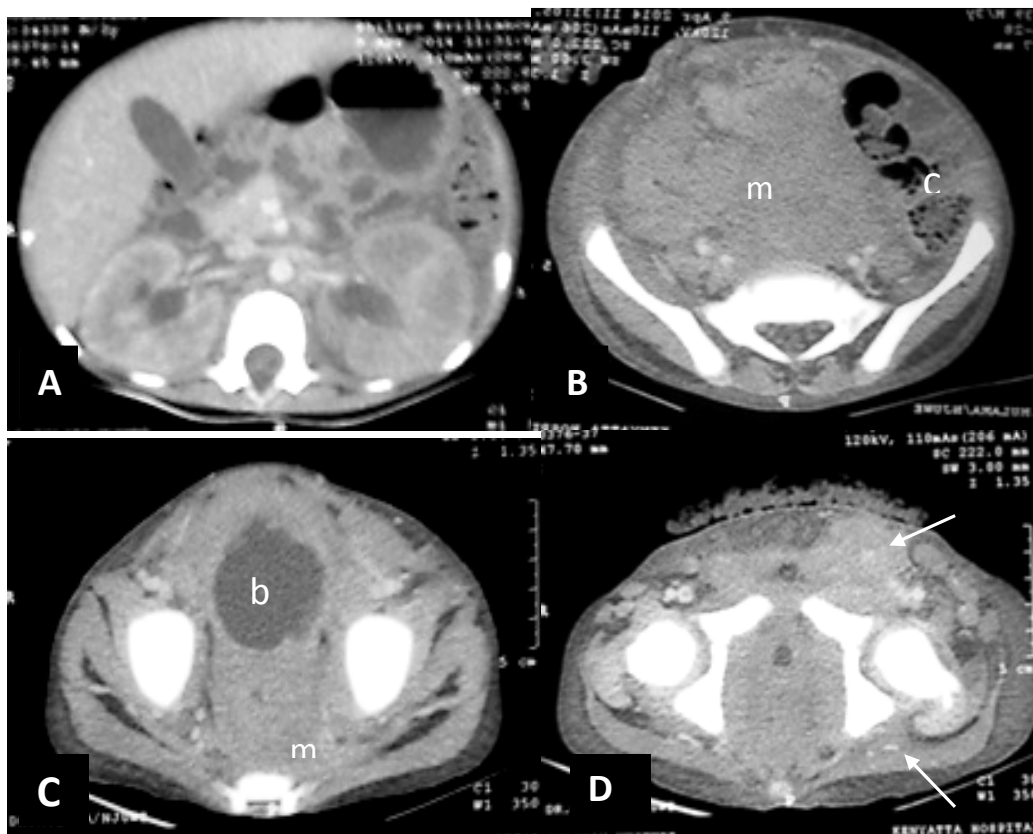


Figure 3. Axial contrast enhanced CT scan images of the abdomen and pelvis. A) Bilateral hydronephrosis left more than right. B) Large heterogeneously enhancing mass (m) in the pelvis displacing adjacent sigmoid colon (c). C) Mass surrounding the urinary bladder (b) and involving its wall. The mass (m) surrounds and involves the rectum. D) The mass is seen to extend to the left inguinal region and left gluteal region (arrows) with associated bilateral inguinal lymphadenopathy.

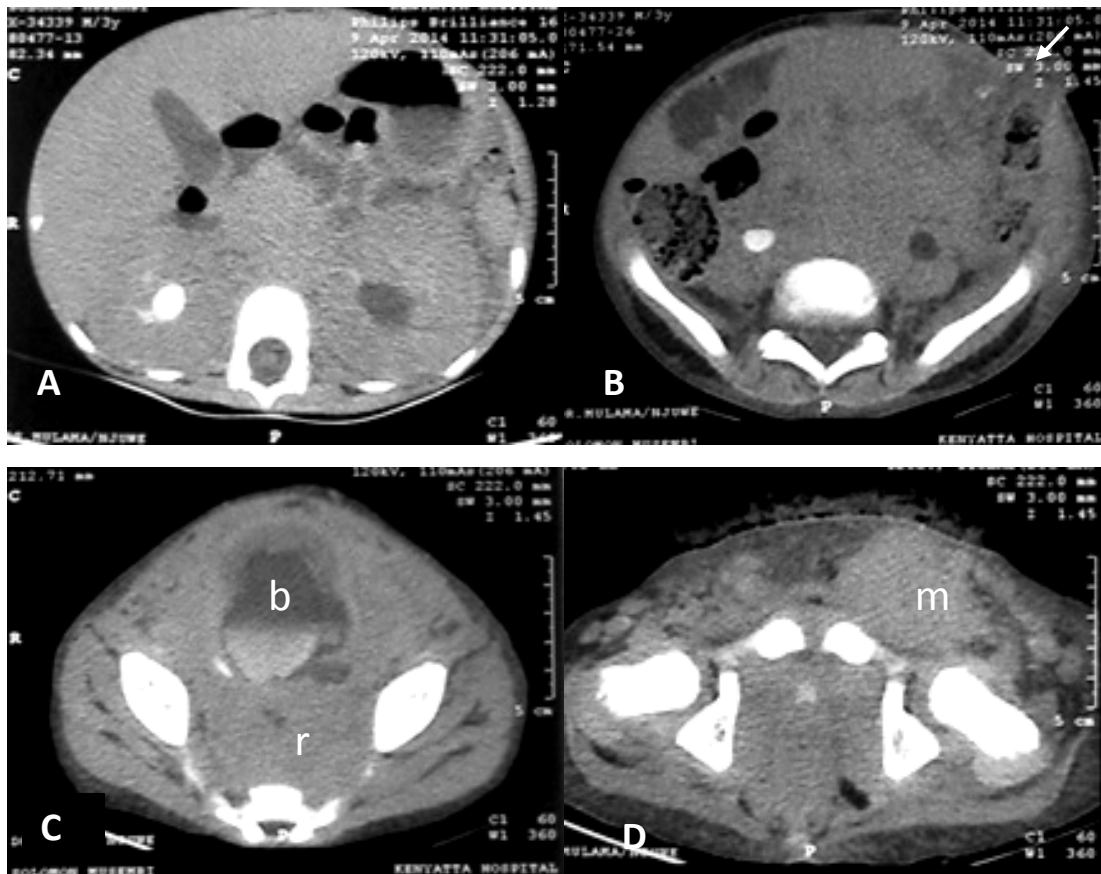


Figure 4: Axial contrast enhanced CT scan images of the abdomen and pelvis in the delayed phase. A) Bilateral hydronephrosis with excretion from the right kidney, as evidenced by contrast media in the dilated right renal pelvis. No contrast excretion noted from the left kidney. B) The large, ill-defined pelvic mass is seen surrounding the dilated ureters. The colostomy site noted, on the left anterior abdominal wall (arrow). C) The mass is seen to surround and involve the urinary bladder (b) and rectum(r). D) The mass (m) extends into the left adductor compartment. There is bilateral inguinal lymphadenopathy

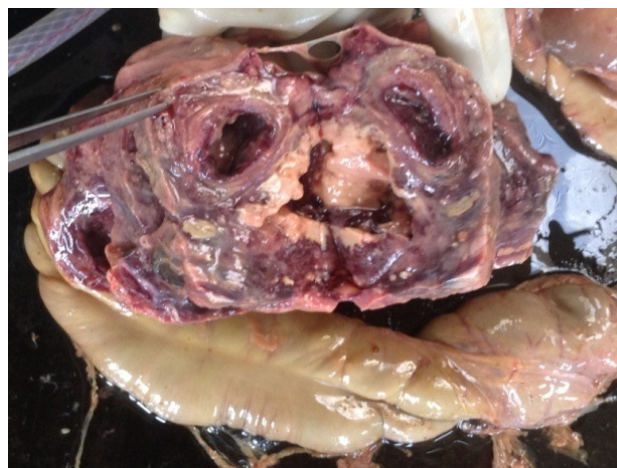

Figure 5: Gross photograph of the pelvic organs and large intestines showing an infiltrating mass engulfing the urinary bladder with relative sparing of the colon. The mass involves the

rectal and bladder serosa. There is no evidence of intestinal obstruction or vascular involvement.

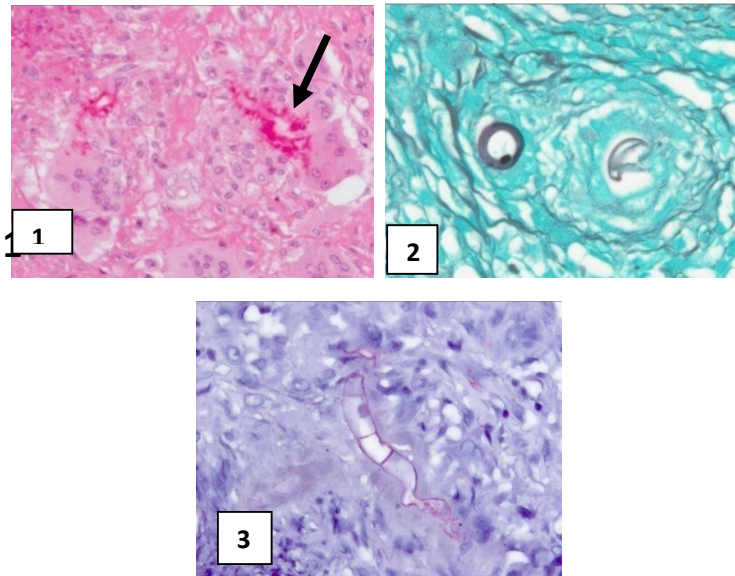


Figure 6. Photomicrographs of histological sections of the pelvic mass: Image 1 (Haematoxylin and Eosin) shows chronic granulomatous inflammation with multinucleated giant cells and fungal hyphae. The arrow shows the Splendore-Hoeppli phenomenon. Image 2 (Grocott's Methenamine Silver) shows fungal hyphae with characteristic dark staining of the fungal cell wall. Image 3 (Immunohistochemistry, polyclonal anti *Basidiobolus* immunohistochemistry) confirm the genus of the fungal hyphae.

Laboratory findings at the tertiary hospital revealed haemoglobin level of 9.78g/dl, peripheral blood leucocytosis of $32.2 \times 10^9/L$, neutrophilia (74.1% on differential counts) and thrombocytosis ($744 \times 10^9/L$). There was no evidence of peripheral blood eosinophilia. Chest radiograph was unremarkable and a pelvic AP and lateral radiograph showed an ill-defined soft-tissue density mass overlying the sacrum. A subsequent ultrasound examination showed a large ill-defined soft tissue mass filling the rectovesical pouch and enclosing the urinary bladder. There was thickening of the bladder wall, bilateral hydronephrosis and hydroureter. The liver, gall bladder, pancreas and spleen were normal. There was no para-aortic adenopathy. An infiltrating pelvic malignancy was suspected, rhabdomyosarcoma being the most likely diagnosis.

Surgical drainage of the peri-anal abscess and an incisional biopsy was re-attempted and an indurated cutaneous lesion was found, there was no pus. Incision biopsies of the cutaneous lesion as well as an excision biopsy of the inguinal lymph nodes were submitted to the laboratory for histopathology. A few days later however, the child developed intestinal obstruction. This required surgical management, a sigmoid colostomy was fashioned.

Abdominopelvic CT scan using water for oral contrast and iodinated non-ionic water-soluble intravascular contrast was performed. There was a large ill-defined, infiltrating soft tissue mass with heterogeneous contrast enhancement, occupying the entire pelvic cavity and engulfing the urinary bladder and rectum. The bladder wall was markedly thickened. The adjacent pelvic walls were infiltrated and the lesion extended into the left ischio-rectal fossa, gluteal and adductor compartments. There was associated inguinal lymphadenopathy, bilateral

hydronephrosis and hydronephrosis; more severe on the left than the right. No ascites or intra-abdominal adenopathy was seen. The liver, gall-bladder, spleen, adrenals and pancreas were normal. There was no skeletal involvement.

During the post-operative period, the child developed high-grade fever. Repeat peripheral blood counts showed worsening anaemia (7.95g/dl), leucocytosis ($25.3 \times 10^9/L$ with a neutrophilia of 72.6%) and thrombocytosis ($501 \times 10^9/L$). Urinalysis was positive for nitrite-positive *Klebsiella* which was sensitive to meropenem. He received antibiotic therapy but unfortunately succumbed due to sepsis.

Histopathology of the perianal mass biopsy was reported as a pilonidal sinus with no evidence of subcutaneous mycosis. Sections of the lymph node biopsy stained with haematoxylin and eosin, and Grocott's Methenamine Silver showed a non-necrotizing chronic granulomatous inflammatory lesion with foreign body type multinucleated giant cells and filamentous fungal hyphae.

At autopsy, a soft-tissue infiltrating abdominal-pelvic mass was found arising from the pelvic floor, sacra-coccygeal and pubic region, and extending to the abdominal aortic bifurcation. The mass engulfed the rectum and sigmoid, the iliac vascular channels, the periosteum of the ileum and the pelvic fascia. Kidney sections demonstrated hydronephrosis and hydronephrosis. Further histopathological analysis of the mass confirmed the presence of the filamentous fungal hyphae. Polyclonal immunohistochemistry (IHC) and polymerase chain reaction (PCR) confirmed infection by *Basidiobolus spp.*

Discussion

In this case report, the young male patient presented with perianal subcutaneous mycosis and a pelvic mass, which extended to involve the pelvic floor, pelvic wall, rectum and urinary bladder. The clinical symptoms and signs were nonspecific, leading to initial consideration of perianal abscess. On imaging, the mass mimicked an embryonal rhabdomyosarcoma. However this was revealed on histopathology as a chronic infection by *Basidiobolus spp.* This is the first report of basidiobolomycosis in a child whose presentation is a pelvic mass.

Basidiobolomycosis presents as painless erythematous firm subcutaneous plaques⁵. There may be skin ulceration, lymphadenopathy and non-pitting oedema of the involved limb⁴. Visceral involvement is rare and has been reported in the gastrointestinal tract where it presents with trans-mural thickening, intimal nodules and ulceration resembling Crohn's disease or gastrointestinal malignancies^{3,6}. In the case presented, there was involvement of the skin, subcutaneous tissue and peri-pelvic fascia with encasing of the pelvic viscera.

According to the majority of case reports, subcutaneous and invasive basidiobolomycosis is associated with anemia, eosinophilia, elevated IgE, elevated ESR and thrombocytosis^{6,7}. In this case, there was no evidence of peripheral blood eosinophilia, which contributed to the diagnostic dilemma. Untreated zycomycosis infection is associated with 100% mortality rate³.

Zygomycosis is diagnosed by identifying its characteristic morphology on tissue biopsy where it induces a non-necrotizing granulomatous chronic active inflammation⁵. Surrounding the hyphae is a dense eosinophilic infiltrate and the Splendore-Hoeppli reaction^{5,7}. Molecular techniques are used in combination with morphology because, unlike culture, they are rapid, precise and accurate⁷. Applying Polymerase Chain Reaction (PCR) in addition to morphology using routine, special and immunohistochemical stains, we can confirm that the fungus is *Basidiobolus sp.*

Conclusion

This is the first report of pelvic basidiobolomycosis. It mimicked malignant disease and lacked peripheral blood eosinophilia. Delayed diagnosis was due to a low index of suspicion and non-specific radiological features. Clinical, radiological and pathological correlation is required for timely diagnosis and management of this disease.

Acknowledgments

Prof Emily Rogena, Department of Pathology, University of Nairobi), Dr Sherif Zaki (Division of High Consequence Pathogens, CDC), Dr Fazzal (Pediatric Surgery Resident University of Nairobi)

References

1. Roden M, Zaoutis T, Buchanan W, et al. Epidemiology and outcome of Zygomycosis: A review of 929 reported cases. *Clinical Infectious Diseases*. 2005; 41: 634-653.
2. Bittar D, Van-Cauteren D, Lauternier F, et al. Increasing Incidence of Zygomycosis (Mucormycosis) in France, 1997-2006. *Emerging Infectious Diseases*. 2009.
3. Geramizadeh B, Foroughi R, Keshtkar-Jahromi M, et al. Gastrointestinal Basidiobolomycosis, an emerging infection in the immunocompetent host, a report of 14 patients. *Journal of Medical Microbiology*. 2012; 61 (12):1770-1774.
4. Mugerwa J. Subcutaneous phaeohyphomycosis in Uganda. *British Journal of Dermatology*. 1976; 94:539-544.
5. R, Kontoyiannis D and Lewis. Agents of Mucormycosis and Entomophthoromycosis. [book auth.] Bennet J and Dolin R Mandel G. [ed.] 7th. Principles and practice of Infectious Diseases. Philadelphia : Churchill Livingstone, 2010, pp. 3257-69.
6. Hussein M, Mahmoud R. Mucocutaneous Splendore-Hoeppli phenomenon. *Journal of Cutaneous Pathology*. 2008; 35:979-988.
7. Zabolinejad N, Naseri A, Davoudi Y et al. Colonic Basidiomycosis in a child: Report of a culture proven case. *International Journal of Infectious Disease*. 2014; 22: 41-43.
8. Vikram H, Smillac J, Leighton J, et al. Emergence of Gastrointestinal Basidiolomycosis in the United States, with a review of worldwide cases. *Clinical Infectious Disease*. 2012; 54 (12): 1685-1691.