

Evaluation of the Outcome of Femoral Plate Osteosynthesis in a Teaching Hospital in a Developing Country.

O.J. Ogundele¹, A.I. Ifesanya¹, A.A. Fakoya², T.O. Alonge¹.

¹Department of orthopaedics and Trauma, University College Hospital, PMB 5116, Ibadan, Oyo state, Nigeria.

²Department of surgery, University College Hospital, PMB 5116, Ibadan, Oyo state, Nigeria.

Correspondence to: O.J. Ogundele, Email: ogunjosh@yahoo.com or ogunjosh128@gmail.com.

Background: Fractures of the femur are a common presentation of traumatic injuries and are usually associated with other injuries. The need for surgical fixation is undisputed although operative options are varied, and often the choice is based on fracture pattern, available facilities and the surgeon's preference. This decision should be determined by the predicted functional outcome rather than by the type of implant to be used. The objective of this study was to evaluate the results of treatment of femoral shaft fractures using plate osteosynthesis in our centre.

Method: This was a retrospective study done by reviewing the medical records of patients presenting with femoral shaft fractures between 2005 and 2012.

Results: A total of two hundred and four patients underwent plate osteosynthesis of femoral shaft fractures within the period under consideration. One hundred and seventy (83.3%) patients achieved clinical and radiological union after an average of 5 months. There were 12 (5.9%) non-unions, 10 (4.9%) infected implants and 4 (2%) broken implants.

Conclusion: Plate osteosynthesis is vital in the management of femoral fractures especially in developing countries where the cost of care is entirely borne by the patients and relations. Careful patient selection and meticulous post-operative follow-up care are essential for a favourable outcome.

Introduction

The femur is the strongest, longest and heaviest bone in the body and is essential for ambulation. It is composed of 3 parts - the shaft or diaphysis, proximal and distal metaphyses. Several large muscles attach to the femur. Proximally, the gluteus medius and minimus attach to the greater trochanter, resulting in abduction of the femur when there is a fracture. The iliopsoas attaches to the lesser trochanter, resulting in internal rotation and external rotation following fractures. The linea aspera (the rough line on the posterior surface of the femoral shaft) reinforces the strength and serves as an attachment for the gluteus maximus, adductor magnus, adductor brevis, vastus muscles, and the short head of the biceps femoris. Distally, the large adductor muscle mass attaches medially, resulting in an apex-lateral deformity after femoral fractures. The medial and lateral heads of the gastrocnemius attach to the posterior femoral condyles, resulting in flexion deformity in distal-third fractures.¹

The blood supply enters the femur through metaphyseal arteries and branches of the profunda femoris artery, penetrating the diaphysis and forming medullary arteries extending proximally and distally. Healing of femoral fractures is enhanced by the surrounding soft tissue and local recruitment of blood supply around the fracture site.^{1,2}

The scope of femoral fracture is wide and generally high energy forces are involved with multi-system trauma in majority of the cases. There is usually associated significant soft tissue injury and severe comminution.³ Causes of femoral fractures include motor vehicular trauma such as

auto crashes, motorcycle crashes, pedestrian traffic injuries, run-off the road traffic injuries, gunshots and falls etc. Isolated femoral fractures also occur in patients with metabolic bone diseases, primary and secondary bone tumours and repetitive stress. Injury mechanism and age distribution is also known to follow a bimodal distribution.⁴

High energy injuries cause fractures in young adults, usually road traffic crashes and gunshots. Low energy injuries are known to occur commonly in the elderly and are due to falls and usually have a local or general factor weakening the mechanical strength of the bone.⁵

The femur is very vascular and fractures can result in significant blood loss into the thigh. Up to 40% of isolated fractures may require transfusion as up to 3 units of blood may be lost. This is significant especially in the elderly who have a reduced cardiovascular reserve. The risk of vascular injury is also high and this further increases the requirements for blood transfusion.⁶

About 420 open reduction and internal fixations are done annually at our centre, a 1000-bed teaching hospital in Nigeria.

Patients and Methods

This is a retrospective study to evaluate the results and effectiveness of plate osteosynthesis of femoral fractures in our centre. Two hundred and four patients who had open reduction and internal fixation for femoral fractures in our hospital between 2005 and 2012 were recruited into this study.

Our operating theatre diaries were reviewed and all the cases of plate osteosynthesis of the femoral shaft carried out during the period under consideration were extracted. The case records were then pulled out from the records department. Information about age, gender, fracture classification, sites of the fracture, energy transfer, associated injury, cause of fracture, time spent in hospital before surgery, outcome of treatment, complications and the number of units of blood transfused were extracted from their medical records.

The data obtained was transferred to a computer spreadsheet and analyzed using the Statistical Package for the Social Sciences (SPSS Inc.) version 17.0. Categorical data were compared using the Chi squared test, a p value of 0.05 was regarded as significant. Continuous variables were expressed as mean \pm SD (standard deviation).

Results

A total of two hundred and four patients who underwent plate osteosynthesis of femoral shaft fractures within the period under consideration were recruited into the study. There were one hundred and seventeen (57.4%) males and eighty-seven (42.6%) females in a ratio of 1.4:1. The ages of the patients ranged from 7 to eighty-five years (mean age = 34.1 ± 13.8 years). The age distribution of the patients is shown in figure 1. One hundred and eighty-one (88.7%) patients had closed fractures while twenty-three (11.3%) had open fractures. Details are presented in figure 2. One hundred and ninety (93.1%) patients were involved in high energy injuries.

Motor-vehicular crashes were responsible for one hundred and twenty-two (59.8%) cases and motorcycle crashes for sixty-one (29.9%). Others include gunshots (3.4%) and falls (6.9%). This is shown in figure 3. The mean number of days spent in the hospital before surgery was approximately 4.0 ± 5.9 days.

One hundred (40%) patients had blood transfusions. Eight (3.9%) patients had three units of blood while eighteen (8.8%) had two. Seventy-four (36.3%) patients had one unit of blood each.

The blood transfusions were preoperative, intraoperative or post operative depending on their haemoglobin concentration and packed cell volumes. One hundred and twenty-eight (62.8%) patients had associated injuries which include head injuries, facial fractures, foot gangrene, pelvic fractures, cervical and thoracic spine injuries, chest injury, humeral and tibia fractures and blunt abdominal injuries. Seventy-six (37.3%) patients did not have associated injuries. Details are presented in Figure 4.

One hundred and eighty-one (88.7%) of the fractures occurred at the mid-shaft, 13 (6.4%) at the distal third, 7 (3.4%) at the proximal third while 3 (1.5%) were segmental.

One hundred and fifty nine (78%) patients had open reduction and internal fixation (ORIF) with broad dynamic compression plates (BDCCP), 19 (9.3%) patients had angled blade plating while 7 (3.4%) had ORIF with narrow dynamic compression plates (NDCP). Ten (4.9%) had internal fixation with condylar blade plate while 8 (3.9%) had condylar buttress plating. One patient (2.5%) had Jewett nail plating.

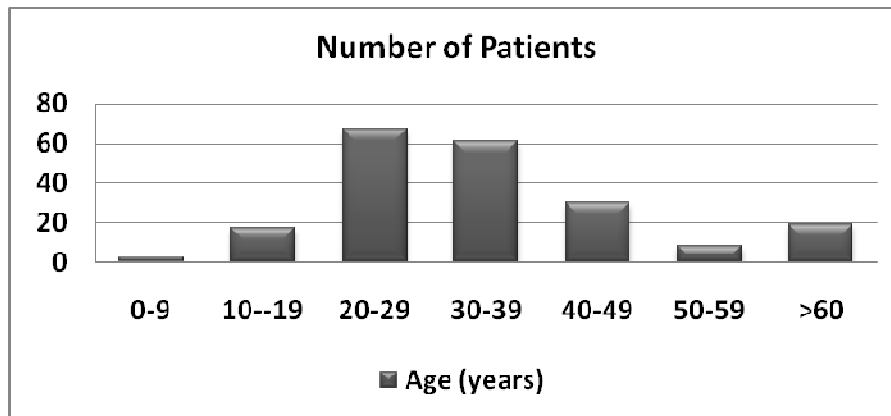


Figure 1. Age distribution of patients who had plate osteosynthesis for femoral shaft fractures

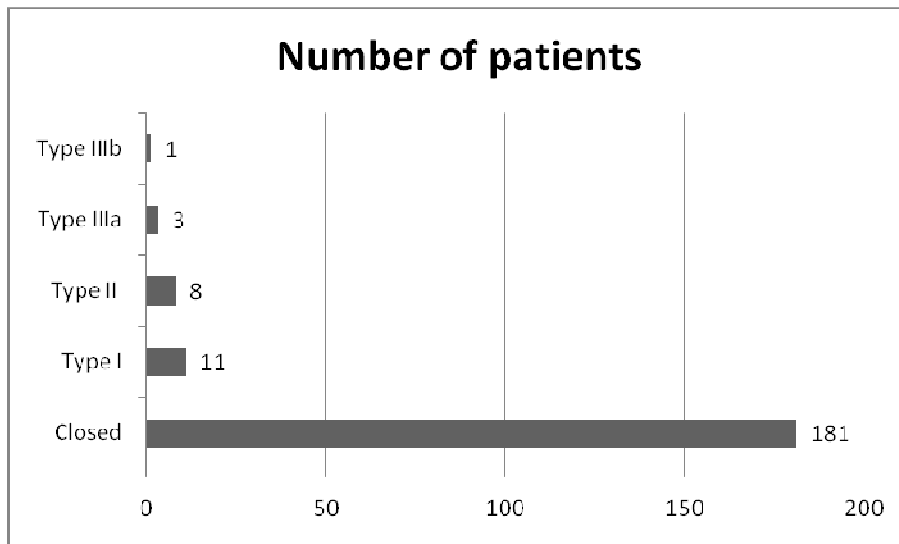


Figure 2. Classification of femoral shaft fractures operatively treated by plate osteosynthesis according to the severity of the open injury

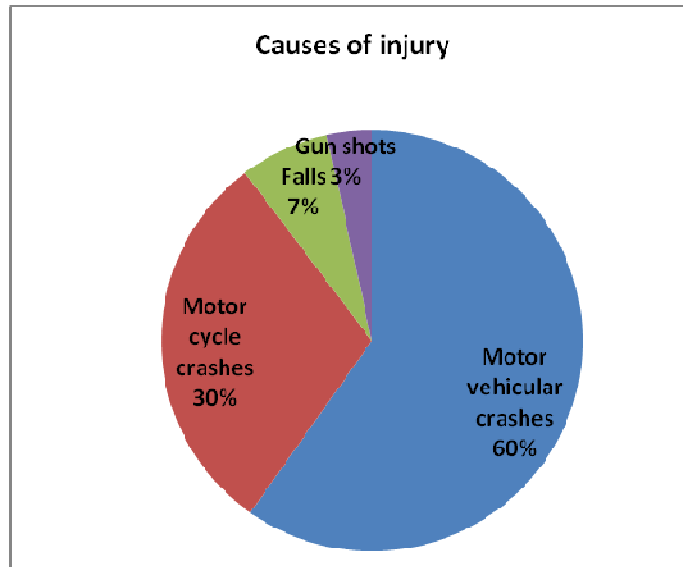


Figure 3. Causes of injury in patients who had plate osteosynthesis for femoral fractures

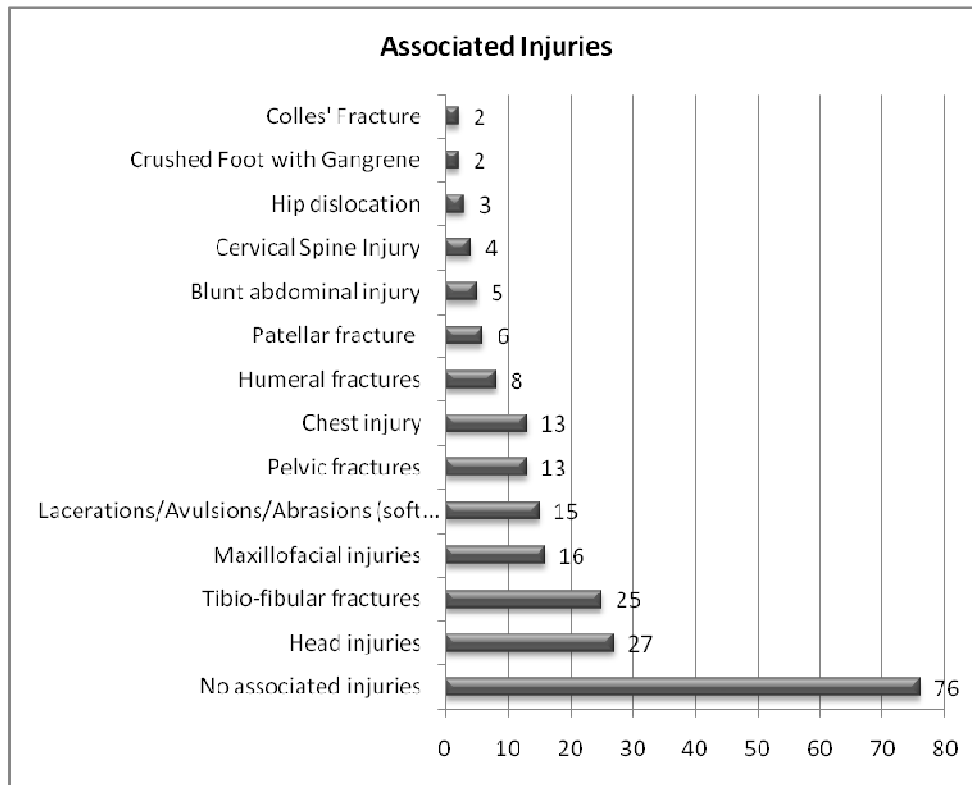


Figure 4. Associated injuries in patients who had plate osteosynthesis for femoral shaft fractures

Table 1. Outcome of treatment of patients who had plate osteosynthesis for femoral shaft fractures

Outcome of treatment	Number of patients
Clinical and radiological union	170 (83.3%)
Non union	12 (5.9%)
Infected implants	10 (4.9%)
Broken implants	4 (2.0%)
Discharge against medical advice	1 (0.5%)
Referral to another hospital	1 (0.5%)
Lost to follow-up before union	2 (1.0%)
Joint stiffness	4(2.0%)
Total	204(100.0%)

One hundred and seventy (83.3%) patients had clinical and radiological union of their fractures while 12 (5.9%) had non-unions. Ten (4.9%) had infected implants and 4 (2.0%) broken implants. The outcome of treatment could not be ascertained in 4 patients. Two of these patients were lost to follow-up, one was referred to another hospital for proximity to relations while another discharged against medical advice. Details are presented in table 1.

Treatment modalities for the associated injuries include external fixation of open fractures, craniotomy, dynamic compression plating with or without bone grafting for tibio-fibula fractures, exploratory laparotomy, below knee amputation for crush injuries of the foot, closed thoracostomy tube drainage and suturing of lacerations.

Discussion

The scope of femoral fracture is wide and generally high energy forces are involved with multi-system trauma in majority of the cases.^{3, 7} Femoral fractures followed a bi-modal age distribution in this study with peak age at 20-29years and above 60years which is similar to the report by Taylor et al.^{4, 8} The diagnosis of femoral shaft fractures is made straight-forward by the presence of such clinical signs as axial deviation, shortening, abnormal function and pain. An assessment of soft-tissue damage is an integral part of every clinical examination. Open fractures are less common because of the dense soft-tissue cover around the femur. Only 11% were open fractures in this study. Lacerations of the muscle layers, however, can be present and subcutaneous de-gloving injuries should not be overlooked despite an intact integument. Assessment of neuro-vascular functions is also mandatory.⁹

A number of studies have supported early aggressive surgical management of the patient with multiple injuries and long bone fractures. A strong relationship exists between early fixation of femoral fractures and reduction in the number of days in the intensive care unit, the number of days in hospital, and the incidence of adult respiratory distress syndrome, pneumonia, infection and death.¹⁰ In this study, most cases (62.8%) were operated within 2days of presentation in the hospital. Those who had longer pre-operative stay were delayed either because of lack of theatre slots or associated life threatening injuries which had to be taken care of before plate osteosynthesis. Studies in the 1960's and 1970's by Charnley, Guindy and Wilber, suggested that fractures operated on early (within 0-6 days after fracture) when compared to those operated

on late (after more than 6 days) had a higher incidence of non-union, delayed union and re-fracture. Modern day studies have refuted these claims and show no benefit from delaying surgery.¹¹

Standard x-ray examinations consist of views in two planes. Adjacent joints must be included so that ipsilateral fractures of the femoral neck or tibia plateau are not missed. A femur fracture in a young individual is always the consequence of a considerable trauma and may involve other injuries. More extensive examinations are required in the polytrauma patient or if concomitant injuries to the pelvis, spine or knee joints are suspected, since such additional injuries will affect treatment.^{9, 12} Known associated injuries with femoral fractures are vascular injuries, nerve injuries, ipsilateral femoral neck fractures, knee injuries and tibia fractures.¹² Head injury was the commonest associated injury in this study occurring in 27(13.2%) patients. This is closely followed by tibio-fibula fractures 25 (12.3%) and maxillofacial injuries which occurred in 16(7.8%) patients. Others include cervical and thoracic spine injuries with paraplegia, chest injuries, 2(1%) foot injuries with resultant gangrene etc.

The current favoured treatment of femoral shaft fractures is with statically locked reamed intramedullary nailing.¹³ Alternatives include traction with or without cast bracing, plate osteosynthesis and external fixation. The principles of anatomical reduction and stable fixation of femoral shaft fractures followed by early limb rehabilitation have gained widespread acceptance. Dissatisfaction with the results of non-operative treatment of femoral shaft fractures, because of prolonged hospitalization, high costs, fracture shortening, malunion, delayed union and joint stiffness has led to the development of various operative techniques for the management of femoral shaft fractures.

Plate osteosynthesis is an important technique which is advantageous in situations where intramedullary nailing is not ideal and in resource poor settings like ours where it is relatively cheaper and facilities for intramedullary nailing are either not readily available or the functionality cannot be guaranteed as a result of technical faults or incessant power outages. All implants are out-of-pocket expenses by the patients and/ or the relations. Other reasons why plating may be favoured over intramedullary nailing include adult and paediatric polytrauma with concomitant head trauma or pulmonary compromise, ipsilateral femoral neck and shaft fractures, Open fracture with a vascular injury where exploration is mandatory, fracture location in the proximal or distal femoral shaft and excessively narrow intramedullary canals.¹⁴

The principles of accurate reduction and stable internal fixation of femoral fractures with plates should be followed. The commonly used implants for plate osteosynthesis in our center includes broad dynamic compression plates(BDCP), narrow dynamic compression plates(NDCP), Jewett nail plates, angled blade plates, condylar blade and buttress plates. This study shows the dwindling popularity of Jewett nail plate in our centre as in most parts of the world.

Despite the improvements in anatomical reduction, earlier mobilization, decreased pulmonary morbidity and earlier discharge from hospital, plating is associated with it an array of complications which range from non-union, infected and broken implants and joint stiffness.¹⁵ The problem of knee movement has not been completely addressed. This is a bit skewed in that plating is more likely to be used in the distal third fractures where knee movement is more likely to be affected.^{15,16} Malunion, infection, mechanical failure of fixation, delayed union, non-union, re-fracture and re-operations are all possible complications following plate fixation of femoral fractures. Accurate open reduction and plate fixation requires considerable experience

and operative expertise to ensure satisfactory results. Recent evolution in plating techniques has led to the concepts of careful tissue dissection, epiperiosteal exposure of bone, and indirect reduction of fractures to minimize stripping and devascularization of bone fragments. Reduced soft tissue dissection also leads to less quadriceps tethering and improved knee range of motion. Reduction of the fracture to achieve anatomic alignment of intra-articular fractures and optimal rather than maximal stability is the goal.^{14,16} Routine bone grafting of the medial cortical defect as advocated in the 1980's by Loomer et al¹⁶ is no longer advocated, however in situations where there is extensive fracture comminution with devascularization of fragments primary bone grafting is strongly advised.^{14,17} Longer plates relative to the fracture length are thought to be particularly important, increasing the lever arm of the plate. Optimal use of screws through the plate as opposed to maximal use of screws the length of the plate has also been suggested.^{14,17} Loomer^{16,17} also reported on 45 patients who had plate osteosynthesis who had their fractures healed at 7 months, returned to work at 12 months and resumed sporting activities at 15 months. In this study the average interval before patients returned to work was 18 months. The disparity in time taken to return to work is due to the fact that some of the patients have severe associated injuries which kept them in bed longer and some elderly patients who took longer to commence ambulation.

Conclusion

Plate osteosynthesis is still a vital tool in the management of femoral fractures especially in developing countries where the cost of care is entirely borne by the patients and the relations.

Our results are comparable to those obtained from other centres around the world. Careful selections of cases as well as meticulous post-operative follow-up care are essential for a favourable outcome in the treatment of femoral shaft fractures with plate osteosynthesis.

References

1. Selvadurai N. Femoral shaft fractures. In: Gavin J, Francesca N, editors. Apley's system of Orthopaedics and Fractures. London: Hodder Arnold, 2010. p.859.
2. Bucholz R, Brumback R. Fractures of the shaft of the femur. In: Rockwood C, Green D, Bucholz R et al, editors. Rockwood and Green's Fracture in Adults. Philadelphia: Lippincott-Raven, 1996.p.1827.
3. Oestern H, Tscherner H. Pathophysiology and classification of soft tissue injuries associated with fractures. In: Tscherner H, and Gotzen L, editors. Fractures with soft tissue injuries. Berlin: Springer Verlag, 1984. p. 1-9.
4. Hedlund R, Lindgren U. Epidemiology of diaphyseal femoral fracture. *Acta Scand orthop* 1986 Oct; 57(5):423-7.
5. Clement N, Aitken S, Duckworth A, McQueen M, Court-Brown C. Multiple fractures in the elderly. *J Bone and Joint surgery Br.* 2012 Feb; 94(2):231-6.
6. DiChristina D, Riemer B, Butterfield S et al. Femur fractures with femoral or popliteal artery injuries in blunt trauma. *J orthop trauma.* 1994; 8: 494-503.
7. Whittle AP, Wood GW II. Fractures of the lower extremity. In: Campbell's Operative Orthopaedics, 10th, Canale ST. (Ed), Mosby, St. Louis 2003. p.2825.
8. Taylor M, Banerjee B, Alpar E. The epidemiology of fractured femurs and the effects of these factors on outcome. *Injury.* 1994b; 25: 641-44.

9. Dankward H. Femur: Shaft (including subtrochanteric). In: Thomas R, William M, AO principles of fracture management. Chris L, Alberto F et al. Editors. Thieme Verlag 2000. p. 457.
10. Charash WE, Fabian TC, Croce MA. Delayed surgical fixation of femur fractures is a risk factor for pulmonary failure independent of thoracic trauma. *J Trauma*. 1994; 37:667-72.
11. Bone L, Johnson K, Weigelt J, Scheinberg R. Early versus delayed stabilization of femoral fractures. A prospective randomized study. *J Bone and Joint surg*. 1989; 71A: 336-40.
12. Taylor M, Banerjee B, Alpar E. Injuries associated with a fractured shaft of the femur. *Injury*. 1994; 25: 185-87.
13. Brumback R, Reilly J, Poka A, Lakatos R, Bathon G, and Burgess A. Intramedullary nailing of femoral shaft fractures. Part I: Decision-making errors with interlocking fixation. *J Bone and Joint Surg*. 1988; 70A: 1441-52.
14. Rozbruch S, Muller U, Gautier E, Ganz R. The evolution of femoral shaft plating technique. *Clin Orthop Relat Res*. 1998; 354: 195-08.
15. Geissler W, Powell T, Blickenstaff K, Savoie F. Compression plating of acute femoral shaft fractures. *Orthopedics* 1995;18:655-60
16. Loomer RL, Meek R, DeSommer F. Plating of femoral shaft fractures: the Vancouver experience. *J Trauma*. 1980; 20:1038-42.
17. Rüedi T, Lüscher J. Results after internal fixation of comminuted fractures of the femoral shaft with DC plates. *Clin Orthop Relat Res*. 1979; 138:74-6.