

Testicular torsion in Ethiopia: a case series and systematic review of the sub-Saharan African literature

M. Derbew¹, A.D. Laytin²

¹Addis Ababa University School of Medicine

²University of California San Francisco

Correspondence to: Miliard Derbew, Email: miliardderbew@gmail.com

Background: We report on the presentation, clinical course and outcome of patients with testicular torsion in Addis Ababa, Ethiopia to identify opportunities for improved care.

Methods: A retrospective review of clinical records of patients with testicular torsion presenting to a hospital with pediatric surgical expertise in Addis Ababa, Ethiopia in 2012-4 was performed and analyzed descriptively. A systematic review of published literature about testicular torsion in sub-Saharan Africa between 1990-2014 was performed using the PubMed and African Journals Online databases.

Results: Seven patients aged 5 days to 18 years were diagnosed with testicular torsion, six with acute symptoms and one with chronic, intermittent symptoms. The most common symptoms were scrotal swelling and unilateral pain. In 4/6 acute cases, surgical consultation was delayed to obtain color Doppler ultrasound. In 5/6 cases, including all in which ultrasound was obtained, the testis was nonviable, requiring orchiectomy. Thirteen studies reported on testicular torsion in sub-Saharan Africa in the past 25 years.

Conclusions: Testicular torsion remains an under-appreciated surgical emergency in Ethiopia. Delays in presentation and diagnosis contribute to high levels of testicular loss. A high index of suspicion is warranted, and surgical consultation should not be delayed to obtain ultrasound confirmation in this setting.

Introduction

Testicular torsion is a common cause of acute scrotal pain, accounting for acutely presenting scrotal symptoms in 90% of post-pubescent boys and 30% of pre-pubescent boys¹. The condition is a surgical emergency, as prolonged ischemia results in testicular necrosis². However, timely surgical intervention with detorsion and bilateral orchiopexy resulted in a salvage rate of 68% in the United States³.

Color Doppler testicular ultrasound has been widely advocated as a diagnostic adjunct to confirm the presence of torsion^{4,5}. However, there has been little research to assess the prevalence of testicular torsion in sub-Saharan Africa, or the appropriateness testicular ultrasound as a diagnostic technique in this setting. Delaying surgical consultation and intervention to obtain ultrasound imaging in the absence of emergency department physicians with ultrasound expertise may contribute to potentially avoidable testicular necrosis. This study was aimed at investigating the presentation, clinical course and outcome of patients with testicular torsion presenting to one of the few private hospitals with pediatric surgical expertise in Ethiopia to determine current practices and identify sources of delay that may contribute to poor outcomes.

Patients and Methods

A retrospective review was performed of the medical records of all patients with final diagnosis of testicular torsion presenting to the emergency department of one of the few private hospitals with pediatric surgical expertise in Ethiopia, between January 1, 2012 and December 31, 2014. Clinical charts were retrieved and data was extracted regarding patient demographics, nature and duration of symptoms, exam findings, work-up, intra-operative findings and surgical pathology. These data were compiled in Microsoft Excel and analyzed using descriptive statistics.

In addition, a systematic literature review was performed following the PRISMA guidelines⁶. The PubMed database was queried using the search terms “testicular torsion” and “Africa” and the names of all sub-Saharan African countries, as well as the MeSH terms “testicular torsion” and “Africa.” The African Journals Online database (www.ajol.info) was also queried using the search term “testicular torsion.” All reports based on empirical studies published between 1990-2015 for which at least an abstract was available were included. Duplicate reports were excluded and then abstracts were reviewed. Reports were then screened and excluded if they were case reports or animal studies. Finally, reports were assessed for eligibility and excluded if they were reports of patient populations outside sub-Saharan Africa, reports of pathological examinations, reports in which testicular torsion was not a main focus of the study, or review articles.

Results

Over a three year period, seven patients were treated for testicular torsion (Table 1). Ages ranged from 5 days to 18 years. Six patients had acute onset of symptoms, while the seventh had over a year of intermittent symptoms.

Table 1. Patients treated for testicular torsion

Age	Month	Presenting Symptoms	Duration of Symptoms	Physical Exam Findings	ED Diagnosis	Ultrasound findings	Viability of Testis	Operation Performed
13 y	Sept	scrotal pain	12 h	unilateral testicular tenderness, swelling	testicular torsion	epididymo-orchitis	no	orchiectomy, contralateral orchiopexy
5 d	June	scrotal swelling	5 d	unilateral testicular swelling	undescended testis	testicular torsion	no	orchiectomy, contralateral orchiopexy, circumcision
18 y	July	scrotal pain, swelling	37 h	unilateral testicular tenderness, elevation	testicular torsion	torsion with no flow, no evidence of viability	no	orchiectomy, contralateral orchiopexy
1.3 y	July	scrotal swelling, discoloration	12 h	unilateral testicular tenderness, erythema, elevation	undescended testis, possible epididymal torsion	enlarged and heterogeneous testis, possible germ cell tumor or subacute or missed torsion	no	orchiectomy, contralateral orchiopexy
2.5 y	July	scrotal pain, swelling	4 h	unilateral testicular tenderness, swelling, hyperemia	possible testicular torsion	not obtained	yes	bilateral orchiopexy
12 y	Apr	scrotal pain, swelling	1 day	unilateral testicular tenderness, swelling	acute epididymo-orchitis, possible testicular torsion	not obtained	no	orchiectomy, contralateral orchiopexy, circumcision
13 y	Apr	intermittent scrotal pain	>1 year	nontender, unenlarged testes	recurrent testicular torsion and detorsion	not obtained	yes	bilateral orchiopexy

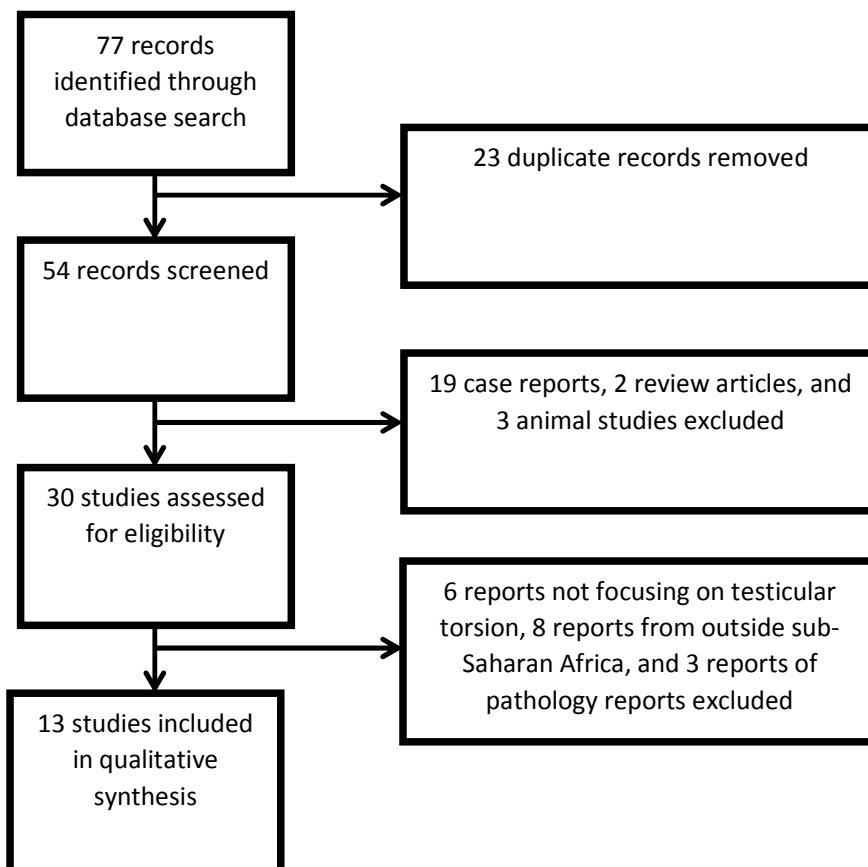
In the patients with acute presentations, presenting symptoms included scrotal swelling (5/6), unilateral testicular pain (4/6), and discoloration (1/6). The duration of symptoms ranged from 4 hours to 5 days at the time of surgical consultation. Five of the six acute cases occurred between June and September, during the rainy season in Ethiopia. .

The patient with chronic, intermittent symptoms reported severe unilateral testicular pain that resolved spontaneously after about one day when symptomatic

Among the patients with acute onset of symptoms, all were afebrile on presentation. Physical examination findings in the emergency department included unilateral testicular tenderness (5/6), scrotal swelling (4/6), scrotal discoloration (2/6), and testicular elevation (2/6). In 5/6 cases, patients underwent laboratory evaluation, with normal or mildly elevated white blood cell counts (5,000-15,000/microliter) and haematocrit (41-46%). In 4/6 cases, surgical consultation was delayed to obtain a color Doppler ultrasound to confirm the diagnosis. One ultrasound study was obtained prior to referral and three were obtained from the radiology department by the physician staffing the emergency department. Two of the ultrasound studies confirmed a diagnosis of testicular torsion, while the other two suggested alternate diagnoses.

In 5 out of the 6 acute cases, including all of those in which an ultrasound was obtained, the affected testis was grossly nonviable at the time of scrotal exploration and orchiectomy was performed with contralateral orchiopexy. Testicular salvage was only possible in one acute case—the patient who had four hours of symptoms—and the one chronic, intermittent case. In these cases bilateral orchiopexy was performed, for a testicular salvage rate of 29%. All patients had uneventful post-operative courses and no surgical complications were noted.

Table 2. PRISMA flowchart



Seven reports were case series or cohort studies of patients with confirmed testicular torsion^{7-9,13,14,17,18}; five reports were case series or cohort studies of patients presenting with acute scrotal pain^{10-12,15,16} and one cohort study compared patients presenting with testicular torsion and orchitis¹⁹

All reports were hospital-based. One report only included adult patients⁹, one only included pediatric patients¹⁵, and the remaining 11 reports included all ages^{7,8,10-14,16-19}. Study periods ranged from two to 18 years, with one multinational study presenting data from one French and six sub-Saharan African cohorts spanning two to eight years. Ten of the reports included testicular salvage rates, and six of those were less than 60%.

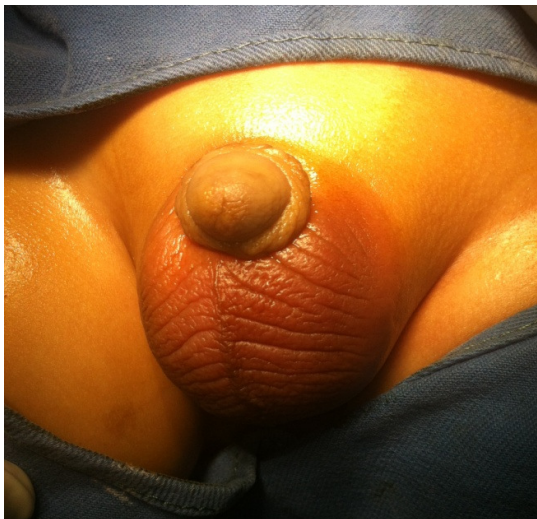

Figure 1. Scrotal Appearance in Acute Testicular Torsion.

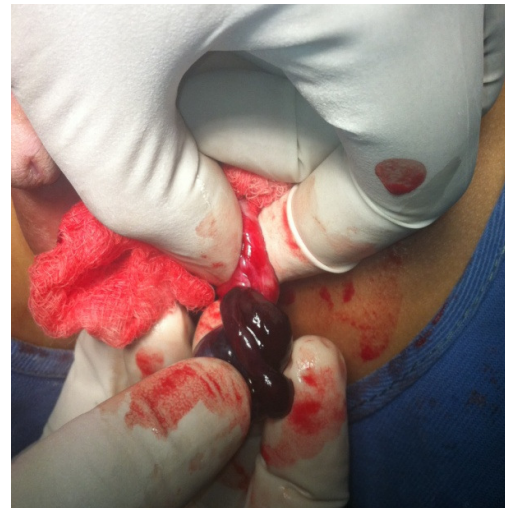

Figure 2. Intra-operative Appearance of Twisted Testis

Authors	Country	Year Published	Time Range	Sample Size	Age Range, years (mean)	Salvage Rate
Muguti et al ¹⁸	Zimbabwe	1994	1987-1991	90	<1-32 (17)	36%
Magoha ¹⁶	Kenya	1995	1988-1995	110	(21)	21%
Kuranga ⁷	Nigeria	2002	1989-1998	87	<1-50 (22.1)	14%
Obi and Aghaji ⁹	Nigeria	2003	2000-2002	50	14-45 (22.5)	NR
Ugwu et al ⁸	Nigeria	2003	1993-2001	57	2-55 (22.7)	61%
Mbibu et al ¹⁰	Nigeria	2004	1978-1997	178	<1-55 (23)	52%
Dakum et al ¹¹	Nigeria	2005	2001-2002	18	NR	72%
Gnassingbe ¹⁵	Mali	2009	2003-2007	17	<1-15 (4.75)	NR
Okorie ¹⁴	Cameroon	2011	2003-2011	16	13-32	NR
Maranya ¹⁷	Kenya	2011	1999-2011	29	NR	14%
Njeze ¹²	Nigeria	2012	1993-2003	22	10-38 (22.7)	75%
Baruga an Munabi ¹⁹	multinational	2013	1980-2011	305	NR	56%
Takure et al ¹³	Nigeria	2013	1998-2010	169	<1-45 (23.8)	81%

* NR = not reported

Discussion

Although it is a well documented clinical entity, there are few published reports of testicular torsion in sub-Saharan Africa, and accurate quantification of the incidence and clinical outcomes of testicular torsion in sub-Saharan Africa remains elusive. The only previous report of testicular torsion in Ethiopia that we encountered in the published medical literature was a case report of intrauterine testicular torsion from 1993²⁰. In our study, five of the six cases of acute testicular torsion occurred during the rainy season, which is the coldest time of year in Ethiopia. Several previous studies in both the African and international literature have noted also seasonal variation in the incidence of testicular torsion, with torsion more common during colder times of year^{8,10,21-24}. Two of our cases were atypical, with one case of perinatal testicular torsion and one case of intermittent testicular torsion. These are both rare entities that are well-documented in the international literature²⁵.

Our study's findings are similar to those of many of the reports identified in our systematic literature review regarding the demographics of patients with testicular torsion, with a wide range of ages from infancy to adulthood, as well as their clinical presentations, with severe scrotal pain and swelling as the most common symptoms. Our testicular salvage rate of 29% is consistent with the low rate observed in most of the reviewed studies. Several of these studies noted delayed presentation and missed or delayed diagnosis as an important factors contributing to testicular loss^{10,11,16,18}. Because none of these studies were population-based, the true prevalence of testicular torsion in sub-Saharan Africa remains elusive. While the scope of this problem in sub-Saharan Africa has not been well studied, one study from Nigeria cited testicular torsion as the causative event in 6% of case of testicular insufficiency²⁶.

This study has several limitations. As a single-site case series, we cannot comment on the population prevalence of testicular torsion in Addis Ababa. Some patients with testicular torsion may have been referred to other surgeons in the city, and it is likely that some patients with testicular torsion never received medical care or surgical consultation. In addition, our literature review was limited by our inability to access full manuscripts for several of the included reports, forcing us to rely on data included in abstracts. Logistical challenges prevented us from including grey literature in this review. Nevertheless, we feel that it is important to draw attention to the appropriate diagnosis and management of this surgical emergency.

Traditionally, surgical exploration has been advocated for all pediatric patients presenting with acute onset of unilateral scrotal pain^{21,27}. More recently authors have recommended radiographic evaluation prior to surgery, with color Doppler ultrasound as the first line imaging modality of choice^{5,28-30}. However, these recommendations generally come from research-rich settings where point-of-care ultrasound is available in the emergency department. The only article from sub-Saharan Africa commenting on the use of color Doppler ultrasound that we encountered was a review article that only recommended its use in patients with a low probability of torsion with long duration of symptoms or positive urinalysis³¹. None of the studies from sub-Saharan Africa in our review commented on the impact of color Doppler ultrasound on diagnosis or delays in intervention in patients with acute scrotal pain.

Testicular torsion remains an under-diagnosed surgical emergency in Ethiopia, and throughout sub-Saharan Africa. A low index of suspicion and urgent surgical consultation are crucial to improve the rate of testicular salvage. Timely diagnosis of testicular torsion is especially important because in addition to the threat to the affected testis, testicular torsion poses a threat of auto-antibody mediated damage to the contralateral testis³². It is important to educate both patients and primary care providers about the seriousness of acute scrotal pain, swelling and discoloration, and the urgency of early presentation and surgical consultation. In the absence of the equipment and expertise to provide accurate point-of-care color Doppler

ultrasonography, surgical consultation and scrotal exploration should not be delayed to obtain radiographic work-up for patients with acute scrotum.

Sources of Support

This project was supported by NIH Fogarty International Center (Grant #R25TW009338) under the Global Health Equity Scholars Consortium. The authors declare that they have no conflicts of interest to disclose.

References

1. O'Brien M, Chandran H. The acute scrotum in childhood. *Surgery (Oxford)*. 2008;26:279-282.
2. Vasdev N, Chadwick D, Thomas D. The Acute Pediatric Scrotum: Presentation, Differential Diagnosis and Management. *Curr Urol*. 2012; 6:57-61.
3. Cost NG, Bush NC, Barber TD, Huang R, Baker LA. Pediatric testicular torsion: demographics of national orchiopexy versus orchiectomy rates. *J Urol*. 2011;185:2459-2463.
4. Baker LA, Sigman D, Mathews RI, Benson J, Docimo SG. An Analysis of Clinical Outcomes Using Color Doppler Testicular Ultrasound for Testicular Torsion. *Pediatrics*. 2000;105:604-607.
5. Blaivas M, Sierzenski P, Lambert M. Emergency Evaluation of Patients Presenting with Acute Scrotum Using Bedside Ultrasonography. *Acad Emerg Med*. 2001;8:90-93.
6. Liberati A, Altman DG, Tetzlaff J, Mulrow C, Gotzsche PC, Ioannidis JP, et al. The PRISMA statement for reporting systematic reviews and meta-analyses of studies that evaluate healthcare interventions: explanation and elaboration. *BMJ*. 2009;339:b2700.
7. Kuranga SA, Rahman GA. Testicular torsion: Experience in the Middle Belt of Nigeria. *Afr J Urol*. 2002;8:78-82.
8. Ugwu BT, Dakum NK, Yiltok SJ, Mbah N, Legbo JN, Uba AF, et al. Testicular torsion on the Jos Plateau. *West Afr J Med*. 2003;22:120-123.
9. Obi AO, Aghaji AE. Torsion of the Spermatic Cord: Is Bilateral Orchidopexy Really Necessary? *J Coll Med (Nigeria)*. 2003;8:42-44.
10. Mbibu NH, Maitama HY, Ameh EA, Khalid LM, Adams LM. Acute scrotum in Nigeria: an 18-year review. *Trop Doct*. 2004;34:34-36.
11. Dakum NK, Ramyil VM, Sani AA, Kidmas AT. The acute scrotum: aetiology, management and early outcome-preliminary report. *Niger J Med*. 2005;14:267-271.
12. Njeze GE. Testicular torsion: Needless testicular loss can be prevented. *Niger J Clin Pract*. 2012;15.
13. Takure AO, Shittu OB, Adebayo SA, Okeke LO, Olapade-Olaopa EO. Torsion of the testis and factors that determine the choice of orchidectomy and unilateral orchidopexy. *Niger Postgrad Med J*. 2013;20:197-202.
14. Okorie CO. Unilateral testicular torsion with necrotic outcome: dilemmas of surgical timing. *Urology*. 2011;78:1232-1234.
15. Gnassingbe K, Akakpo-Numado GK, Songne-G B, Anoukoum T, Sakiye KA, Kao M, et al. [Acute scrotum in children]. *Mali Med*. 2009;24:31-35.
16. Magoha GA. Torsion of the testis in Africans in Nairobi. *East Afr Med J*. 1995;72:758-760.
17. Maranya G, Mwero B, Kinyanjui G, Al-Ammary A, Maganga H. Dismal salvage of testicular torsion: A call to action! *Ann Afr Surg*. 2011;8.
18. Muguti GI, Kalgudi R. Torsion of the testis: review of clinical experience in Zimbabwe. *Cent Afr J Med*. 1994;40:119-122.
19. Baruga E, Guyton Munabi I. Case series on testicular torsion: an educational emergency for sub-Saharan Africa. *Pan Afr Med J*. 2013;14:18.
20. Bekele Z, Lulseged S. Intrauterine-neonatal torsion of the spermatic cord in an Ethiopian newborn. *Ethiop Med J*. 1993;31:223-226.

21. Molokwu CN, Somani BK, Goodman CM. Outcomes of scrotal exploration for acute scrotal pain suspicious of testicular torsion: a consecutive case series of 173 patients. *BJU Int.* 2011;107:990-993.
22. Lyronis ID, Ploumis N, Vlahakis I, Charissis G. Acute scrotum -etiology, clinical presentation and seasonal variation. *Indian J Pediatr.* 2009;76:407-410.
23. Srinivasan AK, Freyle J, Gitlin JS, Palmer LS. Climatic conditions and the risk of testicular torsion in adolescent males. *J Urol.* 2007;178:2585-2588.
24. Mabogunje OA. Testicular torsion and low relative humidity in a tropical country. *Br Med J.* 1986;292:363-364.
25. Gatti JM, Patrick Murphy J. Current management of the acute scrotum. *Semin Pediatr Surg.* 2007;16:58-63.
26. Ahmed A, Bello A, Mbibu NH, Maitama HY, Kalayi GD. Epidemiological and aetiological factors of male infertility in northern Nigeria. *Niger J Clin Pract.* 2010;13:205-209.
27. Cavusoglu YH, Karaman A, Karaman I, Erdogan D, Aslan MK, Varlikli O, et al. Acute scrotum -- etiology and management. *Indian J Pediatr.* 2005;72:201-203.
28. Kapoor S. Testicular torsion: a race against time. *Int J Clin Pract.* 2008;62:821-827.
29. DaJusta DG, Granberg CF, Villanueva C, Baker LA. Contemporary review of testicular torsion: new concepts, emerging technologies and potential therapeutics. *J Pediatr Urol.* 2013;9:723-730.
30. Yagil Y, Naroditsky I, Milhem J, Leiba R, Leiderman M, Badaan S, et al. Role of Doppler Ultrasonography in the Triage of Acute Scrotum in the Emergency Department. *J Ultrasound Med.* 2010;29:11-21.
31. Visser AJ, Heyns CF. Torsion of the testis and its appendages: Diagnosis and management. *Afr J Urol.* 2004;10:85-91.
32. Visser AJ, Heyns CF. Testicular function after torsion of the spermatic cord. *BJU International.* 2003;92:200-203.