



Pseudomyxoma Peritonei: An Unusual Complication of Ovarian Tumor

S.R. Singhal¹, R. Sharma¹, R. Sen², A. Gupta¹

¹Department Of obstetrics and Gynecology, ²Department of pathology, Pt B D Sharma Post Graduate Institute Of medical Sciences, Rohtak, Haryana, 124001, India

Correspondence to: Dr Savita Rani Singhal, Email- savita06@gmail.com

Pseudomyxoma peritonei, also known as adenomucinosis or jelly-belly, is enlisted as very rare and recurrent clinical condition accidentally diagnosed by surgeons during laparotomy and laparoscopy. It is characterized by excessive extracellular mucin accumulation in peritoneal cavity due to leakage of mucin secreting cells from a mucinous tumor of appendix. There is an exception where this condition arises from mucinous tumor of ovary. We present an interesting case where a 40 years old woman presented with an ovarian mass and intraoperatively abdominal cavity was found to be filled with huge mucinous ascites and big ovarian tumor. Surgical debulking was done and the histopathology report demonstrated a well differentiated adenocarcinoma of ovary with mucin deposits in the omentum and a malignant variant of pseudomyxoma peritonei (Peritoneal mucinous carcinomatosis).

Key Words- Ovarian tumor, Pseudomyxoma peritonei, chemotherapy

Introduction

Pseudomyxoma peritonei (PMP) is a very rare clinical condition also known as adenomucinosis or gelatinous ascites with an estimated incidence of one to two cases per million per year¹. It is usually encountered accidentally during the surgery, and this pathology is seen in two of 10,000 laparotomies². This condition usually has its origin from ruptured appendiceal mucinous adenoma, though there are some case reports where PMP is seen in presence of normal appendix or prior appendectomy³. It also shows association with mucinous malignancies of ovary, colon, urachus, biliary tree, stomach and uterus. There occurs progressive accumulation of large amount of extracellular mucin in the peritoneal cavity and metastatic implants on peritoneum and omentum.. WERTH coined the term Pseudomyxoma peritonei and he found its association with an mucinous tumour of ovary in 1884². It is pathologically and prognostically classified in three distinct categories such as DPAM (Disseminated peritoneal adenomucinosis), PMCA (Peritoneal mucinous carcinomatosis) and an intermediate group⁴. A case of pseudomyxoma peritonei with origin from mucinous tumour of ovary is reported due to its rarity.

Case Report

A 40-years old woman with four live children was referred by a private practitioner with complaints of abdominal distension, dull aching abdominal pain and decreased appetite for three months. Her general and systemic examination was normal. Abdominal examination revealed ascites with cystic to firm mass of about 24 week gravid uterus size, well defined, arising from pelvis, reaching up to umbilicus and with

restricted mobility. Same mass was felt through anterior and lateral fornices on vaginal examination. Ultrasonography of whole abdomen showed ascites with a large 18x 15 cm hypoechoic right adnexal mass with multiple internal septations and uterus, liver, gall bladder, spleen, kidney, urinary bladder and appendix appeared normal. CECT pelvis also showed a large well defined rounded hypodense mass lesion in pelvic region arising from right adnexa with CT attenuation value of 5-10 HU with fluid content and mild enhancing walls and normal left adnexa and uterus.

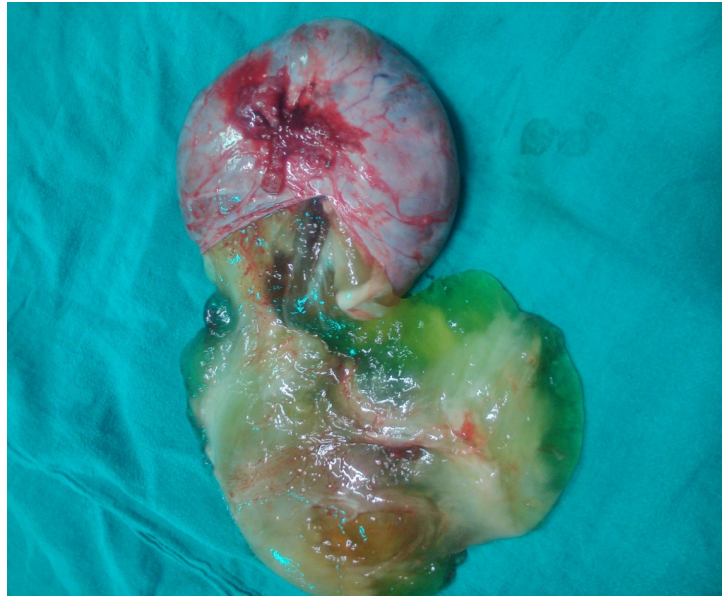

Figure 1. Gross Appearance of Mucin Filled Right Ovarian Cyst

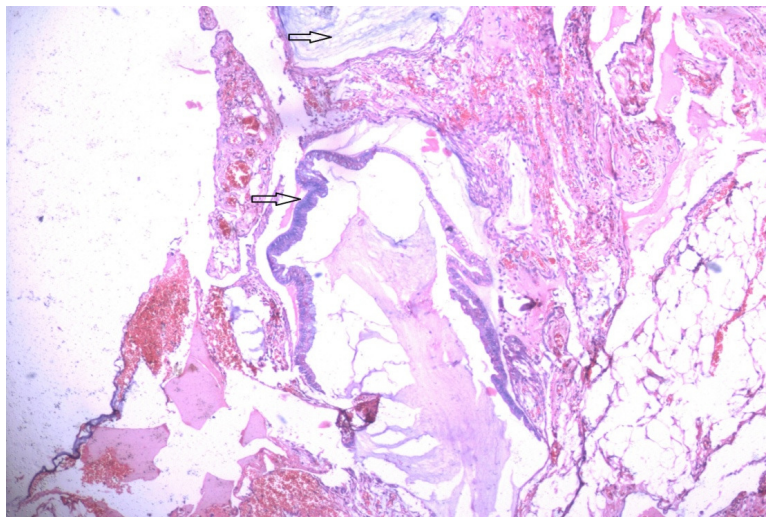


Figure 2. Omentum Showing Pools of Mucin along with Metastatic Deposits from Adenocarcinoma of Ovary at 40x

Tumor marker CA-125 level was 96.7 U. patient was taken for staging laparotomy which revealed, around 1000cc mucinous ascites, dense adhesion of intestines with uterus, ovaries and omentum, tumor seedlings on gut, bladder, omentum, under surface of diaphragm, left ovary and uterus. There was a right sided multiloculated ovarian cyst filled with mucin of 18x15 cm size with smooth surface (Figure 1). Surgical debulking was done which included right sided salpingo-opherectomy and omentectomy with multiple biopsies. Removal of uterus, left side tube and ovary was not possible due to dense adhesions.


Histopathological report showed a well differentiated adenocarcinoma ovary and metastatic deposits from mucin secreting adenocarcinoma in omentum (Figure 2). Pseudomyxoma peritonei was designated as peritoneal mucinous carcinomatosis (PMCA). She was given cisplatin based chemotherapy after radiotherapy department consultation. Patient was discharged in good condition and was alright after six courses of chemotherapy. She did not consent for complete surgery after chemotherapy and continued to come for follow up till one year and there was no recurrence.

Discussion

Pseudomyxoma peritonei has an indolent course and presents with non specific symptoms. There occurs leakage of tumor cells in to peritoneal cavity from rupture of mucinous tumors of appendix or ovary. Peritoneal cavity is filled with septate jelly like fluid. Mucinous implants are found on all peritoneal surfaces and the omentum. This mucin causes compression of vessel, gastrointestinal tract and other abdominal structures and results in distortion and impaired function of these organs⁵. These cases present unexpectedly during laparotomy and laparoscopy. Some cases may present with intestinal obstruction associated with fibrosis caused by mucin. Its preoperative diagnosis is very difficult and tumor markers like CEA, CA125 CA19-9 have prognostic value. CECT is currently the optimal imaging modality for the diagnosis and staging of PMP and it predicts likelihood of complete cytoreduction⁶.

Ultrasonography of abdomen may detect immobile ascites. Histology of the tumor shows clinical behavior of the tumor. PMP designated as DMPA is slow progressive and have prolonged survival whereas PMCA depicts metastatic adenocarcinoma with aggressive clinical course⁷. Standard treatment for pseudomyxoma peritonei is surgical debulking, in which the tumor is removed as much as possible. Intraperitoneal cisplatin chemotherapy is also a good modality of treatment for pseudomyxoma peritonei. Intraperitoneal hyperthermic chemotherapy is a newer modality of treatment for PMP and it is given for 30 minutes at 41-42celsius temperature using cisplatin (100 mg/m²) and mitomycin-c (25mg/m²) or 5-flurouracil and mitomycin⁵. Hyperthermia causes destruction of malignant cells and improves absorption of chemotherapy. Even with a better understanding and recent advances in the management of these cases, low incidence of PMP makes it difficult to study the disease and to evaluate the real efficiency of the various modalities of treatment.

Conclusion



This condition can be encountered by any surgeon during the surgery and the best treatment is to perform complete cytoreduction after taking multiple biopsies and to do appendicectomy if possible.

References

1. Amini A, Moghaddam SM, Ehteda A, Morris DL. Secreted mucins in pseudomyxoma peritonei: pathophysiological significance and potential therapeutic prospects. *Orphanet Journal of Rare Diseases*. 2014;71:1-12.
2. Jacquemin G, Laloux P. Pseudomyxoma Peritonei : Review on a Cluster of Peritoneal Mucinous Diseases. *Acta chir belg*. 2005;105:127-33.
3. Sueblinvong T, Hanprasertpong J. Pseudomyxoma Peritonei Associated with Ovarian Tumor. *Thai J Obstet Gynecol*. 2003;15(3):123-28.
4. Pranesh N, Menasce LP, Wilson MS, O'Dwyer ST. Pseudomyxoma peritonei: unusual origin from an ovarian mature cystic teratoma. *J Clin Pathol*. 2005;58:1115-7.
5. Kamal SM, Bakar MA, Ali MY, Ahad MA. Pseudomyxoma peritonei: A Review. *Faridpur Med. Coll. J*. 2012;7(2):88-92.
6. Bevan KE, Mohamed F, Moran BJ. Pseudomyxoma peritonei. *World J Gastrointest Oncol*. 2010; 2(1): 44-50.
7. Djordjevic B, Stojanovic S, Ljubenovic N and Djordjevic I. Pseudomyxoma peritonei and mucinous ovarian tumors. *Acta Medica Medianae*. 2009; 48(1): 46-9.