

## **Lumbar Disc Degenerative disease: Magnetic Resonance Imaging Findings in Patients with Low Back Pain in Dar Es Salaam.**

**M. Jacob<sup>1</sup>, L.O. Akoko<sup>2</sup>, R.R. Kazema<sup>1</sup>**

<sup>1</sup>Department of Radiology, Muhimbili University of Health and Allied Health Sciences

<sup>2</sup>Department of surgery Muhimbili University of Health and Allied Sciences,

**Corresponding to:** Dr M. Jacob, E-mail: [mbokajacob@gmail.com](mailto:mbokajacob@gmail.com)

**Financial support:** Government of Tanzania through Ministry of Health and Social Welfare(MOHSW).

**Background:** Lower back pain (LBP) is a public health problem and lumbar disk degenerative disease (LDDD) is a main cause. Studies elsewhere show that the prevalence of LDDD ranges from 85% - 95%. MRI being the best modality for spine disorders, we studied pattern of LDDD in patients with LBP.

**Methods:** This was a seven months, hospital based descriptive, prospective study which involved all patients presenting with LBP referred for MRI. Patient characteristics were analyzed using SPSS version 13.

**Results:** One hundred and sixty five patients were recruited into the study. Their ages ranged from 20 to 80 years with a mean of  $50 \pm 12.5$  years. Female accounted for 87 (53%) of the cases.

Most of the patients had LDDD. The disease mostly affected individuals in the age group above 60 years ( $P < 0.05$ ) with no sex difference. Disk herniation, central canal stenosis and nerve root compression were significantly seen in patients with radiculopathy ( $P = 0.00$ ). L4/L5 & L5/S1 were the most affected.

**Conclusions:** LDDD occurs in all age groups but individual aged 60 years and above are most affected. There is a relationship between radiculopathy and disk herniation, central canal stenosis and nerve root compression. The lower lumbar spine levels remain the most affected area for disk degenerative disease.

### **Introduction**

Lumbar disc degenerative Disease (LDDD) is the most common cause of low back pain worldwide and refers to a syndrome in which an intervertebral disk with adjacent spine structures are compromised. The prevalence of LDDD increases with age affecting 85% to 95% of adults aged 50 to 55 years, with no sex difference<sup>1,2</sup>. Lumbar spine is the common area affected by degenerative changes, as it is a part of spine, which is subjected to heavy mechanical stress<sup>3</sup>. Lumbar degeneration can occur at any level but mainly it occurs on L3-L4, L4-L5 and L4-S1 vertebrae<sup>3,4,5</sup>.

Lumbar degenerative disk disease may present as disk degeneration, Modic changes, disk displacement, lumbar spinal stenosis, facet joint arthropathy or their combination. Disk degeneration is a loss of disk signal on T2W images with/without disk height reduction<sup>1</sup>. The dark signal of the disk on T2W images is due to loss of water content. Initially there are biochemical changes within a disk, resulting in dehydration of disk<sup>1</sup>. In later stages of the disease there is morphological changes such as loss of disk height, annular tears, rim lesions and osteophyte<sup>6</sup>. The occurrence of annular tears leads to weakening of the annulus fibrosus hence disk displacement beyond the vertebral margins. Disk degeneration is common in individuals who are more than 40 years of age though its prevalence increases progressively to over 90% by 50 to 55 years of age<sup>7,8,9</sup>.

Modic changes are endplate degenerative changes due to disk degenerative disease<sup>10</sup>. These Modic changes can be painful – especially type I changes<sup>1</sup>. They are common observation on MR images and are of three main forms<sup>1</sup>. Type I is the acute stage of disk disease, there is invasion of the cancellous spaces by fibrovascular reactive tissue<sup>1,11</sup>. With time, fatty replacement of red marrow occurs leading to type II Modic changes; eventually bony sclerosis of the marrow occurs and leads to type III Modic changes<sup>1,11</sup>. Spinal stenosis is defined as loss of signal in epidural fat with compression of neural tissues within the canal<sup>10,12</sup>. Spinal stenosis is evident when there is reduction of spinal canal diameter to less than 18mm<sup>7</sup>.

Disk displacement is also one of the findings in spine degenerative disease. The displaced disk can be a simple bulge, herniation, extruded or sequestration<sup>13</sup>. *Disk bulge* is a circumferential enlargement of the disk contour in a symmetric fashion in a weakened disk, the annulus is intact with disk extension outward involving >50% of disk circumference<sup>14</sup>. Herniation occurs when nuclear materials protrude or extrude into the perineural space through radial tears of the annulus<sup>7,12,13</sup>. Disc degeneration and loss of disc space height, leads to increased stresses on the facet joints with craniocaudal subluxation resulting in facet joint arthropathy<sup>15</sup>.


LBP is the main presenting symptom followed by sciatica. Features suggestive of sciatica are unilateral or bilateral leg pain radiating to the feet and toes, numbness in dermatomes distribution and positive straight leg raising test. Sciatic pain aggravates on standing, walking, bending, straining and coughing<sup>16</sup>. Eighty percent (80%) of the adult population suffers from LBP at some time in their lives and around 10% of sufferers become chronically disabled<sup>17,18</sup>. The possible sources of pain are mechanical compression of neural elements by disk herniation, as well as direct biochemical and inflammatory<sup>13,19</sup>.

Ageing is main factor implicated in spine degenerative disease<sup>13</sup>. Apart from age other factors include genetic inheritance, physical loading history, trauma and impaired nutrition, smoking, obesity, immobilization, psychosocial factors, gender, height, occupations like machine drivers, carpenters and office workers<sup>1,20,21,22</sup>.

Main diagnostic tool and imaging technique for the evaluation of disc degeneration is magnetic resonance imaging (MRI)<sup>23</sup>. The role of diagnostic imaging in spine degenerative disease is to evaluate the status of the neural tissues and to affect the therapeutic decision making<sup>24</sup>.

The main objective of this study was to determine the pattern of lumbar degenerative disk disease by using MRI and we also evaluated the relation between lumbar degenerative diseases with symptomatology

## Patients and Methods



This was a cross sectional study conducted in the MRI unit department of Radiology in Muhimbili National Hospital Dar Es Salaam. The duration of the study was 7 months from March to September 2010. A total of 165 patients with LBP were included in this study after obtaining written consent. Once the subject was entered in the study, multiplanar MRI was done from the first lumbar to the first sacral vertebra with a 1.5-tesla imaging system (Phillips, Achiever, Best, Eindhoven, Netherlands).

Two observers analyzed all scans independently. Intra- and inter-observer reliabilities were assessed by calculating kappa statistics. All images were screened for evidence of neoplastic, inflammatory or infectious disorders, and if any were observed, the patient was excluded from the study. Each spinal level was evaluated separately. Each level from L1-S1 was assessed for disk degenerative disease, using the latest international nomenclature for describing disk pathology. The variables evaluated on MRI were disk degeneration, Modic changes, Disk bulge, herniation, central canal stenosis and nerve root compression. Disk degeneration was classified by using a nomenclature used by Dominic et al<sup>25</sup>. Grade 1-2 disc degeneration was considered normal while grade 3-5 were accepted as a presence of degeneration. Modic changes were evaluated in accordance with the system described by Modic<sup>13</sup>. Disk bulge was defined as presence of circumferential enlargement of the disk contour in a symmetric fashion in a weakened disk, the annulus is intact with disk extension outward involving >50% of disk circumference. Disk herniation presence of (localized/focal displacement of disk beyond the intervertebral disc space. Central canal stenosis was defined as narrowing of the spinal canal anterior-posterior diameter anywhere along its axis. Severity of canal stenosis was graded as per Borenstein et al<sup>14</sup>. Mild canal stenosis was evaluated by the presence flattening of the ventral thecal sac. Moderate canal stenosis is the triangularization of spinal canal with loss of posterior epidural fat pad and severe canal stenosis: compression of the canal with loss of epidural fat in all planes. Only those with moderate and severe canal stenosis were diagnosed as patient with canal stenosis. Nerve root compression was defined as presence of mass effect on nerve root.

A structured questionnaire was used to collect patient findings, which included questions regarding biodata (age, sex, gender, and date), symptomatology, and MRI findings. The study was approved by Institutional Review Board of Muhimbili university of Health and Allied sciences.

Each spine level and all aspects of degeneration were considered individually as 100%. Most of the patients had more than one spine level affected and more than one finding. Institutional Review Board of Muhimbili University of Health and Allied Sciences (MUHAS) ethically approved the study. Descriptive indices, like frequency, percentage, mean and standard deviation, were used to summarise patient demographic and MR imaging findings. Chi-square and Fisher's exact test were used for comparison between demographic, presenting symptoms and MRI findings. All analyses was performed using the Statistical Package for Social Sciences (SPSS) version 13. A p-value of 0.05 was considered to indicate a statistically significant difference.

## Results

The study included 165 patients, with age ranges from 20-80 years, and a mean of 50±12. A slight female preponderance was observed at 53% (87) fig 2 with 132 (80%) of the patients

presenting with radiculopathy. One hundred and fifty nine (94%) of the patients had at least one degenerative finding.

The commonest degenerative finding was disk degeneration in 137 (83%) followed by nerve root compression in 127 (77%) and disc herniation in 104 (63%). Of all the degenerative findings, only disc bulge and herniation did not significantly increase with age [Table 1]. With the exception of disk bulge, all disk degenerative changes were proportionally higher among men, but these observations were not statistically significant [Table 2]. Figure 2 shows the distribution of patients by age and sex. Table 4 shows the distribution of disk degenerative changes by disk level. The commonest two site were L4/L4 and L5/S1 level

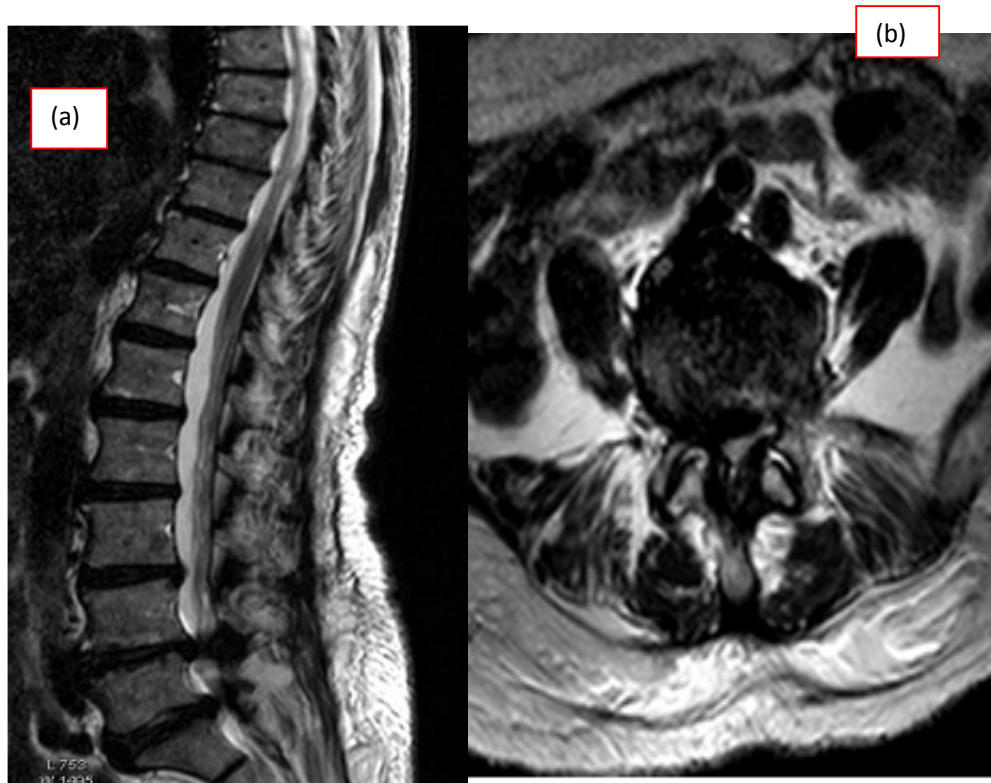
**Table 1.** Distribution of patients with degenerative imaging findings by age.

Pathological Findings	Age in years			Total	P value
	20-39 (n=30)	40-59 (n=98)	60-80 (n=37)		
Disk degenerative changes	13 (43)	87(89)	37(100.0)	137(83.0)	0.000
Disk degeneration	2(6.7)	31(31.6)	14(37.8)	47(28.5)	0.011
Modic changes	12(40.0)	40(40.8)	12(32.4)	64(38.8)	0.664
Disk bulge	14(46.7)	63(64.3)	27(73.0)	104(63.0)	0.079
Disk Herniation	2(6.7)	30(30.6)	18(48.6)	50(30.3)	0.001
Canal Stenosis	17(56.7)	77(78.6)	33(89.2)	127(77.0)	0.002
Nerve root compression					

**Table 2.** Percentage Distribution of Degenerative Imaging Findings by Sex.

Disk degenerative changes	Sex			P- value
	Male (n=78)	Female(n=87)	Total(N=165)	
Disk degeneration	67(85.9)	70(80.5)	137(83.0)	0.353
Modic changes	26(33.3)	21(24.1)	47(28.5)	0.191
Disk bulge	27(34.6)	37(42.5)	64(38.8)	0.298
Disk herniation	54(69.2)	50(57.5)	104(63.0)	0.118
Canal stenosis	24(30.8)	26(29.9)	50(30.3)	0.902
Nerve root compression	63(80.8)	64(73.6)	127(77.0)	0.272

p-value was calculated by from chi-square



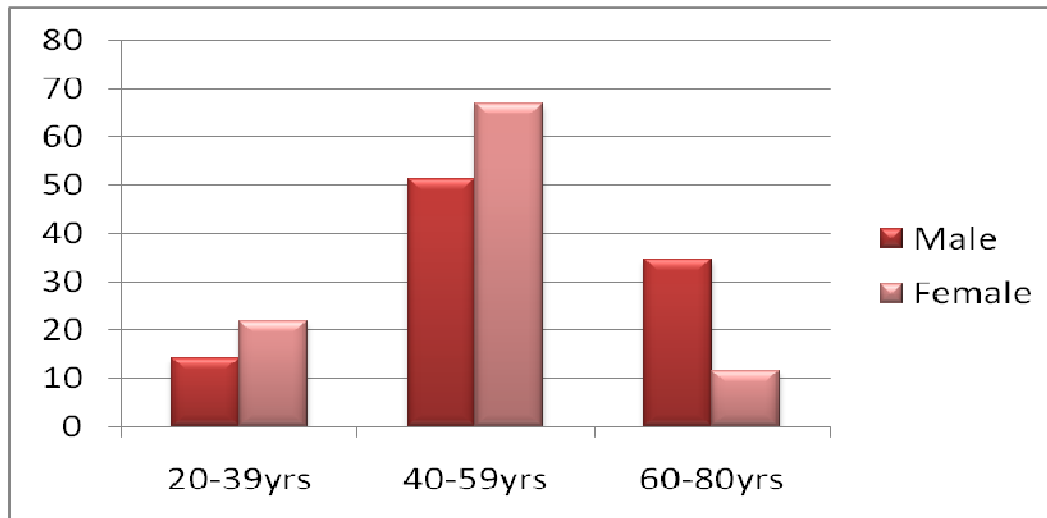
**Figure 1.** (a) Sagittal and axial (b) T2-W MR image showing disk herniation at L4/L5 and L5/S1 and severe central canal stenosis at L5/S1.

**Table 3.** Distribution of degenerative imaging findings by patient presenting symptoms.

Disk degenerative changes	Symptoms		
	LBP with Radiculopathy (n=132)	LBP only (n=33)	P. value
Disk degeneration	111(84)	26(79)	0.468
Modic changes	43(33)	4(12)	0.020
Disk bulge	50(38)	14(42)	0.632
Disk herniation	100(76)	4(12)	0.000
Canal stenosis	50(38)	0(0)	0.000
Nerve root compression	118(89)	9(27)	0.000

P

value was calculated from Fishers' Exact test.




**Figure 2.** Distribution of Patients by Age and Sex

**Table 4.** Frequency Distribution of Disk Degenerative Changes by Disk Level.

Degenerative changes	Spine level				
	L1/L2	L2/L3	L3/L4	L4/L5	L5/S1
<b>Disk degeneration</b>	24(14.5)	43(26.11)	57(34.5)	109(66.1)	87(52.7)
<b>Modic changes</b>	3(1.8)	7 (4.2)	9(5.5)	22(13.3)	14(8.5)
<b>Disk bulge</b>	1(0.6)	4(2.4)	15(9.1)	38(23)	26(15.8)
<b>Disk herniation</b>	3(1.8)	13(7.9)	29(17.6)	78(47.3)	51(30.9)
<b>Canal stenosis</b>	1(0.6)	2(1.2)	14(8.5)	41(24.8)	15(9.1)
<b>Nerve root compression</b>	5(3)	16(9.7)	38(23)	107(64.8)	71(43)

## Discussion

We studied disk degenerative disease in patients with LBP by using MRI. MR imaging is a modality of choice for diagnosing spine disorders as it provide accurate anatomic information and hence affect the management decision making. All recruited patients underwent MRI of the lumbar spine and both sagittal and axial views of all images were interpreted. Degenerative changes were observed in majority 155 (94%) and most of them had multiple degenerative



changes and more than one spine levels were affected and this findings were also consistent with other studies<sup>8,26</sup>(26)(8). Since lumbar spine is subjected to heavy mechanical stress, it is a common area affected by degenerative changes this could partly explain such observation in this study<sup>27</sup>. The mean age of this study group is  $50 \pm 12.5$  years could be another explanation, as degenerative changes is common in individuals above 50 years of age and its prevalence increases progressively to over 90% by 50 to 55 years of age<sup>8,9</sup>.

The main presenting symptom was LBP followed by radiculopathy consistent with a studies done in Pakistan and Ethiopia<sup>26,28</sup>. Disk degeneration was the most frequent finding observed (83%), in contrary to some other studies where disk herniation is the most common finding<sup>26</sup>. Disk degeneration increased with age, the difference observed was statistically significant (p-value = 0.000) and compares well to the findings of other studies<sup>8,9,26</sup>. The difference in prevalence among young and aged individual could be contributed by aging process. Disk degeneration was slightly more frequent among males 67 (85.9%) as compared to females 70(80.5%), though the variation observed was not statistically significant and compares well with other studies<sup>5,13</sup>. Proportion of degenerated disks progressively increases the lower the spine level, and the most common affected spine levels are L4/L5 and L5/S1<sup>9,25</sup>, this is similar to what was observed in this study.

The prevalence of Modic changes (28%), was higher compared to other studies<sup>1</sup>. In young individuals aged <30 years prevalence of Modic changes is low, ranging from 1.4% to 3.7%<sup>29</sup>; in this study it was 6.7%. The young individuals in this study were in the age group of 20 – 39 years, could explain this difference. Modic changes progressively increased the lower the spine level, and the most common location were L4/L5 and L5/S1. This observation is consistent with previous studies<sup>1,30</sup>.

In this study disk herniation were more common than bulges (63% and 39% respectively); and this is different to the findings reported by other studies(3). This difference could be due to young study population (individuals below 30 years) included in other studies. The prevalence of disk herniation is similar to the findings reported by Modic<sup>24</sup>, but lower than what was reported in other studies<sup>28,31,32</sup>.

Disk bulges were more common among young individuals aged 20 to 39 years as compared to individuals aged 60 to 80 years, unlike disk herniation, which was higher among older individuals. However, these findings were not statistically significant (p-value >0.05). In this study, no significant difference in sex was found in the prevalence of disk bulges and herniation. Various studies have reported that disk herniation is common at L4/L5 and L5/S1 and the frequency at these levels is ranging from 30% to over 90%<sup>26,28</sup>. This was also reflected in this study as 74% of the herniated disks were at L4/L5 and L5/S1, this can be due to the large workload causing stress at these lower lumbar levels of the spine.

The main presentation of disk herniation is sciatica. In this study 76% of patients with LBP with radiculopathy had disk herniation as compared to 12% in those with LBP only (p value 0.000), this is different from report published by Modic<sup>24</sup>. This difference could be due to the short duration of patient's presenting symptoms (less than 3weeks) in Modic's study, while in this study most of patients (88%) had symptoms for more than twelve weeks.

Fifty (30%) patients in this study had central canal stenosis, which is higher compared to that reported by other previous studies<sup>24,31</sup>. The difference observed could be due to much older study population in this study. Older individuals had higher prevalence of canal stenosis in this

study. Both sexes were equally affected. Canal stenosis was frequent at L4/L5 and L5/S1, while none was found at L1/L2 level, these findings are similar to other previous studies<sup>24,31</sup>. Degenerative spinal stenosis is more common in patients with sciatica than in patients with low back pain<sup>31</sup>. In this study the prevalence of canal stenosis among patients with radiculopathy was 38% and none was found among patients with LBP only (p-value 0.000). These findings are similar to findings of previous studies<sup>31</sup>. The small canal in patients with stenosis causes thecal sac or nerve roots to impinge against the spine bone elements hence causing radiculopathy and activity dependent pain.

Nerve root compression is most common among sciatic patients and lower among patients with LBP<sup>31</sup>. In this study prevalence of nerve root compression was 77%, and it increased with age. Males more affected than females, prevalence being 80.8% and 73.6% respectively, though these findings were not statistically significant. Nerve root compression was more frequently seen at L4/L5 contrary to what was reported by Shobeiri et al<sup>31</sup>.

A limitation encountered was a skip technique used that can reduce the sensitivity of MR imaging in the detection of smaller disc protrusions, migrated free disk fragments, and their effect on the thecal sac. In conclusion lumbar spine degenerative disease is prevalent (94%) among patients with LBP and cuts across all age groups. There is a relationship between radiculopathy and disk herniation, central canal stenosis and nerve root compression. The lower lumbar spine levels remain the most affected area for disk degenerative disease. As less is known on MRI pattern of disk degenerative disease in Tanzania, we have established the base line data to be used for future research planning in the field of spine.

## References

1. Kuisma M, Karppinen J, Haapea M, Niinimäki J, Ojala R, Heliövaara M, et al. Are the determinants of vertebral endplate changes and severe disc degeneration in the lumbar spine the same? A magnetic resonance imaging study in middle-aged male workers. *BMC Musculoskelet Disord* [Internet]. 2008 Jan [cited 2014 May 22];9:51. Available from: <http://www.pubmedcentral.nih.gov/articlerender.fcgi?artid=2373785&tool=pmcentrez&rendertype=abstract>
2. Luoma K, Riihimäki H, Luukkonen R, Raininko R, Viikari-Juntura E, Lamminen A. Low back pain in relation to lumbar disc degeneration. *Spine (Phila Pa 1976)* [Internet]. 2000 [cited 2014 May 22];25(4):487-92. Available from: <http://www.mendeley.com/catalog/low-back-pain-relation-lumbar-disc-degeneration-3/>
3. Ong A, Anderson J, Roche J. A pilot study of the prevalence of lumbar disc degeneration in elite athletes with lower back pain at the Sydney 2000 Olympic Games. *Br J Sports Med*. 2003;37:263-6.
4. David G, Ciurea AV, Iencean SM MA. Angiogenesis in the degeneration of the lumbar intervertebral disc. *J Med Life*. 2010;(3):54-61.
5. Cheung KMC, Karppinen J, Chan D, Ho DWH, Song Y-Q, Sham P, et al. Prevalence and pattern of lumbar magnetic resonance imaging changes in a population study of one thousand forty-three individuals. *Spine (Phila Pa 1976)* [Internet]. 2009 Apr 20 [cited 2014 May 23];34(9):934-40. Available from: <http://www.ncbi.nlm.nih.gov/pubmed/19532001>
6. Wang C, Auerbach JD, Witschey WRT, Balderston RA, Reddy R, Borthakur A. Advances in Magnetic Resonance Imaging for the assessment of degenerative disc disease of the lumbar spine. *Semin Spine Surg* [Internet]. 2007 Jun [cited 2014 May 23];19(2):65-71.



- Available from:  
<http://www.pubmedcentral.nih.gov/articlerender.fcgi?artid=2084362&tool=pmcentrez&rendertype=abstract>
7. Dahnet Wolfgang. Central Nervous System: Disk degenerative disease. In: Joyce Rachel John AS, editor. Radiology Review Manual. FIFTH EDIT. Philadelphia: Lippincott Williams & Wilkins; 2003. p. 199–201.
  8. Kasdan RB, Howard JL. Neuroimaging of spinal diseases: a pictorial review. *Semin Neurol* [Internet]. 2008 Sep [cited 2014 May 23];28(4):570–89. Available from: <http://www.ncbi.nlm.nih.gov/pubmed/18843583>
  9. Waris E, Eskelin M, Hermunen H, Kiviluoto O, Paajanen H. Disc degeneration in low back pain: a 17-year follow-up study using magnetic resonance imaging. *Spine (Phila Pa 1976)* [Internet]. 2007 Mar 15 [cited 2014 May 23];32(6):681–4. Available from: <http://www.ncbi.nlm.nih.gov/pubmed/17413474>
  10. Sivas Acar Filiz, Deniz Cihz, Ugur Erel, Esra Erkol Inal, Kurşat Ozoran BS. Abnormal Lumbar Magnetic Resonance Imaging in Asymptomatic Individuals. *Turk J Phys Med Rehab*. 2009;55:73–7.
  11. Weissleder Ralph , Wittenberg Jack, Harisinghani G. Mukesh CWJ. *Primer of Diagnostic Imaging*. Fifth. Gaertner Rebecca CA, editor. Elsevier: Mosby, Inc; 2011.
  12. Boden SD, Davis DO, Dina TS, Patronas NJ, Wiesel SW, Joint JB, et al. Abnormal magnetic-resonance scans of the lumbar spine in asymptomatic subjects . A prospective investigation Abnormal Lumbar Magnetic-Resonance Spine Scans of the in Asymptomatic. 2006;
  13. Modic MT, Ross JS. Lumbar degenerative disk disease. *Radiology*. 2007;245(1):43–61.
  14. Borenstein DG, O'Mara JW, Boden SD, Lauerman WC, Jacobson A, Platenberg C, et al. The value of magnetic resonance imaging of the lumbar spine to predict low-back pain in asymptomatic subjects : a seven-year follow-up study. *J Bone Joint Surg Am* [Internet]. 2001 Sep [cited 2014 May 23];83-A(9):1306–11. Available from: <http://www.ncbi.nlm.nih.gov/pubmed/11568190>
  15. Modic MT, Ross JS. Lumbar degenerative disk disease. *Radiology* [Internet]. 2007 Oct [cited 2014 Jun 19];245(1):43–61. Available from: <http://www.ncbi.nlm.nih.gov/pubmed/17885180>
  16. A.Bakhsh. Long-term outcome of lumbar disc surgery: an experience from Pakistan. *J Neurosurg Spine*. 2010;12:666–70.
  17. Urban J, Roberts S. Degeneration of the intervertebral disc. *Arthritis Res Ther* [Internet]. 2003 [cited 2014 Nov 1];5(3):120–30. Available from: <http://arthritis-research.com/content/5/3/120>
  18. Lateef H, Patel D. What is the role of imaging in acute low back pain? *Curr Rev Musculoskelet Med* [Internet]. 2009 Jun [cited 2014 May 23];2(2):69–73. Available from: <http://www.pubmedcentral.nih.gov/articlerender.fcgi?artid=2697333&tool=pmcentrez&rendertype=abstract>
  19. Jensen MC, Brant-Zawadzki MN, Obuchowski N, Modic MT, Malkasian D, Ross JS. Magnetic resonance imaging of the lumbar spine in people without back pain. [Internet]. *The New England journal of medicine*. 1994. p. 69–73. Available from: <http://www.ncbi.nlm.nih.gov/pubmed/8208267>
  20. Palepu V, Kodigudla M, Goel VK. Biomechanics of disc degeneration. *Adv Orthop* [Internet]. 2012 Jan [cited 2014 Oct 28];2012:726210. Available from: <http://www.pubmedcentral.nih.gov/articlerender.fcgi?artid=3382964&tool=pmcentrez&rendertype=abstract>
  21. Battié MC, Videman T, Gibbons LE, Fisher LD, Manninen H, Gill K. 1995 Volvo Award in clinical sciences. Determinants of lumbar disc degeneration. A study relating lifetime



- exposures and magnetic resonance imaging findings in identical twins. *Spine (Phila Pa 1976)* [Internet]. 1995 Dec 15 [cited 2014 Oct 29];20(24):2601–12. Available from: <http://europemc.org/abstract/MED/8747238>
22. Adams MA, Freeman BJ, Morrison HP, Nelson IW, Dolan P. Mechanical initiation of intervertebral disc degeneration. *Spine (Phila Pa 1976)* [Internet]. 2000 Jul 1 [cited 2014 Apr 28];25(13):1625–36. Available from: <http://www.ncbi.nlm.nih.gov/pubmed/10870137>
  23. Teritti M, Paajanen H, Laato M, Aho H, Komu M K, M. Disc degeneration in magnetic resonance imaging. A comparative biochemical, histologic, and radiologic study in cadaver spines. *Spine (Phila Pa 1976)*. 1991;16:629–34.
  24. Modic MT, Obuchowski NA, Ross JS, Brant-Zawadzki MN, Grooff PN, Mazanec DJ, et al. Acute low back pain and radiculopathy: MR imaging findings and their prognostic role and effect on outcome. *Radiology* [Internet]. 2005 Nov [cited 2014 May 23];237(2):597–604. Available from: <http://www.ncbi.nlm.nih.gov/pubmed/16244269>
  25. Dominik Weishaupt, Marco Zanetti, Juerg Hodler, Kan Min, Bruno Fuchs, Christian W. A. Pfirrmann NB. Painful Lumbar Disk Derangement: Relevance of Endplate Abnormalities at MR Imaging. *Radiol* 2001218,. 2001;218:420–7.
  26. Saleem S, Aslam HM, Rehmani MA, Raees A, Alvi AA, Ashraf J. Lumbar disc degenerative disease: disc degeneration symptoms and magnetic resonance image findings. *Asian Spine J*. 2013;7:322–34.
  27. Thome C, Borm W MF. Degenerative lumbar spinal stenosis: current strategies in diagnosis and treatment. *Dtsch Arzteblatt Int*. 2008;105(20):373–9.
  28. Biluts H, Munie T AM. lumbar disc diseases at Ethiopia Tikur Anbessa. *Ethiop Med J*. 2012;50(1):57–65.
  29. Takatalo J, Karppinen J, Niinimäki J, Taimela S, Näyhä S, Järvelin M-R, et al. Prevalence of degenerative imaging findings in lumbar magnetic resonance imaging among young adults. *Spine (Phila Pa 1976)*. 2009;34(16):1716–21.
  30. Toyone T, Takahashi K, Kitahara H, Yamagata M, Murakami M, Moriya H. Vertebral bone-marrow changes in degenerative lumbar disc disease. An MRI study of 74 patients with low back pain. *J Bone Joint Surg Br* [Internet]. 1994 Sep [cited 2014 May 23];76(5):757–64. Available from: <http://www.ncbi.nlm.nih.gov/pubmed/8083266>
  31. Shobeiri E, Khalatbari MR, Taheri MS, Tofighirad N, Moharamzad Y. Magnetic resonance imaging characteristics of patients with low back pain and those with sciatica. *Singapore Med J* [Internet]. 2009 Jan [cited 2014 May 23];50(1):87–93. Available from: <http://www.ncbi.nlm.nih.gov/pubmed/19224091>
  32. Siddiqui AH, Rafique MZ, Ahmad MN, Usman MU. Role of magnetic resonance imaging in lumbar spondylosis. *J Coll Physicians Surg Pak* [Internet]. 2005 Jul [cited 2014 May 23];15(7):396–9. Available from: <http://www.ncbi.nlm.nih.gov/pubmed/16197866>