

A Rare Case of Rosacea Rhinophyma in an African Patient.

F.C. Muchemwa^{1,2}, O.B. Chihaka¹, R. Mutasa³, G.I. Muguti¹

¹Department of Plastic and Reconstructive Surgery

²Department of Immunology ,

³Department of Histopathology

University of Zimbabwe College of Health Sciences

Corresponding to: Dr. Faith C Muchemwa, E mail: fcmuchemwa@yahoo.co.uk

Rosacea rhinophyma is an extremely rare entity in the African population; only 4 cases have been reported to date. We report the case of a 72-year-old African man, with a 4 year history of an enlarging nodular mass on the nose. Examination led to the diagnosis of rosacea rhinophyma. A shave procedure using a scalpel was used to excise the phymatous tissue and histological analysis confirmed the diagnosis of rosacea rhinophyma. The patient healed well by epithelialization and was discharged on the 5th day. He was very satisfied with the immediate cosmetic result, however, he defaulted long-term follow-up. We report the first case of rosacea rhinophyma in an African patient in sub-Saharan Africa, and the fifth in the published literature

Key words: Rosacea, Rhinophyma, African

Case report

A 72 year old man, a peasant farmer presented with a 4 year history of progressively enlarging nodules on his nose. The symptoms started insidiously, when the patient noticed some acne-like lesions which produced a foul smelling discharge. Scratching and frequent squeezing resulted in hypertrophic scarring and progressive enlargement of the nose. There was gross disfigurement but the enlarged nose did not affect or compress the nares. Pressure on the acneoid lesions forced out whitish, pasty, and fetid sebum. He had no significant surgical or medical history and was not on any medication. He occasionally took opaque beer and had a 4 pack-year history of cigarette smoking. He was widowed 30 years ago and had remarried; he had a total of 14 children.

On examination he was a healthy elderly man with a non-contributory systemic examination. Local examination showed nodular lesions affecting all aesthetic units of the nose. The largest nodule was on the right alar-nostril and the nasal tip significantly protruded anteriorly. The clinical picture of this patient is shown in Figure 1.

The patient then proceeded to have a shave procedure of the phymatous lesion under general anaesthetic. Meticulous haemostasis was achieved by electrocautery and the patient was dressed with tulle gras for 5 days. The first exposure showed partial epithelialization as shown in Figure 1. The patient was then discharged on day 5 post operatively. Histological examination of the specimen revealed a lesion comprised of hyperplastic sebaceous glands, and distended hair follicles, some of which were distended by keratin. The pilo-sebaceous units were surrounded by an inflammatory infiltrate, comprised of lymphocytes, plasma cells & histiocytes. The dermal matrix showed solar elastosis and only mildly telangiectatic vessels. No granulomata or micro-abscesses were evident.

The appearances were consistent with the phymatous subtype of rosacea (Fig 2). The patient did not report for long-term follow up and attempts to contact him were fruitless.

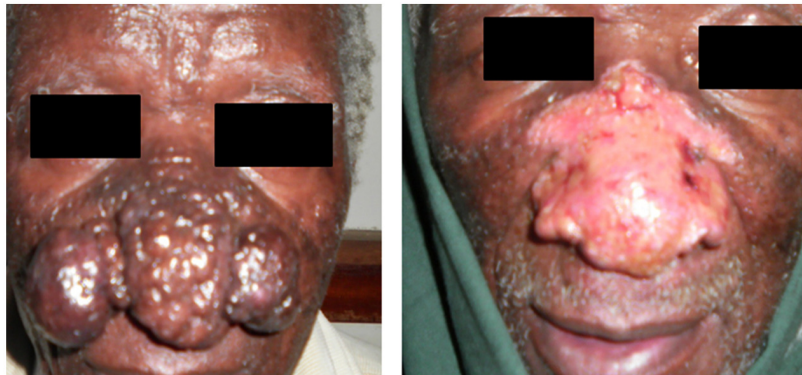


Figure 1. Pre-operative and day 5 post-operative pictures of the phymatous nose.

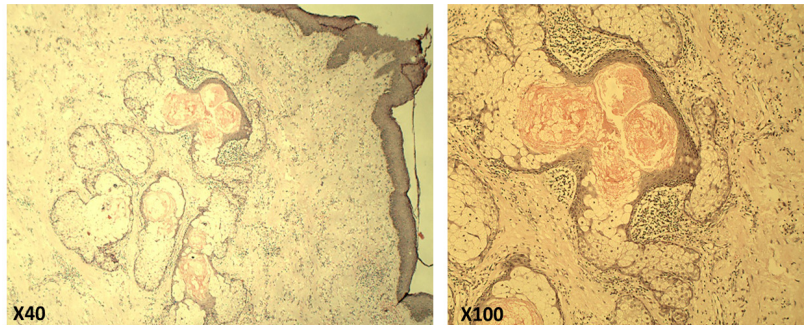


Figure 2. Low and high power fields of a haematoxylin & eosin (H&E) section of the phymatous tissue showing dermal solar elastosis with distended hair follicles & sebaceous glands surrounded by an inflammatory infiltrate of lymphocytes, plasma cells & histiocytes.

Discussion

Rosacea rhinophyma is part of a complex dermatological condition known as rosacea, comprising three main subtypes: the erythemato-telangiectatic, papulopustular, and phymatous type. This is a condition which is common in the Caucasian population and is very rare in the black population. Rosacea is four times more common in Caucasians than in Asians and Africans.

Rhinophyma is generally accepted as being an end stage of acne rosacea, a connection first suggested by Virchow in 1864. Acne rosacea is three times commoner in women than men, whereas the incidence of rhinophyma is nearly twenty times greater in men. This discrepancy may possibly be explained by an androgenic hormonal influence.

There is a very remote risk of malignant transformation in rosacea rhinophyma; Ross and Davies presented a case of squamous cell carcinoma arising from a rhinophyma of 10 years¹,

however, our case was confirmed to be completely benign. There are, however, significant psychological, functional, aesthetic consequences of this condition.

Conventional surgical methods utilize a scalpel, skin graft knife, carbon dioxide laser vaporization^{2,3} electrocautery or cryotherapy. However, disposable shavers were described to be cheap, easy to use and in inexperienced hands, allow for better depth gauging therefore preventing inadvertent cutting of deep tissues⁴. In this case, we used a scalpel and managed to get an excellent result.

Although rosacea rhinophyma is fairly common in fair skinned people of celtic origin, it is uncommon in black people⁵, only 4 cases have been reported in the literature^{6,7,8}. The reason for the racial disparity is not known, but may be related to the way the different races respond to sun damage, as sun damage appears to play an important role. Our patient had significant dermal solar elastosis as illustrated in Fig 2. We report here the 5th case of rosacea rhinophyma in an African patient, and the first to be reported from sub-Saharan Africa.

References

1. DA Ross, MP Davies. Squamous cell carcinoma arising in rhinophyma. *Journal of the Royal Society of Medicine* 1992; 85: 236-37.
2. Roenigk RK. Carbon dioxide laser vaporization for the treatment of rhinophyma. *Mayo Clin Proc* 1987; 62: 676–80.
3. el-Azhary RA, Roenigk RK, Wang TD. Spectrum of results after treatment of rhinophyma with the carbon dioxide laser. *Mayo Clin Proc* 1991; 66: 899–905.
4. Jonathan M Fishman, Sujata Kundu, Mark Draper. 'A close shave' use of a disposable razor blade in the management of rhinophyma. *Ann R Coll Surg Engl* 2009; 91: 161-70.
5. Rosen T, Stone MS. Acne rosacea in blacks. *J Am Acad Dermatol* 1987;17:70-3
6. Allah KC, Kossoko H, Yéo S *et al*, Rhinophyma in a black African male patient. *Rev Stomatol Chir Maxillofac*. 2009;110:347-9.
7. Koffi-Aka V, Kouassi AA, D'Horpock FA *et al*, Rhinophyma in a black African *Rev Laryngol Otol Rhinol (Bord)*. 2002;123:109-10. (Article in French)
8. Redett RJ, Manson PN, Goldberg *et al*. Articles Methods and Results of Rhinophyma Treatment. *Plastic & Reconstructive Surgery* 2001; 107:1115-23.