

## Early Outcome of Mitral Valve Replacement: Results from Chordal Preservation at Muhimbili National Hospital, Tanzania

E.V. Ussiri<sup>1</sup>, W.B.C. Wandwi<sup>1</sup>, E.T.M. Nyawawa<sup>1</sup>, B.J. Nyangassa<sup>1</sup>, B.A. Kamala<sup>2</sup>, N. Satyaki<sup>3</sup>, W. Mahalu<sup>4</sup>

<sup>1</sup>Muhimbili National Hospital, Dar es Salaam, Tanzania. <sup>2</sup>Hubert Kairuki Memorial University, Dar es Salaam – Tanzania. <sup>3</sup>Apollo Hospital, Bangalore – India. <sup>4</sup>Bugando College of Health Sciences, Mwanza - Tanzania

Correspondence to: Dr Ussiri, E-mail: [eussiri@yahoo.com](mailto:eussiri@yahoo.com)

**Background:** Mitral Valve Replacement (MVR) is a common procedure for chronic Rheumatic Heart Disease (RHD) in developing countries. MVR may involve excision of chordae tendinae with leaflet(s) depending on the extent of pathology. Follow up of these patients reveals a progressive Left Ventricle (LV) dilatation, LV dysfunction and low cardiac output syndrome which has been attributed to the loss of annulo-ventricular continuity. Many studies revealed that, preservation of chordae tendinae has a significant role in maintaining post-operative normal LV size and function. The main objective of this study was to determine early outcome of mitral valve replacement among patients operated for Mitral Valve Replacement (MVR) with regards to chordal preservation at Muhimbili National Hospital

**Patients and Methods:** All patients admitted in the Cardiothoracic Unit, Muhimbili National Hospital for Mitral Valve Replacement from November 2011 to November 2013. Detailed echo was done pre-and post-operatively and New York Heart Association class (NYHA) assessment were recorded. Intra-operative valve assessment was done and categorized into; Total Chordal Excision (TCE), Posterior Mitral Leaflet (PML) preservation or Total Chordal Preservation (TCP). Patients were followed up at one month for control echo and NYHA assessment

**Results:** A total of 59 patients were recruited, male accounting for 31.7% and female 68.3% with age ranging from 10 years to 58 years. Indications for surgery were; severe mitral valve stenosis (MS)-33.2%, severe mitral valve regurgitation (MR)-35.6% and severe mixed mitral valve disease (MMVD)-32.2%. Among all patients, 45.8% had calcified leaflet(s) and 30.55% had atrial fibrillation. TCE was done in 22 patients (37.3%), PML in 21 patients (35.6%) and TCP in 16 patients (27.1%). There was a significant increase in End Diastolic Volume (EDV) and End Systolic Volume (ESV) with decrease in Ejection Fraction (EF) post-operatively in the TCE group ( $p=0.024$ ,  $0.001$  and  $0.000$  respectively), a significant decrease in EDV and ESV in PML preservation ( $p=0.001$  and  $0.002$  respectively), increase in EF ( $p=0.004$ ) and a significant decrease in EDV in TCP group ( $p=0.008$ ), increase in EF ( $p=0.016$ ).

### Conclusion and Recommendation

- Chordal Preservation in chronic rheumatic Mitral Valve Replacement is encouraged
- Chordal Preservation plays a significant role in the reduction of Left Ventricular volumes and improvement in ventricular function
- A larger scale study with longer follow up is required

**Key Words:** Mitral Valve Replacement, Chordal Preservation, Early Outcome

### Introduction

Mitral Valve Replacement is a common procedure for chronic Rheumatic Heart Disease (RHD) in developing countries. The commonest indications includes; severe Mitral Valve Stenosis,

severe Mitral Valve Regurgitation and severe mixed Mitral Valve Disease.<sup>1,2,3</sup> Mitral Valve Replacement may involve excision or sparing of chordae tendinae with the accompanying leaflet(s) depending on the extent and severity of the pathology. Follow up of these patients reveals a progressive Left Ventricle (LV) dilatation, LV dysfunction and low cardiac output syndrome which has been attributed to the loss of annulo-ventricular continuity<sup>4,5,6,7</sup>.

Many studies revealed that, preservation of chordae tendinae has a significant role in maintaining post-operative normal LV function despite whether partial or complete preservation<sup>4,5,6,7</sup>. There are many techniques used in chordal preservation but, no one is superior to the other ones in terms of their outcome and therefore, Surgeon's choice<sup>5,8</sup>. The prospective study was done to evaluate early Left Ventricular functions and NYHA class following Mitral Valve Replacement at Muhimbili National Hospital, MNH.

### **Patients and Methods**

A prospective study was done for two years from November 2011 to November 2013 to analyze 59 patients, 19 males and 40 females admitted for MVR in the Cardiothoracic Unit at MNH following Cardiac Panel. Both sexes and all age groups were included. Informed consent was obtained from all patients. Detailed pre-operative echo findings were recorded including Left Atrial (LA) diameter, left ventricular diastolic diameter (LVDD), left ventricular systolic diameter (LVSD), end diastolic volume (EDV), end systolic volume (ESV), pulmonary hypertension (PHT) and ejection fraction (EF). Pre-operative NYHA class was recorded and cardiac profile work-up was completed.

### ***Surgical Technique***

Standard Cardio-Pulmonary By-Pass (CPB) with cold blood cardioplegia and moderate hypothermia was used.

Mitral Valve was approached through the left atrium and assessment was done to determine type of chordal preservation as follows;

- Total Chordal Excision (TCE) – whole valve was fibrotic, stenotic and fixed with calcifications extending to the chorda tendinae and papillary muscles
- Posterior Mitral Leaflet (PML) preservation – posterior mitral leaflet is thickened, fibrotic and fixed but, not calcified
- Total Chordal Preservation (TCP) – both leaflets are mobile but, thickened edges, retracted and nodular, not possible for repair
- Finally, standard Mitral Valve Replacement and weaning from CPB was completed. Left atrial appendage was ligated for 18 patients who had atrial fibrillation, All 100 patients were followed up after one from discharge. Postoperative echo and NYHA class were recorded. Data was analyzed using SPSS 22 program. Exclusion criteria included all patients who underwent double valve replacement, all patients with incomplete echo reports and those who died one month before surgery.

### **Results**

A total of 59 patients (100%) were recruited in this study. Male patients accounted for 31.7% and female 68.3% with age ranging from 10 years to 58 years. Majority of patients (81.7%) were below 40 years of age (Table 1). Ten patients were excluded; 3 had double valve replacement, two died within 24 hours of operation due to low cardiac output syndrome despite high dose inotropic support and 5 had incomplete echo report.

All patients (100%) operated for mitral valve replacement had echocardiographic features of severe chronic rheumatic heart disease presenting with severe mitral valve stenosis (33.2%), severe mitral valve regurgitation (35.6%) and mixed mitral valve disease (32.2%) with NYHA IV. Among all patients, 45.8% had calcified valve and 30.5% had atrial fibrillation. Considering type of procedure done, Total Chordal Excision accounted for 37.3% due to severe fibrosis and calcification, Posterior Mitral Leaflet preservation were 35.6% and Total Chordal Preservation were 27.1% (Table 2, Fig 1). All these patients present with severe symptoms, NYHA class IV . There was no significant difference between the indication of operation and type of operation done,  $p = 0.605$  (Table 3)

**Table 1** Background characteristic of patient

Age group(yrs)	Number	(%)
10 -19	19	33.3
20 -29	13	21.7
30 -39	16	26.7
40+	11	18.3
<b>Total</b>	<b>59</b>	<b>100</b>
<b>Sex</b>		
<b>Male</b>	19	31.7
<b>Female</b>	40	68.3
<b>Total</b>	<b>59</b>	<b>100</b>

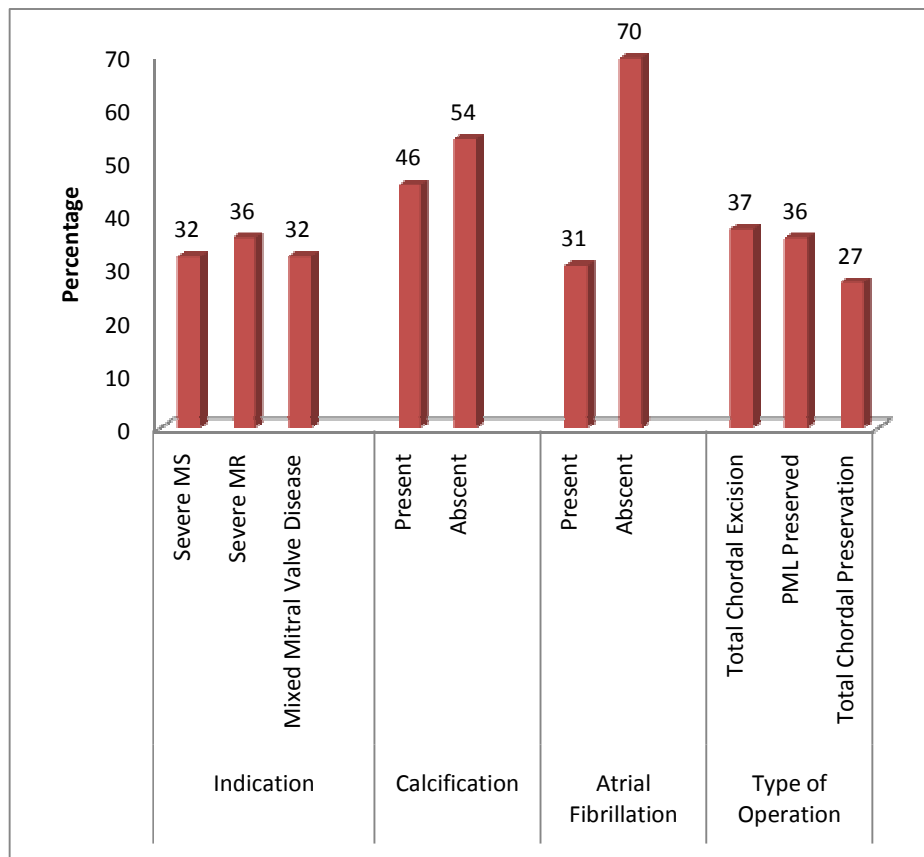
**Table 2.** Proportion for Indication, Calcification, Atrial Fibrillation and Type of operation

	Number	(%)
<b>Indication</b>		
<b>Severe MS</b>	19	32.2
<b>Severe MR</b>	21	35.6
<b>Severe MMVD</b>	19	32.2
<b>Total</b>	<b>59</b>	<b>100</b>
<b>Calcification</b>		
<b>Yes</b>	27	45.8
<b>No</b>	32	54.2
<b>Atrial Fibrillation</b>		
<b>Yes</b>	18	30.5
<b>No</b>	41	69.5
<b>Type of Operation</b>		
<b>TCE</b>	22	37.3
<b>PML</b>	21	35.6
<b>TCP</b>	16	27.1
<b>Total</b>	<b>59</b>	<b>100</b>

**Table 3.** Indication versus Type of Operation

Indication/Type	Total Chordal Excision (%)	PML Preservation (%)	Total Chordal Preservation (%)	Total
Severe MS	11 (55.0)	3 (15.0)	6 (30.0)	20 (100)
Severe MR	6 (30.0)	8 (40.0)	6 (30.0)	20 (100)
Severe MMVD	5 (26.3)	10 (52.6)	4 (21.1)	19 (100)
<b>Total</b>	<b>22 (37.3)</b>	<b>21 (35.6)</b>	<b>16 (27.1)</b>	<b>59 (100)</b>

p = 0.605



**Figure1.** Proportion of Indication, Calcification, Atrial Fibrillation and Type of Operation

Current study showed a significant decrease in the mean overall diameter of left atrium from 6.2cm, std=1.4 to 4.7cm, std=1.0 (p=0.000), left ventricle diastolic diameter from 5.2cm, std=1.1 to 4.4cm, std 0.9 (p=0.000), left ventricle systolic diameter from 3.5cm std=0.9 to 3.0cm, std=0.9 (p=0.000), end-diastolic volume from 109ml, std=51.4 to 95.7ml, std= 40.8 (p=0.000), no significant change in the end-systolic volume, from 55.7ml std=29.1 to 56.6ml std=26.8 (p=0.502), pulmonary hypertension decreased significantly from 75.4 mm Hg, std=23.1 to 57.7mmhg, std= 18.9 (p= 0.000) and NYHA improved from class IV std=0.652 to class II std=0.642 (p=0.000) following mitral valve replacement(Table 4) . All patients had severe pulmonary hypertension and therefore, long term follow up is required to determine its outcome as well as the end-systolic volume which had no significant change.

There was a significant increase in end-diastolic volume ( $p=0.024$ ) and end-systolic volume ( $p=0.000$ ) which was accompanied by decrease in the Ejection Fraction ( $p=0.000$ ) in the Total Chordal Excision group compared to the preserved groups both Posterior Mitral Leaflet and total chordal preservation which showed remarkable improvement in the Ejection Fraction ( $p=0.004$  and  $0.016$  respectively). No significant difference was found in the end systolic volume among patients who underwent total chordal preservation. All patients had improved NYHA post-operatively in all groups but, a long follow -up is required to evaluate the effect on TCE. There was no significant improvement in ESV from the TCP ( $p=0.717$ ) and this will need a long follow up (Table 5). Four patients of out of 69 operated patients died making an overall mortality rate for mitral valve replacement of 5.8%.

**Table 4.** Overall Mean Echo and NYHA Comparison before and after Operation

LV diameter/ Function	Mean Before Operation (Std Deviation)	Mean after Operation (Std Deviation)	p-value
LA (cm)	6.2 (1.4)	4.7 (1.0)	0.000
LVDD (cm)	5.2 (1.1)	4.4 (0.9)	0.000
LVSD (cm)	3.5 (0.9)	3.0 (0.9)	0.000
EDV (cm)	109 (51.4)	95.7 (40.8)	0.004
ESV (cm)	55.7 (29.1)	56.6 (26.8)	0.502
PHT (mmhg)	75.4 (23.7)	57.7 (18.9)	0.000
EF (%)	62.3 (13.5)	62.3 (13.5)	0.779
NYHA (class)	4 (0.652)	2 (0.642)	0.000

**Table 5.** Mean Echo Findings versus Type of Operation

MeanEcho/ Type of Operation	Total Chordal Excision			PML Preservation			Total Chordal Preservation		
	Pre-Op mean (SD)	Post-Op mean (SD)	p-value	Pre-Op mean (SD)	Post-Op mean (SD)	p-value	Pre-Op mean (SD)	Post-Op mean (SD)	p-value
LA	6.3 (1.3)	4.9 (0.9)	0.001	6.3 (1.8)	4.7 (1.2)	0.001	6.10 (1.16)	4.4 (1.0)	0.001
LVDD	4.9 (0.9)	4.5 (0.8)	0.001	5.7 (1.3)	4.3 (0.8)	0.001	5.2 (0.9)	4.3 (1.1)	0.008
LVSD	3.3 (0.7)	2.9 (0.7)	0.016	3.7 (1.0)	2.9 (0.8)	0.001	3.4 (0.9)	3.2 (1.2)	0.244
EDV	90.8 (26.2)	103.3 (47.5)	0.024	118.8 (70.6)	93.9 (44.4)	0.001	113.8 (44.4)	87.7 (22.3)	0.008
ESV	47.5 (22.8)	59.5 (26.8)	0.001	64.9 (30.7)	54.5 (26.2)	0.002	54.9 (33.2)	55.3 (28.9)	0.717
PHT	77.8 (21.2)	68.7 (17.7)	0.000	72.3 (22.9)	52.2 (16.1)	0.000	76.0 (28.0)	49.8 (17.6)	0.000
EF	65.6 (15.3)	55.1 (9.6)	0.000	61.4 (9.1)	66.2 (8.1)	0.004	58.9 (15.9)	65.9 (6.5)	0.016
NYHA	4 (0.7)	2 (0.6)	0.000	4 (0.6)	2 (0.6)	0.000	4 (0.5)	2 (0.7)	0.000
Mortality		2							

## Discussion

Chronic rheumatic heart disease still is a major problem in developing countries and surgical intervention is the definitive treatment of choice <sup>1,2,3,9</sup>.

Chordal transection during mitral valve replacement is accompanied by a progressive dilatation of the left ventricle and subsequently, left ventricular dysfunction and low cardiac output syndrome which has been attributed to the loss of annulo – ventricular continuity. Therefore, maintaining the geometrical anatomy of the left ventricle during mitral valve replacement plays a key role in determining post-operative normal left ventricular dimensions and function. Several studies found that preservation of at least Posterior Mitral Leaflet or both have a significant impact on the improvement of the left ventricular functions following mitral valve replacement <sup>4,5,6,7,8</sup>.

Rozich et al <sup>10</sup> evaluated 15 patients who underwent mitral valve replacement for pure mitral valve regurgitation and found a significant decrease in ejection fraction, significant increase in the left ventricle end systolic volume and no change in the left ventricle end diastolic volume in the chordal transected group when compared to the preserved group which revealed a significant decrease in the left ventricle end diastolic and systolic volumes with unchanged ejection fraction

Zakai et al <sup>7</sup> did an echo at discharge and six month following mitral valve replacement and found that the preserved groups (posterior mitral leaflet and total chordal preservation) had remarkable improvements in terms of EDV and ESV. EF remained the unchanged in all groups at discharge but improved progressively at six month of follow up. Similar improvement in the size of LA, PHT and NYHA

Garcia-Fuster et al <sup>11</sup> found that complete excision of the Chordae was associated with low cardiac output syndrome ( $p < 0.01$ ) and more patients in NYHA III and IV ( $p = 0.001$ ) compared to the preserved groups, posterior mitral leaflets and total chordal preservation who had significant reduction in ventricular volumes, EF and PHT. Rao et al <sup>12</sup> evaluated the impact of subvalvular apparatus preservation on long term outcomes for 10 years and found that preserved group survived longer than unpreserved group (65.7% vs 58.1% respectively)

Shah et al <sup>13</sup> studied on LV dimension changes after chordal preservation in mitral valve replacement and no significant change was found in median size of LA in both groups but, LV EDV and LV ESV remained the same or increased where no chorda was preserved and decreased where the chorda was preserved

Morimoto et al <sup>14</sup> did a study on mid-term echo comparison of chordal preservation following mitral valve replacement at 4 years and found a significant improvement in the EF in the total chordal preservation ( $p = 0.017$ ) and posterior mitral leaflet preservation (0.025) and significant decrease in EF in the total chordal excision group (0.036) which was accompanied by a significant increase in EDV ( $P = 0.005$ ) and ESV ( $p = 0.001$ )

Current study has findings which are comparable to the other studies although a long-term follow up with bigger sample size will be required




## Conclusion and Recommendation

- Chordal Preservation in chronic rheumatic Mitral Valve Replacement is encouraged
- Chordal Preservation plays a significant role in the reduction of Left Ventricular volumes and improvement in ventricular function
- A larger scale study with longer follow up is required

## References

1. Marcus RH, Sareli P, Pocock WA, Berlow JB. The Spectrum of Severe Rheumatic Mitral Valve Disease in Developing Countries. Correlation among Clinical Presentation, Surgical Pathologic findings and Haemodynamic Sequelae. *Annals of Int. Medicine* 1994;120(3): 177 - 183
2. Marijon E, Celermaer DS, Tafflet M, El-Haron S, Jani DN, Ferreira B, Mocumbi A, Paquet C, Sidi D, Jouven X. Rheumatic Heart Disease Screening by Echo. *Circulation* 2009;120: 663-668
3. Nyawawa ETM, Ussiri EV, Wandwi WBC, Mpoki U, Lugazia E, Waane T, Mlay G, Bgoya J and Mahalu W. Cardiac Surgery: One- Year experience at Muhimbili National Hospital. *East & Central African J Surgery* 2010; 15: 111-118
4. Athanasion T, Chow A, Rao C, Aziz O, Siannis F, Ali A, Darzi A, Wells F. Preservation of the Mitral Valve Apparatus: Evidence synthesis and critical re-appraisal of surgical techniques. *Eur J Cardiothorac Surg* 2008; 33 (3): 391 - 401
5. Talwar S, Venkataiya H, Kumar J, Kumar AS. Review Article: Chordal Preservation during Mitral Valve Replacement: basis, techniques and results. *Indian J Thoracic Cardiovasc Surg* 2005; 21: 45 -52
6. Thomas W, Sven L, Volkmar F, Claudia W, Nico D, Ardawan R, Sebastian M, Johannes S, Jan G, Friedrich W. Mid-Term Results after Stentless Mitral Valve Replacement. *Circulation* 2003;108: 85 - 89
7. Zakai SB, Khan SU, Rabbi F, Tasneem H. Effects of Mitral Valve Replacement with or without chordal preservation on Cardiac Function: Early and Mid-Term Results. *J Ayub Med Coll Abbottabad* 2010; 22(1): 91-96
8. Choudhary UK, Kumar AS, Airan B, Mittal D, Subramaniam KG, Prakash R, Seth S, Singh R, Venugopal P. Mitral Valve Replacement with or without chordal preservation in a rheumatic population: Serial Echocardiographic assessment of Left Ventricle size and function. *Ann Thorac Surg* 2005; 79 (6): 1926 -33
9. Bonow RO, Carabello BA, Kanu C, Antonio C, Faxon DP, Gaasch WH, Lyte BW, Nishihura RA, Patrick TO, Robert AO, Otto CM, Shah PM, Shanewise JS. ACC/AHA 2006 Guidelines for the management of patients with valvular heart disease: a report on the American College of Cardiology/American Heart Association Task Force on Practice guidelines. *Circulation* 2006; 114: 84 - 231
10. Rozich JD, Carabello BA, Usher BW, Kratz JM, Bell AE, Zile MR. Mitral Valve Replacement with and without chordal preservation in patients with chronic Mitral Regurgitation. Mechanisms for differences in post-operative ejection performance. *Circulation* 1992; 86: 1718 - 26
11. Garcia-Fuster R, Estevez V, Gil O, Canovas S, Martinez-Leon J. Mitral Valve Replacement in Rheumatic patients: Effect of Chordal Preservation. *Ann Thorac Surg* 2008; 86: 472 - 81
12. Rao C, Hart J, Chow A, Siannis F, Tsalafouta P, Murtuza B, Darzi A, Wells FC, Athanasion T. Does Preservation of the subvalvular apparatus during mitral valve replacement



- affect long-term survival and quality of life? A Microsimulation Study. *J Card Thorac Surg* 2008; 3: 3-17
13. Shah S, Ghosh PK, Das A, Chandra M, Agarwal SK, Mittal PK, Krishn SR. Left Ventricle dimension changes after chordal preservation in Mitral Valve Replacement. *Indian J T Cardiovasc Surg* 1991; 7(1): 27 – 32
  14. Morimoto N, Aoki M, Murakami H, Nakagiri K, Yoshida M, Mukohara N. Mid-Term Echocardiographic comparison of Chordal Preservation Method of Mitral Valve Replacement in patients with Mitral Stenosis. *Heart Valve Disease* 2013; 22 (3): 326 - 332