

Biochemical Analysis of Hydrocele fluid in Males with hydrocele in a Filariasis endemic Community: An experience at surgical camp in Tanga

Mchembe M.D, Mwanga A, Ramadhan H

Department of Surgery- MUHAS, Dar es Salaam - Tanzania

Correspondence to: Mabula Mchembe, Email: mchembem@gmail.com

Background: Adult hydrocele is a very common urological disease in most of the sub-Saharan African countries; the reported incidence of adult hydrocele is up to 20–28% in some lymphatic filariasis endemic communities. The associated economic burden involved with the treatment of hydrocele can be significant in these mostly poor resource economies. There is shortage of published data regarding biochemical analysis of hydrocele fluids in Tanzania and the study area in particular. This study was conducted in our local setting in an endemic filariasis affected area to describe and highlight the biochemical component of adult male hydrocele fluid, the clinical appearance of the hydrocele fluid and tunica vaginalis at operation.

Methods: This was cross-sectional descriptive study, done at Pangani to all patients seen at the camp in the year 2011 and found to have hydrocele in one or both sides. Demographic data were entered, necessary investigations were taken and patients were scheduled for operation. Statistical data analysis was performed using SPSS version 17.0.

Results: A total of 81 patients were studied, all being Males. The commonest age of patients at diagnosis was ≥ 60 years (39%) followed by the age range between 20 – 45 years (34%). Majority of patients had their disease duration of < 5years (41 patients) followed by patients with the disease > 10 years (22 patients). In terms of location of the hydrocele, most of the patients had their disease located on the left side (24 patients) followed by those with bilateral disease (22 patients). The clinical hydrocele fluid appearance at operation was found to be straw coloured in the majority of cases (48 patients), followed by the clear yellow fluid (19 patients). For the tunica vaginalis characteristics at operation, 34 patients (the majority) had thin and soft tunica vaginalis. Most of the electrolytes tested in hydrocele fluid (Na^+ , K^+ , Ca^{2+} and Cl^-) were found to be within normal range with the known serum normal levels.

Conclusions: Biochemical electrolyte composition of adult male hydrocele fluid in filariasis endemic area community is almost similar to normal serum major electrolytes.

Key words: Adult male hydrocele fluid, biochemical analysis in an endemic filariasis community, surgical camp, Tanzania.

Introduction

A hydrocoele is an abnormal accumulation of fluid most commonly occurring in the scrotum in men, or the labia majora in women. Hydroceles can be classified as either primary (congenital) or secondary (acquired) based on the time at onset, and also can be classified as communicating (if processus vaginalis is communicating with the peritoneal cavity) and non-communicating (if limited to the scrotum and no communication with the peritoneal cavity)^{1,2,3}.

Non-communicating type of hydrocele is caused by an imbalance between secretion, absorption and drainage of fluid in the scrotal sac. Increased scrotal fluid secretion may be caused by local inflammation of the testis and epididymis from bacteria or viruses, while poor absorption commonly results from men and thickening of the sac or lymphatic malfunction^{4,5}. Noncommunicating hydroceles are the most common^{5,6,7,8,9} type of hydrocoele globally, affecting more than 30 million boys (WHO 2013).

Adult hydrocoele is a very common urological disease in most of the sub-Saharan African countries; the reported incidence of adult hydrocoele is up to 20–28% in some lymphatic

filariasis endemic communities. The associated economic burden involved with the treatment of hydrocoele can be significant in these mostly poor resource economies^{2,3,4}.

Hydrocoele is the commonest manifestation of bancroftian filariasis among males and filarial hydrocoele and chylocoele account for up to 80% of hydrocoele in endemic areas. Hydrocoele fluid is similar to other tissue fluids in the body, such as peritoneal fluid. It is a solution of mostly water, electrolytes, and protein. A 1994 study revealed that hydrocoele fluid had higher levels of calcium, albumin, total protein and creatine-kinase, and lower levels of potassium, aspartate transaminase, and alkaline phosphatase than blood serum. The hydrocoele fluid itself is amber in colour and the sediment shows a characteristic predominance of vacuolated mesothelial cells, fibrin, old blood clots, cholesterol clefts, and calcium dust^{10,11,12,13}].

Clinico-Pathologically filarial infection related hydrocoele it is characterized by a distended, generally thickened tunica vaginalis with hyalinization and fibrosis of the subserosal layer, disorganization of the muscle layers, lymphoid and foreign-body giant cell infiltration, and, in extreme cases, calcification^{5,6,7,8,9}.

Pathogenesis of secondary hydrocoele follows obstruction of the testicular venous or lymphatic vessels is associated with acute hydrocoele development. Venous or lymphatic obstruction can be caused by torsion of the testicle, lymphoma, or the death of parasitic filarial worms. In the temperate climates of Europe, North and South America, and China, most primary hydroceles of adult males are idiopathic. In tropical regions, mainly in LMICs, lymphatic filariasis (LF) is the most significant risk factor for the development of noncommunicating hydrocoele. LF is caused by infection with the mosquito-borne worm, *Wuchereria bancrofti* (Michael, Bundy, and Grenfell 1996; WHO 2005). LF is a complex disease affecting several parts of male genital anatomy. The biological predilection of the adult filarial worms to live and reproduce in the lymphatic channels of the scrotum means that greater than 50 percent of infected men will, with age, develop chronic hydrocoele (Addiss and others 1995; Eigege and others 2002; Mathieu and others 2008). Hydroceles caused by LF are sometimes called *filariaceles*. In tropical or subtropical zones, the *Culex*, *Aedes*, and *Anopheles* mosquitoes carry the filarial parasite. The cycle of infection requires that mosquitoes deposit larvae on the host skin, and these migrate through the puncture site to the venous system and lymphatics, where they mature into adults. Nests of the male and female adults are most commonly identified in the male scrotal lymphatics, where they produce the first-stage larvae (microfilariae) that are subsequently consumed by mosquitoes^{5,6,7}.

Cystic swellings of the scrotum are invariably painless and can attain very large size without causing much discomfort to the patient. However, these are a common surgical problem which affects the physical wellbeing of the patient, it is rather a mental agony for him. These swellings are easily accessible for clinical examination Indication for treatment includes pain, discomfort and the cosmetic appearance of the scrotum or the patients wish^{6,7,8,9}. The spectrum consists of hydrocoele, epididymal cysts, spermatocele, hemocele, pyocele, chylocele, parasitic cyst and sebaceous cysts.

There is lack of information regarding biochemical electrolyte components of hydrocoele fluids in Tanzania and the study area in particular. This is partly due to a lack of published local data regarding these fluids. This study was designed to describe the electrolyte components in hydrocoele fluids and the clinicopathological appearance of fluid and tunica vaginalis in a filarial endemic community. The main objective of this study was to analyze the electrolyte components of hydrocoele fluid and clinico-pathological appearance of the fluid and tunica vaginalis in an endemic filarial community. The specific objectives were to determine the age and duration of hydrocoele among operated patients in an endemic filarial community.

The study was further aimed at:

1. Determining the characteristics of hydrocoele fluid and tunica vaginalis in an endemic filarial community
2. Establishing the common site and duration of hydrocoele in an endemic filarial community
3. Determining the levels of common electrolytes in hydrocoele fluid in an endemic filarial community

Patients and Methods

This was a prospective descriptive cross-sectional study of consecutive series of 81 male adult patients with hydrocoele seen and operated at the five days surgical camp conducted in Pangani-Tanga in September 2011. All male adult patients seen at the camp and found to have hydrocoele in one or both sides of the scrotum were included. Patients with hydrocoele secondary to ascites, congestive heart failure, of acute onset, and those of pediatric ages less than 18 years were excluded from this series. It is assumed that most of the cases were of filarial origin based on history and physical examinations and on the fact that the hospital catchment area of this study is mostly in the coast area and is considered an endemic region for lymphatic filariasis.

Preoperative evaluation included detailed history of the disease and included questions on onset of illness, duration, presence of pain and other relevant medical history. All the patients had preoperative physical examination of the scrotum, lower extremities and inguinal regions, hemoglobin levels, serum blood sugars and urinalysis was ordered as routine tests. The patients were counseled and went ahead to have hydrocelectomy using the partial excision technique. The main indication for surgery was the patient's desire mostly due to the large size of the hydrocoele.

At operation, Aseptic technique was used to prepare the operative area and Local anesthesia was used (lignocaine +/- sedation), lateral or Midline raphe longitudinal incision was made and hydrocoele was identified and dissected out with intact tunica vaginalis. Sterile Syringe 10ml and needle used was used to draw fluid from the tunica Vaginalis. About 10 ml hydrocoele fluids was drawn, put in Vacuntainer sterile bottle and stored in Refrigerator at 8°C and samples were sent for biochemical analysis. Appearance of fluid and status of the tunica vaginalis was recorded.

Statistical data analysis was performed using statistical package for social sciences (SPSS) version 17.0 for Windows (SPSS, Chicago IL, U.S.A). The median + (IQR) and ranges were calculated for continuous variables whereas proportions and frequency tables were used to summarize categorical variables. Chi-square (χ^2) test were used to test for the significance of association between the independent (predictor) and dependent (outcome) variables in the categorical variables. The level of significance was considered as $P < 0.05$. Multivariate logistic regression analysis was used to determine predictor variables that predict the outcome.

Results

In reference to table above, there was no significant association between patients age groups with duration of their disease as it is shown by $X^2 = 2.8$ and $p\text{-value} = 0.59$. Table 2, shows the relationship between duration disease and site (location) of the hydrocoele and it was revealed that there was an association as evidenced by $X^2 = 12.4$ and $p\text{-value} = 0.02$. Table 3, shows there was no association between duration of disease and fluid type whether straw or yellow as revealed by $X^2 = 2.7$ and $p\text{-value} = 0.6$.

Table 1. Age Groups in Relation to Duration of Illness in Years

Age	≤5 yrs	5-10 yrs	≥10 yrs	Total
20-45	14(34.2%)	6 (33.3%)	7(31.8%)	27 (33.3%)
45-60	11(26.8%)	8 (44.4%)	9 (40.9%)	28 (34.8%)
≥60	16(39%)	4 (22.3%)	6 (27.3%)	26 (32.1%)
Total	41 (100%)	18 (100%)	22 (100%)	81 (100%)

Table 2. Duration of Disease in Relation to Location of Hydrocele

Duration	Right	Left	Bilateral	Total
≤5	8 (53.3%)	17 (70.8%)	16 (38.1%)	41 (50.6%)
5-10	4 (26.7%)	8 (25%)	9 (19%)	18 (22.2%)
≥10	3 (20%)	4 (4.2%)	6 (42.9%)	22 (27.2%)
Total	15 (100%)	24 (100%)	22 (100%)	81(100%)

Table 3. Duration of Illness in Relation to Fluid Type of Hydrocele

Duration	Straw	Clear yellow	Thick yellow	Total
≤5	22(45.8%)	12 (63.2%)	7(50%)	41 (50.6%)
5-10	12(25%)	4(21.1%)	2 (14.3%)	18 (22.2%)
≥10	14(29.2%)	3(15.7%)	5 (35.7%)	22 (27.2%)
Total	48 (100%)	19 (100%)	14 (100%)	81 (100%)

Table 4. Duration of Disease in Relation to Tunica Characteristics

Duratio	Soft & thin	Thick & hard	Calcified	Total
≤5	20(58.8%)	14 (51.9%)	4 (20%)	18 (22.2%)
5-10	6(17.7%)	8(29.6%)	7(35%)	41 (50.6%)
≥10	8(23.5%)	5(18.5%)	9 (45%)	22 (27.2%)
Total	34 (100%)	27 (100%)	20 (100%)	81 (100%)

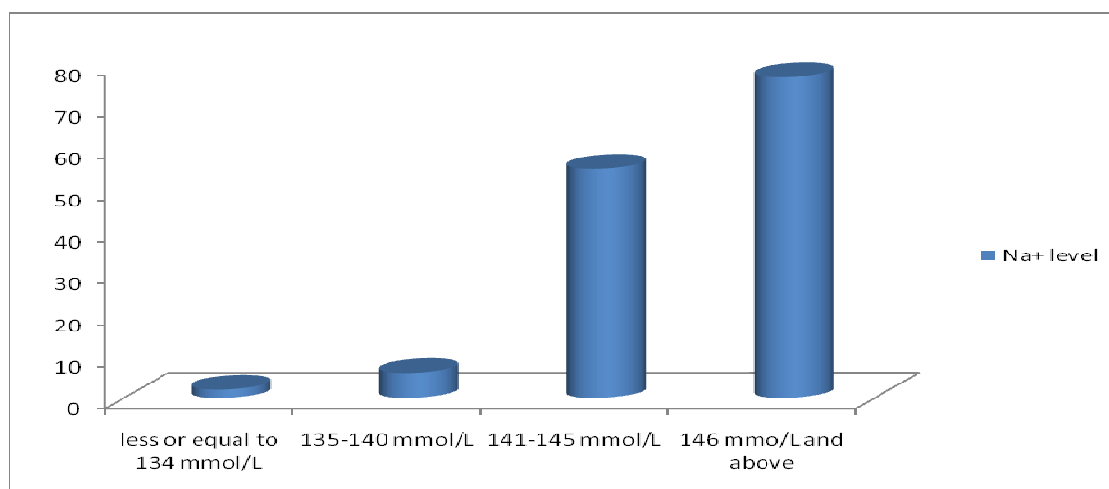


Figure 1: Sodium level

Table 4 shows that there was no significant association between duration of disease and tunica characteristics of the hydrocele as shown by $\chi^2= 5.7$ and $p\text{-value}= 0.2$.

Electrolytes level found on hydrocele

As shown from the figure above, equal and above 146 mmol/L was a commonest sodium level found to patients with hydrocele followed by 141-145 mmol. From figure 2, it is shown that 4.6-5.1 mmol/L was the highest level of potassium found to majority of patients with hydrocele. The highest chloride level found in the majority of patients with hydrocele was 108 mmol/L and above as it is revealed by the figure above. As shown from figure 4, equal and above 2.65 mmol/L was a highest calcium level found to most of patients with hydrocele.

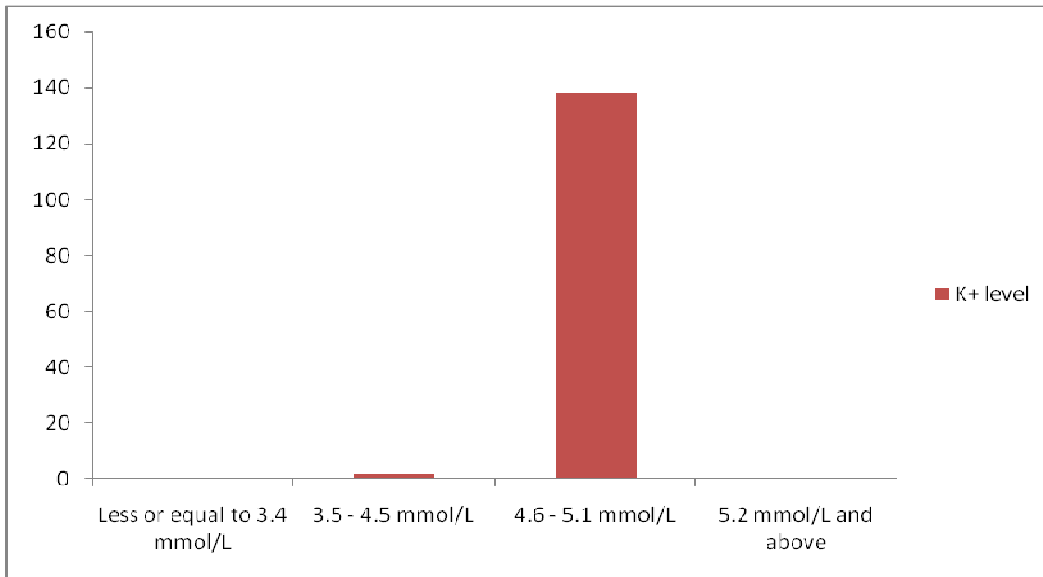


Figure 2: Potassium level

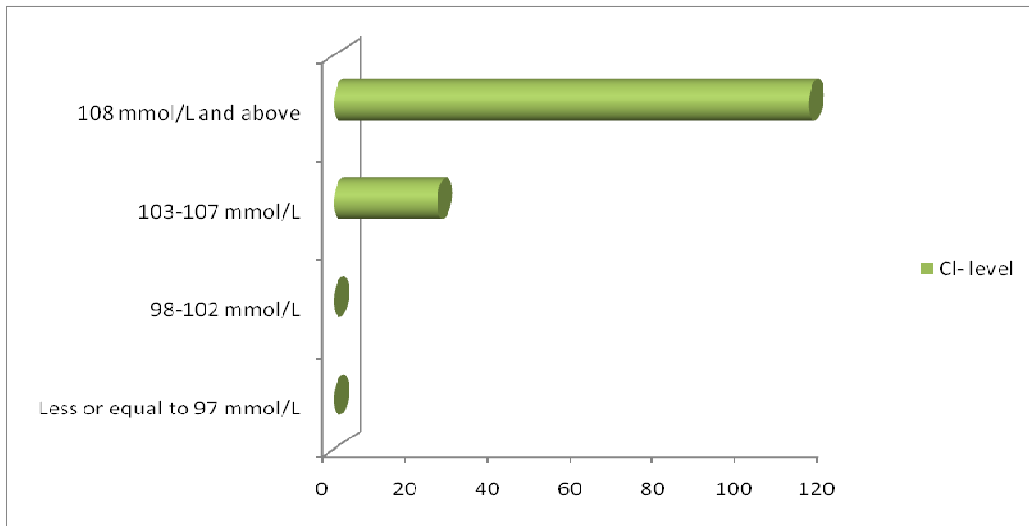


Figure 3. Chloride level

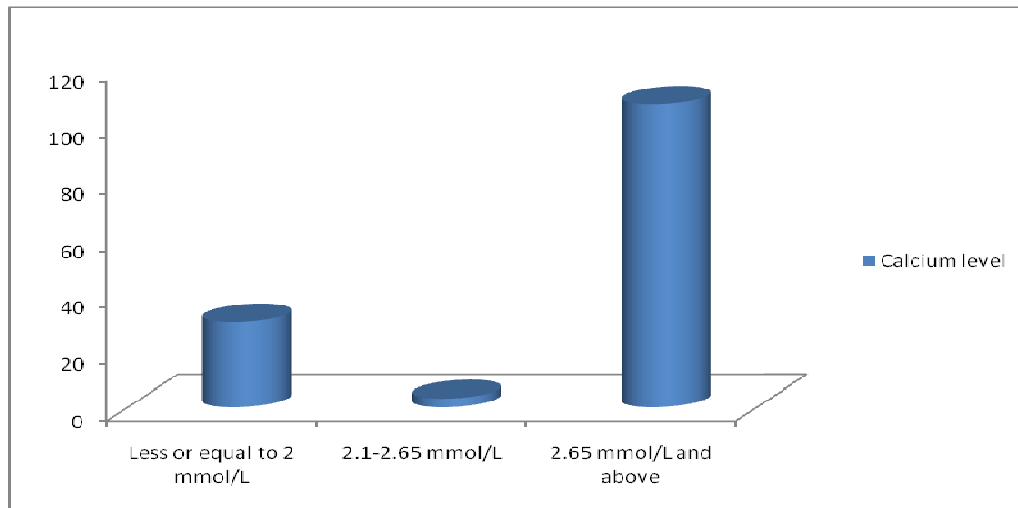


Figure 4. Calcium level

Discussion

In this study, 81 patients were operated for scrotal hydrocele. None of these patients on preoperative evaluation or on surgical exploration was diagnosed with a more serious underlying pathology. The importance of detailed history of illness and good physical examination cannot be underestimated. In this study, only history and physical examination was used to diagnose hydrocele and plan surgery for the diagnosed patients. This is different from other study⁴ whereby transillumination tests and scrotal ultrasound is insisted to be done before surgery. Transillumination tests are not very useful in dark skin individuals and ultrasound is also expensive to conduct in low social income societies. Therefore clinical acumen is highly needed for the diagnosis and final decision on the treatment of these patients.

The commonest age of patients at diagnosis was ≥ 60 years (39%) followed by the age range between 20 – 45 years (34%). Majority of patients had their disease duration of < 5years (41 patients) followed by patients with the disease > 10 years (22 patients). Age groups in relation to the duration of the disease, in this study showed no any association. Hence, it seems that longstanding hydroceles are mostly benign in nature possibly in contrast to hydrocele of acute onset.

Duration of the disease with respect to location of the hydrocele, findings on this study shows that many patients had left sided hydroceles followed by bilateral hydrocele at the duration of less or equal to five years. This can possibly be explained that those who had their disease at that duration and location of hydroceles turned up well for the surgical camp than others.

Clinical appearance of the hydrocoele fluid at operation in this study showed that majority of patients had straw coloured and clear yellow fluid; this is the same findings as reported by Nazim and Devries et al. The tunica vaginalis was found to be soft and thin among the majority of the patients operated in this study. This could be due to the short duration of the illness among these patients as most of them had their disease in less than five years. However, similar findings have been reported by other studies^{5, 6, 7, 8, 9, 10}.

Based on the pathophysiology of hydrocele disease in filarial affected communities, this study expected to find high levels of the investigated electrolytes (Sodium, potassium, chloride and calcium), but to the contrary all the tested electrolytes were found to be normal compared to the known serum levels. This tells that, despite the obstructive effects of filarial worms, yet the electrolyte balance mechanisms in the tunica vaginalis of filarial affected scrotum still function normally. Similar findings have also reported by other studies^{13,14,15}. Very few cases had their

electrolytes below the normal serum levels. However, study by Mandlala et al¹³, reported high levels of calcium, albumin and creatine-kinases in hydrocoele fluid and low levels of potassium, alanine transaminases and aspartate transaminases¹⁴.

Conclusion

Hydrocoele fluids in filarial affected communities do contain the same electrolyte levels as serum and only few cases contain low levels as compared to known serum levels. The tunica vaginalis of filarial related hydrocoele are soft and thin in most cases especially those with short duration of the disease and majority of the hydrocoele fluids is straw or clear yellow in colour.

Study limitations

Few cases were obtained at the surgical camp. Due to limitation of reagents, only common electrolytes were tested

Acknowledgement

We are grateful to our resident in the department of Surgery for their support in participating in the surgical camp and data collection. We also like to thank all members of National institute of medical research Tanzania and all the surgical and medical staff at pangani hospital.

References

1. Christopher Fowler. The testis and scrotum. chapter 79.in;bailey and love's short practice of surgery, Russel R.C.G.et.al.(eds).24thedition,London; Arnold publishers2004;1403-1416.
2. Marc Goldstin .surgical management of male infertility and other scrotal disorder.vol.1.in;Campbell's urology,Patrickc.walsh, Alan B Retik, Vaughan(eds).8th edition. Edinburgh:WBSaunders company 2002;313-316.
3. Margaret. Surgery of the groin and External genitalia. In: Farquharsons'sText book of operative general surgery, Farquarsons M, Morgan B Hodder (eds). 9th edition. Edinburgh: Arnold Publishers 2004; 474
4. Hoshino H, Nakajima N, Hihara T, Hayakawa M, Kawamura N. What are the contents of a hydrocele testis?*Tokai J ExpClin Med*. 1984 Mar;9(1):49-51.
5. deVries, CR. 2002. "The Role of the Urologist in the Treatment and Elimination of Lymphatic Filariasis Worldwide." *BJU International* 89 (suppl 1) 37-43.
6. Simonsen PE, Meyrowitsch DW, Makunde WH, Magnunssen P. Bancroftianfilariasis: The pattern of microfilaraemia and clinical manifestations in three endemic communities of northeastern Tanzania. *Acta Trop*. 1995;60:179-87.
7. Thomas G, Richards FO, Jr, Eigege A, Dakum NK, Azzuwut MP, Sarki J, et al. A pilot program of mass surgery weeks for treatment of hydrocele due to lymphatic filariasis in central Nigeria. *Am J Trop Med Hyg*. 2009;80:447-51.
8. Chukwudi O, Okorie CO, Louis L, Pisters LL, Ping Liu. Long standing hydrocele in adult Black Africans: Is Preoperative scrotal ultrasound justified? *NigerMed J*2011; 52:173-6176.
9. Jat N, Bano F, Memon IA, Memon MS, Azmi MA. Primary vaginal hydro- cele; different surgical procedures: a comparative study. *Professional Med J* 2014;21(5):879-882.
10. Gooding G A ,Leonhardt W C , Marshall G, Seltzer MA , Presti J C. CholesterolCrystals in hydrocele:sonograhpic detection and possible significance. *AJR am J Reontgenol* 1997;169(2):527- 529.
11. Norões, J., D. Addiss, A. Cedenho, J. Figueredo-Silva, G. Lima, and others. 2003. "Pathogenesis of Filarial Hydrocele: Risk Associated with Intrascrotal Nodules Caused by Death of Adult *Wuchereriabancrofti*." *Transactions of the Royal Society of Tropical Medicine and Hygiene* 97: 561-566.



12. Rodriguez, W.C., D.D. Rodriguez, R.F. Fortuño. 1981. "The Operative Treatment of Hydrocele: A Comparison of 4 Basic Techniques." *Journal of Urology* 125: 804–805.
13. Madlala TS, Rencken RK, Bornman MS, Reif S, Joubert HF, Van der Merwe CA. Biochemical analysis of tunica vaginalis fluid in patients with or without idiopathic hydroceles. *Br J Urol.* 1994 Oct; 74(4):511-4.
14. Sivam NS¹, Jayanthi S, Ananthakrishnan N, Elango A, Yuvaraj J, Hoti SL, Pani SP. Tropical vaginal hydroceles: are they all filarial in origin. *Southeast Asian J Trop Med Public Health.* 1995 Dec;26(4):739-42.
15. Ku JH. The Excision, Plication and Internal drainage techniques- a Comparison of the results for idiopathic Hydrocoele. *British Journal of Urology International* 2001; 87:82-84.