

Management of Foreign Body Aspiration in Pediatric Patients: An Experience from a Tertiary Hospital in Ethiopia

A. Tadesse¹, B. Hailemariam²

¹ Assistant professor and consultant pediatrics surgeon, School of Medicine, Addis Ababa University

² Resident in general surgery, School of medicine, Addis Ababa University

Correspondence: Amezene Tadesse, MD, amezenet@yahoo.com

Background: Accidental foreign body aspiration is a relatively common occurrence in pediatric patients and may result in asphyxiation and death, especially among those aged less than 4 years. *This study was aimed at analyzing the clinical and radiological profile, modes of managements and outcomes of foreign body aspiration in children in a tertiary care center and identify areas of possible interventions for proper management of such cases.*

Method: *This was a 2-year retrospective study of children who were admitted and treated for foreign body aspiration between 1 September 2012 and 30 August 2013 at the paediatric surgery unit of Tikur Anbesa Specialized Hospital (TAH) in Ethiopia. Case records of patients suspected to have foreign body aspiration over the past two years were analyzed. Clinico-radiological features, types and location of foreign bodies, modes of management and patients outcomes were studied.*

Results: *A total of 81 children underwent rigid bronchoscopic evaluation, and foreign bodies were identified and removed in 76(93%) of the cases. The mean age of the patients was 4.6 yrs (5 months to 11 years), 54 (71.1%) were male and 22 (28.9%) were female. A foreign body aspiration history obtained in 58 (76.3%) of the patients, The mean duration of illness was 1.6 ±1.9 days with range of 4.5 hours and 4 months, majority of patients, 29 (38.2%) were from Oromia region; 14 (18%) reported within 24 hours of the event; plastic tips was retrieved in 17 (22.4%) patients, seed in 15(19.7%), balloon inflator tip in 7(9.2%), metallic tips 5 (6.6%), Hijab pin 2(2.6%); 50 (73.7%) presented with cough, shortness of breath in 38(50%), wheeze in 23(30.3%); chest x-ray common findings were 10(13.2%) lobar pneumonia, 8 (10.5%) radio opaque foreign body, 7(9.2%) hyperinflation, and 4(5.3%) pneumonia; The site of foreign body lodgment is right main bronchus in 44 (57.9%) patients followed by left main bronchus in 20 (26.3%), trachea in 11(14.5%) and lower stem bronchus in 1 (1.3 %); 73(96%) cases had smooth course in the hospital and discharged within 10 days after bronchoscopic procedures and individualized medical care. 1(1.3%) has passed away.*

Conclusion: *Foreign body aspiration remains a common unintentional childhood injury. Rigid bronchoscopy is very effective procedure for the removal of aspirated foreign body with fewer complications. Education is the best preventive measure for decreasing the incidence of this problem. Caring physician should maintain high index of clinical suspicion to avoid fatal outcome and long term morbidity. Bronchoscopic facility should be available at all hospitals.*

Keywords: Foreign body aspiration, rigid Bronchoscopy,

Introduction

Foreign body aspiration claims thousands of lives each year, because they are rarely managed in time ¹. While aspiration of a large sized foreign body can end with a sudden death by causing complete obstruction, small foreign body can result in death by triggering a laryngospasm and hypoxic crisis ^{2,3}. Most cases of foreign body aspiration are diagnosed early due to the dramatic initial clinical presentation with unmistakable pointers such as sudden bouts of coughing, choking, stridulous respiration, or wheezing. However in some cases it is asymptomatic or the

initial phase symptoms quickly resolve and the foreign body remains lodged in the lower airways ⁴.

High degree of suspicion was needed to diagnose foreign body aspiration, if there is no associated history. But sometimes X- Rays may be inconclusive and bronchoscopy is the ultimate procedure to exclude foreign body ^{5,6}. Missed foreign bodies present later with chronic ill health and varied symptoms that could easily be diagnosed as other chronic respiratory conditions ⁷.

Younger children are at the highest risk for accidental foreign body aspiration. This increased incidence has been attributed to several factors among younger children, including:

- 1) their tendency to put small objects into their mouths;
- 2) often cry, shout, run, and play with objects in their mouths; and
- 3) do not have molars to chew certain foods adequately.

Most studies show that fewer than 15% of foreign body aspirations occur among children older than 5 years of age. Similar study indicated also the condition is not rare in Ethiopia, both in older children and adults ⁸.

Patients and Methods

The clinical records of all children admitted with suspected foreign body aspiration to Tikur Anbessa Specialized Teaching Hospital, Addis Ababa, between 1 September 2012 and 30 August 2013, were analyzed retrospectively. The following data was collected: sex, age, residence, duration of illness, availability of definitive history, imaging findings, date of referral, admission and bronchoscopic procedure, need for tracheostomy, bronchoscopic procedure, associated findings on bronchoscopy, type and location of the foreign body and duration of hospital stay after its removal, and outcome.

All patients suspected of foreign body aspiration were investigated with chest x-ray and subjected to rigid bronchoscopy under general anesthesia. The data and information was prospectively entered into a computer database and was further analyzed. The statistical package for social science, SPSS for Windows, Version 16.0 was used for descriptive data analysis.

Result

A total of 81 patients suspected for a possible foreign body aspiration were identified. There was no foreign body in 5 of them and they were excluded in the analysis. The mean age of the patients was 4.6 yrs (range: 5 months to 11 years), 46(60%) being under 5 years of age. 54 (71.1%) were male, while 22 (28.9%) were female making the M: F 2.5:1. A foreign body aspiration history could be obtained in 58 (76.3%) of the patients, while in 18 (23.7%) of the cases, patients or their families were not aware of any kind of aspiration.

The time interval between aspiration and admission to our unit ranged between 4.5 hours and 4 months with the mean of 1.6 \pm 1.9 days. Table 1 shows the regional distribution with 29 (38.2%) of them coming from Oromia and followed by Addis ababa and other regions. Only 14 (18%) reported within 24 hours of the event. There was a delay of more than 24 hrs in 62(82%) of the cases, the maximum interval between the occurrence and referral being 120 Days. No clear symptoms and signs following foreign body aspiration was noted in 1 (1.3%) cases, 75(98.7%) cases were symptomatic after the aspiration. Most of them 50 (73.7%) presented with cough, shortness of breath in 38(50%), wheeze in 23(30.3%) and other clinical symptoms as depicted in Table 2.

Table 1. Regional Distribution of Patients Referred

Region	Frequency	Percent
Tigray	4	5.3
Addis Ababa	15	19.7
Afar	4	5.3
Amhara	10	13.2
Oromia	29	38.2
SNNP	8	10.5
Benishanguel Gumez	1	1.3
Harer	3	3.9
Somali	2	2.6
Total	76	100.0

Table 2. Clinical presentation of patients with foreign body aspiration

Presentation	Percent
Cough	56/76 (73.7%)
Shortness of breath	38/76 (50%)
Hemoptysis	3 /76(3.9%)
Asymptomatic	1/76 (1.3%)
Hemothorax	1/76 (1.3%)
Pneumothorax	1/76 (1.3%)
Lung abscess	1/76 (1.3%)
others	51/76 (67.1%)

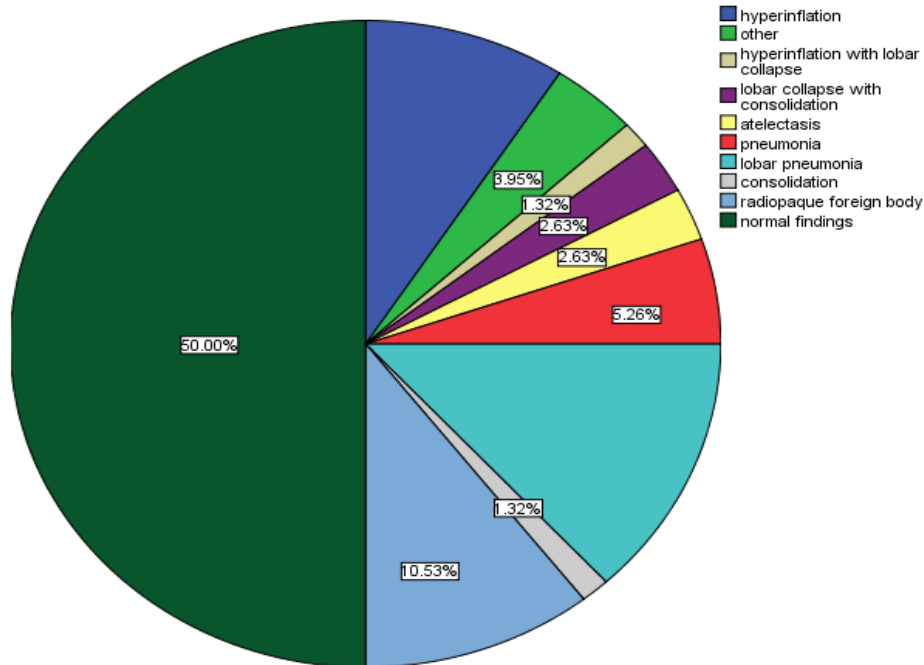


Figure 1. Chest x-ray Finding of Patients with Foreign Body Aspiration

On radiologic evaluation of the patients presumed to have foreign body aspiration, 38(50%) have normal chest x-ray finding and in the remaining, the common findings were lobar pneumonia in 10(13.2%) cases, radio opaque foreign body in 8 (10.5%) cases, hyperinflation in 7(9.2%) cases, and pneumonia in 4(5.3%) cases. As shown in figure 1, Atelectasis and lobar collapse with consolidation were encountered at the same frequency, 2(2.6%), each.

All the patients were scoped under general anesthesia using rigid bronchoscope, plastic tips were retrieved in 17 (22.4%), seed in 15(19.7%) patients, balloon inflator tip in 7(9.2%), metallic tips in 5 (6.6%), Hijab pin 2(2.6%) followed by many other FBs. The most common airway site where foreign bodies were encountered during the bronchoscopic procedure was in the right main bronchus in 44 (57.9%, followed by left main bronchus in 20 (26.3%), trachea in 11(14.5%) and lower stem bronchus in 1 (1.3 %) (Figure 2).

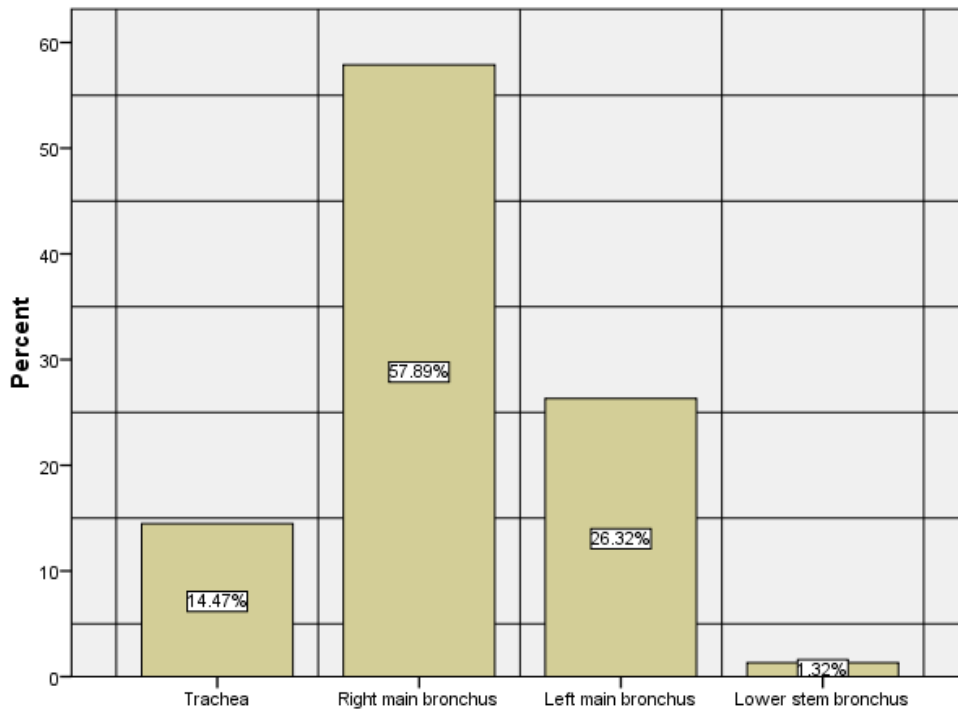


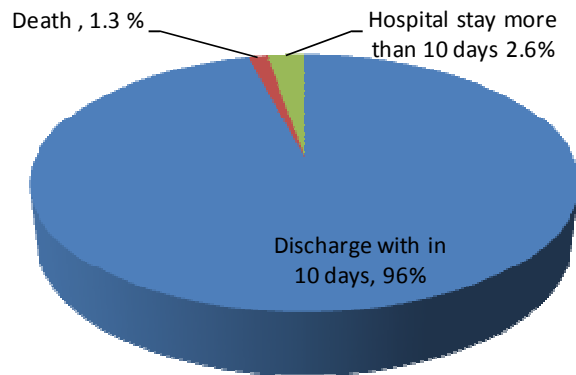
Figure 2. Specific sites in the airway where foreign bodies were found

Pulmonary infection was detected in 19 (25%) cases following aspiration of foreign bodies and other complications associated were atelectasis in 2(2.6%) cases, pneumothorax in 2 (2.6%) cases, pulmonary infection with atelectasis in 1(1.3%) case, pulmonary infection with pneumothorax in 1(1.3%) case, pulmonary infection with lung collapse in 1 (1.3%), lung collapse in 1(1.3%) and other complication like minor airway edema detected clinically, throat discomfort, difficult of swallowing,...etc account 49(64.5%) cases, as shown in Table 3.

Bronchoscopic removal of foreign body on first attempt was possible in 68 (89.4%) cases and in the remaining 8, 4 (5.2%) cases underwent second trial or re-bronchoscopy after a couple of days and removal was successful, and in 4(5.2%) cases tracheotomy was done to achieve removal of the foreign bodies. The majority (96%) of the cases had smooth course in the hospital and discharged within 10 days after bronchoscopic procedures and individualized medical care. 3(3.9%) cases stayed more than 10 days requiring further medical care and 2(2.6%) of them were discharged improved but the remaining case ,1(1.3%)has passed away.

Table 3. Complications associated with foreign body aspiration

Complications	Frequency	Percent
pulmonary infections	19	25.0
lung collapse	1	1.3
others	49	64.5
pulmonary infection with atelectasis	1	1.3
pulmonary infection with pneumothorax	1	1.3
pulmonary infection with lung collapse	1	1.3
pneumothorax	2	2.6
Atelectasis	2	2.6
Total	76	100.0



Discussion

Accidental foreign body aspiration is a relatively common occurrence in pediatric patients ^{9,10}, and may lead to asphyxiation and death, especially among those aged less than 4 years ¹¹. It can occur at every age but children aged 1-3 are involved most frequently according to the literature ¹²⁻¹⁶. Darrow and Hollinger ¹¹ reported that 84% of their cases were younger than five years and 73% were younger than three years. Muet al ¹³ and Carluccio et al ¹⁴ respectively reported that 90% and 61.9% of their series consisted of children aged 3 and below. In our study, 46 (60%) of cases were younger than five years. 54 (71.1%) were male, while 22 (28.9%) were female, with male to female ratio 2.4:1. Although an explanation is missing about the reasons why boys are more involved, in other literatures too the rate is approximately 2:1 in favor of male children ¹⁵⁻¹⁷.

In our study, most of them 50 (73.7%) presented with cough, shortness of breath in 38(50%) and wheeze in 23(30.3%). Physical examination findings include fever, stridor, retractions, and decreased breath sounds. The longer a foreign body resides in the airway, the more likely it is to migrate distally and cause an inflammatory reaction leading to granulation and impacting. When this occurs, symptoms of chronic cough and wheezing may mimic asthma like condition,¹¹.

The configuration of the bronchial tree and the posture of the person during aspiration determine the location of the foreign body^{18, 19}. The smaller angle and a larger air volume during

inspiration are responsible for foreign body locating in the right bronchus in general ²⁰. Foreign bodies were more common on the right side 44 (57.9%) in our study and some authors too who have studied large series have reported foreign bodies mostly on the right side ²¹, while others reported no significant preponderance of right or left sides ²².

Radiographic imaging can be helpful if the aspirated object is radio-opaque or if there are signs of hyper-expansion on expiration. However negative-imaging studies, do not exclude the presence of a foreign body in the airway. In some studies, normal chest X-rays have been reported in more than two thirds of the children ²². In our study, 38(50%) have normal chest x-ray finding and in the remaining, there were significant findings. These results are similar to previous experience ^{23, 24}.

Bronchoscopy should be used as a diagnostic method in cases where the possibility of FB aspiration cannot be ruled out through history, physical and radiological examination or when it is highly suspected. Upon diagnosis, early bronchoscopy is necessary because the earlier the bronchoscopy the lesser the complications. Dikensoy et al. reported that morbidity evaluated in cases where medical treatment without bronchoscopy was used curatively ²⁵.

Majority of cases, 62(82%) in our study presented after 24hrs and only 14 (18%) reported within 24 hours of the event. And also as indicated on the demographic result, most referred patients are out of Addis ababa and delay in the transportation, late detection, parents or caregiver unawareness can be mentioned as a possible factors for delay presentation. As seen in other reports from Ethiopia, correct diagnosis was delayed or missed in 20% of the series. Late presentation, delay in diagnosis and intervention as well as missed diagnoses were major causes of prolonged morbidity and high mortality ²⁶.

Conclusion and Recommendations

It is important for the clinician to have a high index of suspicion, especially in patients with sudden appearance of a wheeze without a previous history of asthma, especially if unilateral.

We recommended that patients with one or more of the following findings should be subjected to bronchoscopy:

1. history of definite or suspected foreign body aspiration;
2. features of foreign body aspiration, e.g., choking, wheezing, stridor and paroxysmal cough;
3. recurrent chest infections with no apparent cause, when bronchial asthma has been excluded; and
4. chest radiograph suggestive of foreign body aspiration.

Foreign body aspiration is a dramatic event with potentially lethal sequel. Education is the best preventive measure for decreasing the incidence of this problem. It is preventable by creating public awareness through mass media about its serious consequences and parental education to keep small objects out of reach of children. Caring physician should maintain high index of clinical suspicion for early diagnosis and management to avoid fatal outcome and long term morbidity. Bronchoscopic facility should be available at all hospitals with paediatrics units.

Acknowledgement

We would like to acknowledge Dr Abebe Bekele for his in valuable comments. We are indebted to Dr Zelalem Chimdesa and Dr Balkew Agonafir for their involvement in the collection of the data. Finally we would like to pass our heart felt gratitude to Dr Belachew Dejene, Dr Hanna

Getachew, Dr Tihitina Nigussie and Dr Milliard Derbew for their role in the management of the patients.

Reference

1. Baharloo F, Veyckemans F, Francis C, Bietlot MP, Rodenstein DO. Tracheobronchial foreign bodies: presentation and management in children and adults. *Chest* 1999;**115**(5):1357-62.
2. Cataneo AJ, Cataneo DC, Ruiz RL Jr. Management of tracheobronchial foreign body in children. *Pediatr Surg Int* 2008; 24: 151-56.
3. Elhassani NB. Tracheobronchial foreign bodies in the middle east a Baghdad study. *J Thorac Cardiovasc Surg* 1988; 96: 621-25.
4. Lima JOB, Fischer GB. Foreign body aspiration in children. *Paediatr Respir Rev* 2002; 3: 303-7.
5. Asmatullah I, Rasool G. Endoscopic removal of tracheobroncheal foreign bodies at a peripheral hospital. *JPMI* 2004;**8**(3):447-52.
6. Tariq P. Foreign body aspiration in children--a persistent problem. *J Pak Med Assoc* 1999;**49**(2):33-6.
7. Karakoc F, Cakir E, Ersu R, et al. Late diagnosis of foreign body aspiration in children with chronic respiratory symptoms. *Int J Pediatr Otorhinolaryngol* 2007; 71: 241-6.
8. Abebe Bekele, "Aerodigestive Foreign Bodies in Adult Ethiopian Patients: A Prospective Study at Tikur Anbessa Hospital, Ethiopia," International Journal of Otolaryngology, vol. 2014, Article ID 293603, 5 pages, 2014. doi:10.1155/2014/293603
9. Mourtaga SM, Kuhail SM, Tulaib MA. Foreign body inhalations managed by rigid bronchoscope among children, in shifa hospital Gaza- Palestine. *Annals of Alquds Medicin* 2005;**2**:53-7.
10. Schmidt H, Manegold BC. Foreign body aspiration in children. *Surg Endosc* 2000;**14**(7):644-8.
11. Evans JNG. Foreign bodies in larynx and trachea. In: Kerr Scott-Brown's Otolaryngology, Butterworth-Heinemann; 1997:2:4-6.
12. Banerjee A, Rao KS, Khanna SK, et al. Laryngo-tracheo-bronchial foreign bodies in children. *J Laryngol Otol* 1988; 11: 1029-32.
13. Mu L, He P, Sun D. Inhalation of foreign bodies in Chinese children: a review of 400 cases. *Laryngoscope* 1991; 101: 657-60
14. Carluccio F, Romeo R. Inhalation of foreign bodies: epidemiological data and clinical considerations in the light of a statistical review of 92 cases. *Acta Otorhinolaryngol Ital* 1997; 17: 45-51.
15. Puhakka H, Kero P, Valli P, Iisalo E, Erkinjuntti M. Pediatric bronchoscopy. A report of methodology and results. *Clin Pediatr* 1989; 28: 253-57.
16. Tomaske M, Gerber AC, Stocker S, Weiss M. Tracheobronchial foreign body aspiration in children - diagnostic value of symptoms and signs. *Swiss Med Wkly* 2006; 136: 533-38.
17. Ludemann JP, Holinger LD. Management of foreign bodies of the airway. In: Shields TW, LoCicero J, Ponn RB, eds. General Thoracic Surgery. 5th ed Philadelphia: *WB Saunders* 2000; 73: 853-62.
18. Pinto A, Scaglione M, Pinto F, et al. Tracheobronchial aspiration of foreign bodies: current indications for emergency plain chest radiography. *Radiol Med* 2006; 111: 497-506.
19. Rafanan AL, Mehta AC. Adult airway foreign body removal What's new? *Clin Chest Med* 2001; 22: 319-30.
20. Athanassiadi K, Kalavrouziotis G, Lepenos V, Ve ark. Management of foreign bodies in the tracheobronchial tree in adults: A 10-year experience. *Eur J Surg* 2000; 166: 920-23.
21. Fienkaya I, Saḡdḡç K, Gebitekin C, et al. Management of foreign body aspiration in infancy and childhood. A life threatening problem. *Turk J Pediatr* 1997;39:353-362



22. Mu L, He P, Sun D. Inhalation of foreign bodies in Chinese children: a review of 400 cases. *Laryngoscope* 1991;101:657-660
23. Wunsch R, Wunsch C, Darge K. Foreign body aspiration. *Radiologe* 1999;39:467-471
24. Mu L, He P, Sun D. The causes and complications of late diagnosis of foreign body aspiration in children. report of 210 cases. *Arch Otolaryngol Head Neck Surg* 1991;117:876-879
25. Woy O, Usalan C, Filiz A. Foreign body aspiration: clinical utility of flexible bronchoscopy. *Postgrad Med J*. 2002 Jul;78(921):399-403. [[PMC free article](#)] [[PubMed](#)]
26. Melaku G. Foreign body aspiration in children: Experience from Ethiopia. *East Afr Med J* 1996; 73: 459-62