

## **Morphometry of the Myopectineal Orifice: Relevance in Prosthesis Hernia Repair.**

**B.M. Ndung'u, A.C. Koech, M.K. Tharao**

Department of Human Anatomy, School of Medicine, University of Nairobi, Kenya.

**Correspondence to:** Dr. Bernard M. Ndung'u, Email: [bmndungu@yahoo.com](mailto:bmndungu@yahoo.com)

**Background:** All groin hernias occur through a weakness at the lower extremity of the abdomen: the myopectineal orifice (MPO). Open preperitoneal and laparoscopic techniques involve dissection and placement of the prosthetic mesh to cover all potential hernia sites of the MPO. We re-examined the preperitoneal anatomy with the aim of determining the minimum ideal shape and size of prosthetic mesh for the repair of inguino-femoral hernias.

**Methods:** Dissection was performed on 15 preserved human adult cadavers of both sexes. The preperitoneal approach was used to access the myopectineal orifice and its shape and dimensions obtained from tracings. The surface area was obtained by point counting.

**Results:** The shape of the MPO was trapezoid and its area  $7.0 \pm 1.29\text{cm}^2$ . The maximum length was 5.7cm and the maximum width 2.9cm. The point of maximum width varied along the length and the area of the MPO was significantly larger in male.

**Conclusion:** For preperitoneal placement of prosthesis, a rectangular mesh measuring 15cm by 12cm is appropriate. These dimensions ensure adequate coverage and overlap of all the potential hernia sites in the groin, as well as allowing for mesh shrinkage.

**Key Words:** Myopectineal orifice; Morphometry; Prosthesis hernia repair

### **Introduction**

Inguinal hernia repair is a common major operation in general surgery<sup>1-3</sup>. All groin-inguinofemoral- hernias occur through a weakness in a common potential weak area at the lower end of the abdomen. Originally described by Fruchaud<sup>4</sup>, the myopectineal orifice (MPO) is a quadrangular anatomic opening between the false pelvis and ipsilateral lower extremity. It is divided, by the inguinal ligament externally and the iliopubic tract internally, into a superior area and an inferior area for the passage of the spermatic cord structures and the femoral vessels respectively.

Cheate<sup>5</sup> initially described, and later Nyhus et. al.<sup>6</sup> popularized the preperitoneal hernia repair<sup>7</sup>. In introducing the giant prosthesis for reinforcement of visceral sac (GPRVS) technique, Stoppa<sup>8</sup> further demonstrated that, permanent repair of groin hernias does not require closure of the abdominal wall defect *per se*, but all of them can be treated by the placement of an unsutured prosthesis in the preperitoneal space. Reinforcement in this area allows intra-abdominal pressure to assist in securing the inlayed prosthesis to the pelvic floor, thus following Pascal's principle of hydrostatic pressure<sup>4,9,10</sup>. Although the preperitoneal approach had not been very popular among surgeons, there is renewed interest with the explosion of laparoscopic hernia repair in the last two decades. Laparoscopic techniques follow the principles of successful open preperitoneal repair, including thorough preperitoneal dissection and placement of the prosthetic mesh to cover all potential hernia sites of the myopectineal orifice<sup>11-14</sup>.

Totte et. al<sup>15</sup> noted that, surgical literature on laparoscopic operative techniques gives incomplete information about the actual form of the internal inguinal region and the size of the prosthetic mesh. Using a mathematical model, they illustrated that, the currently used 10 x 15 cm prosthetic mesh can easily be placed without anchoring but is also too large for covering the necessary inguinal area. The implantation of large meshes, though essential to reduce the risk of recurrence<sup>16</sup>, has also been associated with significant untoward effects including neuralgias, testicular atrophy, inguinal vasal occlusion and difficulties in future operations of the groin<sup>17-22</sup>. Thus, any attempt to avoid the use of unnecessarily large prostheses is worthwhile.

The scientific basis of the ideal size and shape of the prosthetic mesh can be derived from a combination of morphometry of the weak area to be protected and the technical precautions that needs to be taken in its placement to avoid complications<sup>9,21,23,24</sup>. We re-examined the preperitoneal anatomy with the objective of determining the minimum ideal shape and size of prosthetic mesh for the repair of inguino-femoral hernias.

**Material and Methods**

This anatomic study was performed on 15 adult black African cadavers, 8 males and 7 females at the Department of Human Anatomy of the University of Nairobi, Kenya.

The mean height of the cadavers was 165cm with a range of 158 to 176cm. The specimens were previously fixed with an aqueous solution of formaldehyde and preserved; before dissection. Their specific ages were not available. The abdominal cavity was opened via a midline incision. The parietal peritoneum was peeled off and the preperitoneal adipose tissue removed by blunt dissection to enter into the preperitoneal space. The external iliac vessels were transected just beneath the medial end of the iliopubic tract and retracted proximally (Figure 1).

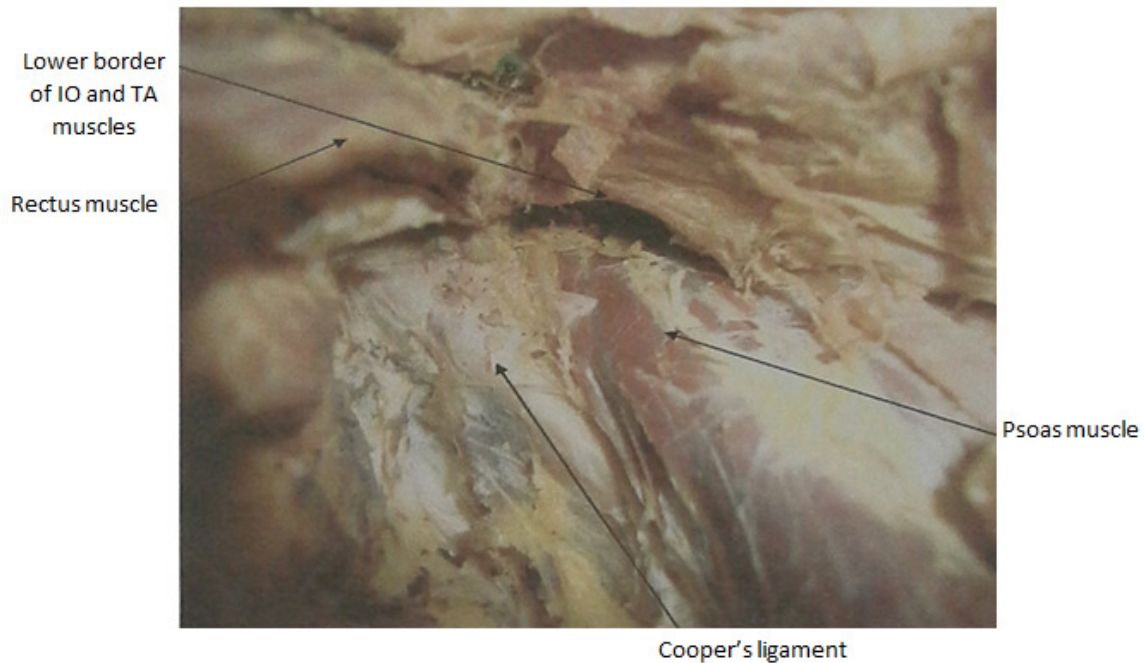

Figure 1. Boundaries of the Myopectineal Orifice. (IO- Internal Oblique, TA – Transversus Abdominis)

An A4 size transparent paper was laid to cover the whole of the posterior surface of the myopectineal orifice (MPO). Through it, the anatomical boundaries (the psoas muscle laterally, inferior border of the internal oblique & transverses abdominis superiorly, medial edge of rectus abdominis medially and the superior pubic rami inferiorly) were seen and traced using an indelible marker pen (Figure 2).

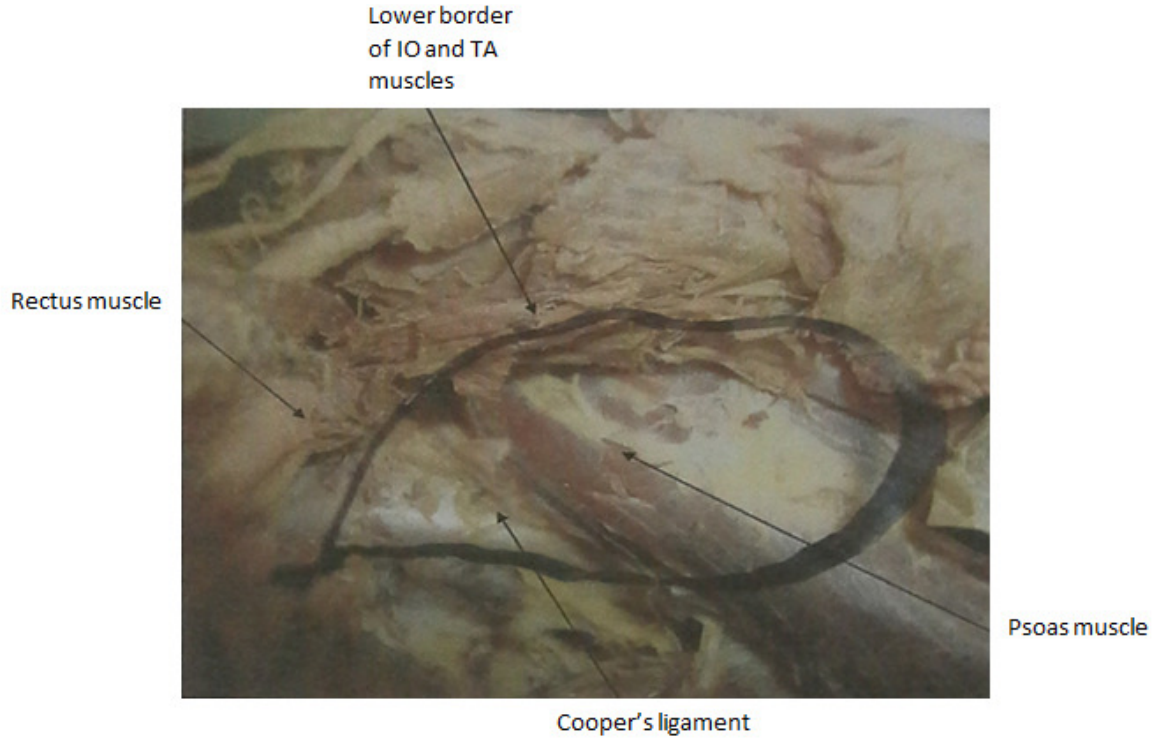


Figure 2. Tracing of the boundaries of the Myopectineal Orifice (IO- Internal Oblique, TA – Transversus Abdominis)

The length and maximum width were measured in centimetres on the tracings. The tracings were then placed on a test system with a set of regularly spaced points at one centimetre intervals. The MPO area was estimated by counting all points within the traced profiles and multiplying the number by a square centimeter (Figure 3). This biological morphometry method was established by Weibel <sup>25</sup> and has recently been utilized in determination of the size of Hesserts triangle in an anatomical study on Hernia. <sup>26</sup>

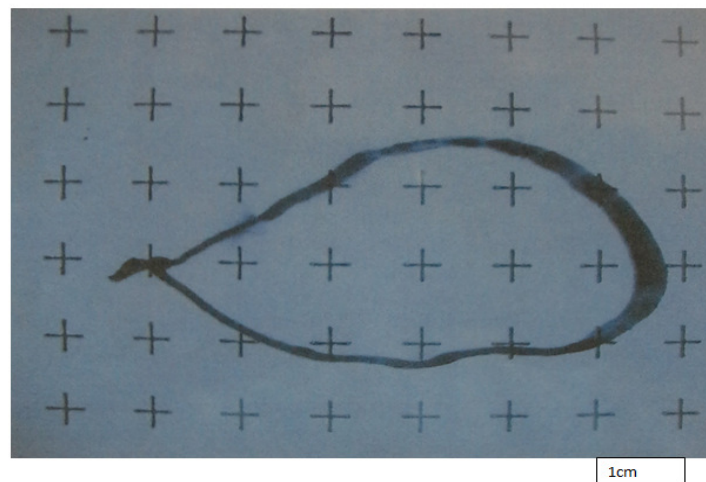


Figure 3. Traced outline of Myopectineal Orifice placed onto grid for point counting.

Photographs were taken using a 6.0 mega pixel digital camera. In view of the size of the sample and assuming non-normal distribution, we used the non-parametric Mann-Whitney U one sided and two-sided test for analysis. Permission for the study was obtained from the Ethics Review Committees of the Kenyatta National Hospital and the School of Medicine, University of Nairobi.

**Results**

The dimensions of the MPO are shown in Table 1.

**Table 1.** Dimensions of the Myopectineal Orifice.

	Mean ± S.D.	Minimum	Maximum
Maximum length (cm)	4.9 ± 0.49	4.1	5.7
Maximum width (cm)	1.9 ± 0.38	1.1	2.9
Area of MPO (cm <sup>2</sup> )	7.0 ± 1.29	5.4	10.8

**Table 2.** Area of the Myopectineal Orifice, Comparison between males and females

Test	Myopectineal Orifice Area (cm <sup>2</sup> )			
	Mean ranks (males)	Mean ranks (female)	U-statistic	p-value
1 Sided*	10.6	5	49	0.009
2 Sided*	10.6	5	49	0.017

\*Mann Whitney U test


The mean area of the MPO was significantly greater in males than in females (p<0.05) (Table 2)

There was no statistically significant difference in the means of lengths and widths of the MPO between males and females (Table 3). The shape of the MPO was trapezoid, being wider inferiorly. With reference to the location of the maximum width, 3 different shapes were described (Figure 4a).

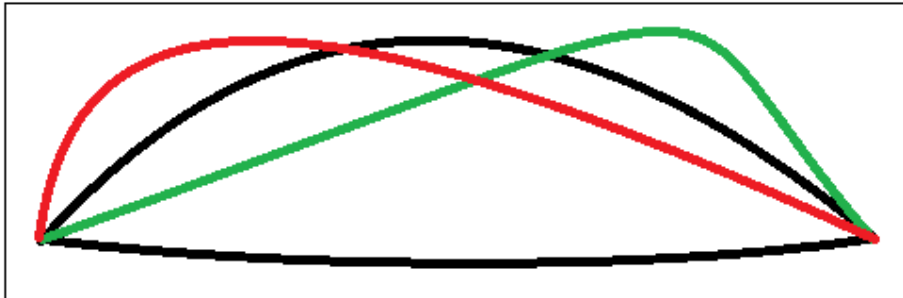
**Table 3.** Length and Width of the MPO, Comparison between males and females

Variable	Test	Myopectineal Orifice Dimensions (cm)			
		Mean ranks (males)	Mean ranks (females)	U-statistic	p-value
MPO Length	1 sided*	8.81	7.07	34.5	0.490
	2 sided*	8.81	7.07	34.5	0.245
MPO Width	1 sided*	8.75	7.14	34	0.261
	2 sided*	8.75	7.14	34	0.522

\*Mann Whitney U test



**Figure 4a.** Line illustrations of the shape variants of the Myopectineal Orifice.



**Figure 4b.** Rectangular shape for the variable shapes of the Myopectineal Orifice

### Discussion

Groin hernia repair is one of the commonest operations in general surgery<sup>1-3</sup> and as such, even relatively modest improvements in clinical outcomes would have a significant medical impact<sup>4, 27</sup>. All groin hernias occur through the myopectineal orifice. This anatomic hole is divided into three anatomic triangles which are potential sites of groin herniation: medial, lateral and femoral triangles. The medial triangle, encircled by the arching fibers of the internal oblique superiorly, the rectus abdominis medially, the inguinal ligament inferiorly, and deep inferior epigastric vessels laterally, is the site of direct inguinal herniation. The lateral triangle, defined by the deep inferior epigastric vessels medially, the inguinal ligament inferiorly, and the arching fibers of the internal oblique is the site of direct inguinal herniation. Femoral herniation occurs through the femoral triangle, bordered by the iliopectineal (Cooper's) ligament inferiorly, the inguinal ligament and iliopubic tract superiorly, and iliopsoas muscle laterally. Any effective groin herniorrhaphy technique, not only repairs the pathologic hole but covers all these potential sites of herniation<sup>28,29, 30</sup>.

Success in groin hernia repair, measured by permanence of the operation, fewer complications and earlier return to normal activities depends on the understanding of the anatomy of the groin as well as how to effectively use the currently available techniques and prosthetic materials. In this study, the mean area of the MPO is 7.0+/- 1.29cm<sup>2</sup> with a maximum area of 10.8cm<sup>2</sup>. The area has been shown to be significantly larger in males than in females. Although the general shape of the MPO was trapezoid with a wide base inferiorly, the location of the maximum width varied depending on the shape of the arching fibres of internal oblique and transverses abdominis muscles and their intersection with the rectus abdominis muscle (Figure 4a). The three different shapes were equally distributed in the study population. These variable shapes have a direct implication on the ideal shape of the prosthetic mesh. Wantz<sup>9</sup> popularized the use of a diamond-shaped prosthesis for unilateral repair for this shape conforms to the myopectineal orifice. This shape however, may not be ideal for the different orientations of the

“diamond” or trapezoid revealed in this study. To accommodate these variations, a rectangular shaped prosthesis seems the most appropriate to cover the MPO and ensure circumferential and adequate overlap (Fig. 4b).

To position a rectangular prosthesis over this area, the dimensions should be more than the maximum length and width of MPO measured which is 5.7X2.9 cm in this study. Insufficient overlap of the hernia defect has been singled out as the most important factor in hernia recurrence after prosthesis repair<sup>16, 17, 20, 22</sup>. It is well established from human and porcine model studies that, adequately positioned prosthesis should overlap the defect by more than three centimeters<sup>23, 24, 31</sup>. Thus, from the dimensions of the MPO in this study, the adequate prosthesis mesh should measure at least 9.7cm by 6.9cm giving it an overlap of four centimeters in either direction. Wolshock and Konerding<sup>32</sup> in a similar cadaveric study recommended a mesh measuring 10cm by 8 cm for adequate coverage of MPO in both genders while Totte et al<sup>15</sup> found a mesh of 8cm by 9cm to be large enough to cover the whole of the inguinal region. However, previous clinical studies had already established that, when implanting 13cm by 8cm mesh for unilateral groin hernia repair, the main cause of recurrence was insufficient mesh size<sup>16, 17, 20, 33, 34</sup>. Therefore, other than the size of the defect to be overlapped and incorrect placement, there are other mesh properties related to their incorporation into the tissues that need to be considered before the ultimate size is suggested.

Shrinkage of meshes after implantation in living tissue has been related to hernia recurrence. Shrinkage occurs with most mesh materials and to varying degrees. The causal factors behind shrinkage are related, but not limited to, contraction as a consequence of the physiological wound healing process. The magnitude of it is related to inflammatory activity and foreign body reaction, which are mediated by the structure and material of mesh, type of fixative, collagen disorders and environmental factors<sup>34, 35</sup>. The shrinkage of different types of mesh in vivo is in the range of 33-50%<sup>34-38</sup> and this should be taken into account when sizing the implant during surgery. To avoid the mesh becoming smaller than the repaired defect, it is recommended to use a prosthesis larger than the defect diameter by 5cm<sup>34, 39, 40</sup>. Applying this to the 9.7cm by 6.9cm dimensions of the mesh in this study, the ideal size of mesh, allowing for shrinkage is recommended to be 14.7cm by 11.9cm. The size of the currently used prosthetic mesh of 10cm by 15 cm is usually adequate for the coverage of the more common suprainguinal part of the MPO. Since coexistence of both inguinal and femoral hernias is very rare, there is minimal need of covering the infrainguinal compartment.

## Conclusion

When the minimum overlap distance of the anatomic hole, the variable trapezoidal shapes of the MPO and the maximum shrinkage of the mesh are taken into consideration, the ideal mesh for all groin hernia repair is recommended to be rectangular in shape measuring 12cm by 15cm.

## Acknowledgement

We appreciate all the staff of the Department of Human Anatomy for the assistance offered during the study and Dr. M. Wahome of the Department of mathematics for the analysis.

## References

1. Editorial. British hernias. *Lancet*. 1985;1:1080-81
2. Rutkow IM, Robbins AW. Demographic, classificatory and socioeconomic aspects of hernia repair in the United States. *Surg Clin North Am*. 1993;73:413-26

3. Grant AM. The EU Hernia trialist collaboration; Repair of groin hernia with synthetic mesh; A metaanalysis of randomized controlled trials. *Ann Surg.* 2002; 235(3): 322-32.
4. Stoppa R, Wantz GE. The history of hernias, Henry Fruchaud (1894-1960): a man of bravery, an anatomist, a surgeon. *Hernia.* 1998;2:45-47
5. Cheatle GL. An operation for the radical cure of inguinal and femoral hernia. *BMJ.* 1920;2:68-69.
6. Nyhus LM, Condon RE, Harkins HN. Clinical experience with a preperitoneal hernia repair for all types of hernia of the groin. *Am J Surg.* 1960;100:234-243.
7. Read RC. Preperitoneal herniorrhaphy: a historical review. *World j Surg.* 1989; 13:532-539.
8. Wantz GE. Giant prosthetic reinforcement of the visceral sac. *Surg Gynecol Obstet.* 1989;169: 408-417
9. Abrahamson J. Etiology and Pathophysiology of primary and recurrent groin hernia formation. *Surg Clin N Am.* 1998;78(6):953
10. Fagan SP, Awad SS. Abdominal wall anatomy: the key to a successful inguinal hernia repair. *Am J Surg.* 2004;188(3s-8s)
11. McKernan JB. Extraperitoneal prosthetic inguinal hernia repair using an endoscopic approach. *Int Surg.* 1995;80: 26-28.
12. Felix EL, Michas CA, Gonzalez MH Jr. Laparoscopic hernioplasty, TAPP vs. TEP. *Surg Endosc.* 1995;9: 984-989
13. Liem MSL, van Vroonhoven TJMV. Laparoscopic inguinal hernia repair. *Br J Surg.* 1996;83: 1197-1204
14. Mirilas P, Colborn GL, McClusky DA, Skandalakis LJ, Skandalakis PN, Skandalakis JE. The History of Anatomy and Surgery of the Preperitoneal Space. *Arch surg.* 2005;140:90-94.
15. Totte E, Van Hee R, Kox G, Hendtckx L, Van Zwieten KJ. Surgical Anatomy of the Inguinal Region: Implications during Inguinal Laparoscopic Herniorrhaphy. *Eur Surg Res.* 2005;37:185-190
16. Lowham AS, Filipi CJ, Fitzgibbons RJ, Stoppa R, Wantz GE, Felix EL, Crafton B. Mechanisms of Hernia Recurrence After Preperitoneal Mesh Repair Traditional and Laparoscopic. *Ann. Surg.* 1997;225(4):422-431.
17. Stoppa R, Diarra B, Verhaeghe P, et. al. Some problems encountered at reoperation following repair of groin hernias with preperitoneal prostheses. *Hernia* 1998;2:35-38.
18. Uzzo RG, Lemack GE, Morrissey KP, et al. The effects of mesh bioprosthesis on the spermatic cord structures: a preliminary report in a canine model. *J Urol.* 1999;161:1344-1349.
19. Nyhus LM. Ubiquitous use of prosthetic mesh in inguinal hernia repair; The dilemma. *Hernia* 2000;4(4):184-6.
20. Amid PK, Bendavid R, Fitzgibbons RI, et. al. Surgery Round table-Current issues in inguinal herniorrhaphy. *Medscape portals.* 2000;
21. Pelissier EP. Inguinal hernia. The size of the mesh. *Hernia.* 2002;5: 169-171.
22. Shin D, Lipshultz LI, Goldstein M, et al. Herniorrhaphy with polypropylene mesh causing inguinal vasal obstruction: a preventable cause of obstructive azoospermia. *Ann Surg.* 2005;241:553-559 .

23. Hollinsky C, Hollinsky KH. Static Calculations for Mesh Fixation by Intraabdominal Pressure in Laparoscopic Extraperitoneal Herniorrhaphy. *Surg Laparosc Endosc Perc Tech*. 1999;9(2):106-109
24. Knook MTT, Rosmalen AC, Yoder BE, Kleinrensinky GJ, Sniijders CJ, Looman CJ. Optimal mesh size for endoscopic inguinal hernia repair. A study in porcine model. *Surg Endosc*. 2001;15: 1471-1477
25. Weibel ER (1979) Practical methods for biological morphometry, vol 1. Stereological methods. Academic press, London New York, pp 1-27
26. Abdalla RZ, Mittelstaedt WE. The importance of the Hesserts triangle in the aetiology of inguinal hernia. *Hernia* 2001;5:119-23
27. Bhatia P. Suviraj J.J. Understanding Endoscopic Anatomy in Laparoscopic Hernia Repair: a step by step approach, a global hospital & endosurgery institute, 2003: 4.1-4.23
28. Flament J.B. Avisse C, Delattre J.F. Anatomy of the abdominal wall. In: Bendavid R, ed. *Abdominal Wall Hernias, Principle and Management*. New York: Springer, 2001:39-63.
29. Colborn G.L. and Skandalakis J. E. Laparoscopic inguinal anatomy in *Applied anatomy: Hernia* (1998) 2: 179-191
30. Bhandakar, D.S. Shankar, M. Udivadia, T. E. Laparoscopic surgery for inguinal hernia; current status and controversies. *J. Min Access surg sept* 2006 2 (3); 178-186
31. Wantz, G. E. preperitoneal hernioplasty with unilateral giant prosthetic reinforcement of the visceral sac *contemp surg* 1994; 44: 83-89
32. Woolshock, T; Konerdig, M. A. Dimensions of the MPO: A human cadaver study; *Hernia* 2009 Dec 13 (6); 639-642
33. Liebel, B. J. Schinudt, C. G. Kraft, K. Uluch, M. Bitner, R, Recurrence after endoscopic TAPP causes, Reparative techniques and results of the operation. *J. Am. Coll surg* 2000 199(6) 651 - 655
34. Klinge U, Klosterhalfen B, Muller M, Ottinger AP, Schumpelick V. Shrinking of polypropylene mesh in vivo: an experimental study in dogs. *Eur J Surg*. 1998;164(12):965-969
35. Andrzej, J. Jalyriski, M. Smigielski, J. Brocki, M. Videosurgery and other miniinvasive techniques 2011: 6(1); 19-23
36. Jonas, J. : the problem of mesh shrinkage in laparoscopic incisional hernia repair, *Zentralbi Chir* 2009; June 134(3) 209 - 213
37. Gonzalez R, Fugate K, McClusky D III, Ritter EM, Lederman A, Dillehay D, Smith CD, Ramshaw BJ (2005) Relationship between tissue ingrowth and mesh contraction. *World J Surg* 29: 1038-1043
38. Kapoor, V. K. and Roberts, K. E. Open Inguinal Hernia Repair; *Medscape portals*; March 13; 2014
39. J. R. Eriksen. I. Gogenur. J. Rosenberg, choice of mesh for laparoscopic ventral hernia repair; *Hernia* (2007) 11: 481- 492
40. Gupta, S.K and De Bond, J.R. Prosthetic material and their interactions with host tissue. In *Hernia infections*: Ed. Deysine Maximo. Marcel Decker Inc. 2004; Chap 5:85.