

## Management of Giant Craniofacial Ossifying Fibroma – Case Series Report.

**J. Moshy.**

Department of Oral and Maxillofacial surgery, Muhimbili University and Allied Health Sciences, P.O.Box 65014, Dar-Es-Salaam, Email: jeremiah.moshy@yahoo.com

*Although ossifying fibroma (OF) is a slow growing neoplasm, some lesions may behave aggressively reaching massive proportions that may demand special treatment. OF of the head and neck is most commonly described in the mandible and maxilla. A few isolated reports in the literature exhibit the rare existence of this lesion in the nasal bone, orbit, ethmoid sinus, sphenoid sinus, frontal sinus, temporal bone, and intracranial region. Three cases of massive OF of the midface with intracranial extension are reported. The management protocol of these lesions is presented and discussed.*

**Key words:** Cranial facial giant ossifying fibroma ; management protocol.

### Introduction

Ossifying fibroma is a neoplasm forming part of the spectrum of Fibro-osseous lesions of the jaws. Although ossifying fibroma is a slow growing neoplasm, some lesions may behave aggressively reaching massive proportions that may require special treatment<sup>1</sup>. Because of its aggressiveness nature an early detection and a complete surgical excision is essential. OF of the head and neck is most commonly described in the mandible and maxilla. A few isolated reports in the literature exhibit the rare existence of this lesion in the nasal bone, orbit, ethmoid sinus, sphenoid sinus, frontal sinus, temporal bone and intracranial region<sup>2,3,4</sup>. This article reports 3-cases of massive OF of the midface with intracranial extension together with their management. The aim of this work is to draw attention of clinicians on these long standing, destructive expansile lesions on their management protocol which required a team approach by maxillofacial surgeon, ENT- surgeon, Neurosurgeon and Ophthalmologist.

### Case reports

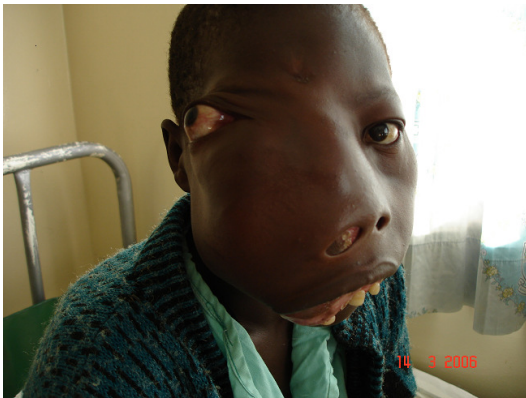#### Case- 1

In 2006, a 26- year- old woman presented to our clinic complaining of a huge right midface swelling which had been present since 2000 ( Figure 1 ). The swelling was painless and was associated with some difficult in breathing . Examination revealed a giant hard swelling involving the right midfacial region .The overlying skin was normal and there was no sign of inflammation. It involved the right nose, right eye, which were pushed laterally. There was associated proptosis of the right eye but there was no loss of vision .The hard and soft palate were bulging intraorally and teeth 12, 13, and 21 were lingually displaced. The overlying mucosa appears intact. Radiographic examination revealed a giant expansile lesion involving the entire right midface with extension to the middle cranial fossa. The lesion was clinically demarcated by a mixed radiopaque / radiolucence appearance.

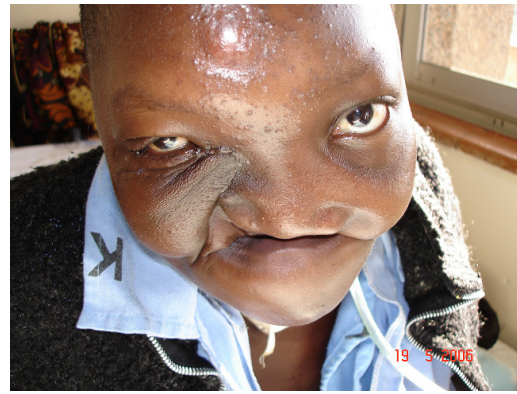An incisional biopsy was performed under local anesthesia. The histological analysis showed numerous trabeculae of neoplastic bone uniformly dispersed in a well vascularized proliferative cellular fibrous tissue stroma. Based on these clinical, radiologic, and histopathologic features, a diagnosis of ossifying fibroma (OF) was made.

Under general anesthesia a tracheotomy was done first followed by tarsorrhaphy and pharyngotomy. A coronal incision was used to approach the tumor and a craniotomy was done to enable the tumor to be pushed downward. A Weber Ferguson and circumvestibular incisions was subsequently made, which enable the tumor to be separated from the maxillofacial structures and delivered through an intraoral route. The right nasal membrane was found to be perforated. It was repaired and supported

by a stent inserted through the right nostril. The defect was packed with a gauze soaked in a betadine and was removed on the fourth day. Postoperative healing occurred without complications except three seizures that happened in the second week postoperatively. They were treated by barbiturates. The postoperative final appearance was far from acceptable and with serious threat to some vital functions like vision and breathing (fig. 2). She however denied obturator for sealing the oral defect and for supporting the collapsed facial soft tissues.



**Figure 1.** Patient with OF involving Rt midface, Nose, orbital cavity. See lateral displacement of the eye ball and the nose.



**Figure 2.** Patient in Figure 1. After operation. Note Postoperative Deformity of the face.

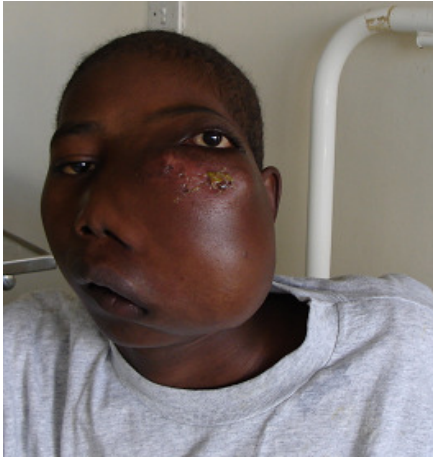## Case-2

In 2006, a 14-year-old boy presented to our clinic complaining of a huge left midface swelling which had been there for eleven months and was progressively increasing in size (fig. 3). The swelling was painless and was associated with decrease in vision of left eye and loss of weight. He had several admissions because of this problem and between January and February 2006 he received 2- cycles of chemotherapy before referral to our centre as the lesion was clinically suspected to be Burkitts Lymphoma. However it did not respond. Examination revealed a giant hard swelling involving the right midface region with extension to the left orbit, nose, and supraorbital region. There was displacement of the left nose to the right and proptosis of the left eye. The movement of the left eye was normal but with decrease in vision. The overlying skin was ulcerated at the inferior orbital margin. Intraorally, the hard and soft palate was involved and all teeth in the second quadrant were displaced.

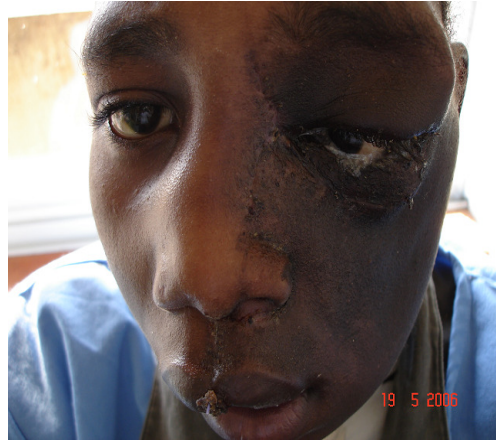The mucosa was intact. Radiographic examination revealed a giant expansile lesion involving the entire left midface region with extension to frontal, ethmoid and sphenoid sinuses.

The lesion was demarcated and demonstrated globular opacities dispersed within it. An Incisional biopsy was performed under local anaesthesia in which histological analysis showed numerous trabeculae of neoplastic bone uniformly dispersed in a well vascularised proliferative cellular fibrous stroma. There was uniform cellularity and mitotic figures were absent. Based on these clinical, radiologic, and histopathological features, a diagnosis of OF was made.

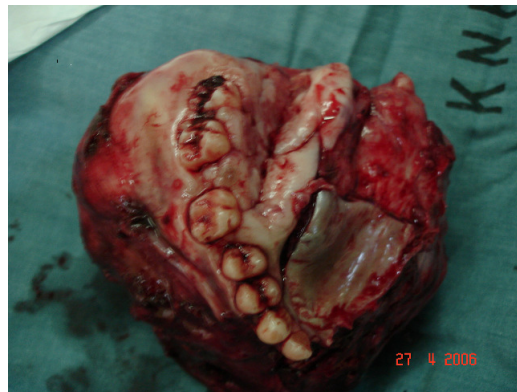
Under general anesthesia a tracheotomy was performed and nasogastric tube was inserted through the right nostril. Weber Ferguson and circumvestibular incisions were used to approach the tumor. The tumor was easily enucleated and it has smooth margins and a size of about 6x 6 cm. in greatest diameter (fig. 4). The frontal, ethmoid and sphenoid sinuses were found to be perforated. The defect was packed with gauze soaked in a betadine and was removed on the third day. Seven days postoperatively, obturator was constructed to close the introral defect and to assist the patient in eating. However the patient remained with serious facial deformity of the left midface (fig. 5).



**Fig. 3.** Patient with OF of the Lt midfacial region.



**Figure 4.** Patient in Figure 3 After operation. Note the postoperative deformity.



**Figure 5.** Tumor removed from patient in Figure 3.

### Case- 3

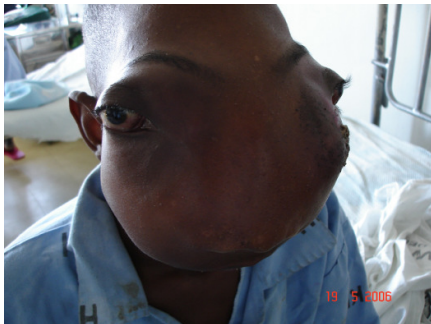In 2006, a 14-year-old boy presented to our clinic complaining of a huge bilateral midface swelling which had been present since 2003 (fig. 6). The swelling was painless and was associated with difficult in eating, breathing and loss of site of both eyes. Examination revealed a giant hard swelling which involved the midface bilaterally. The swelling extends to supraorbital regions. Both eyes were displaced laterally and with associated proptosis. There was increased intercanthal distance and deformation of the nose. One pupil was fixed and dilated and no reaction to light. Intraorally, both soft and hard palate were involved and bulged into the oral cavity. All teeth were displaced and the occlusion was deranged. Radiographic examination revealed a giant expansile lesion involving the midface with extension to both anterior and middle cranial fossae. The lesion was demarcated and with globular opacities dispersed within it (fig. 7). Both carvenous sinuses were involved and there was displacement of the right middle cerebral artery (fig. 8 and 9).

An Incisional biopsy was performed under local anaesthesia and histological analysis showed numerous trabeculae of neoplastic bone uniformly dispersed in a well vascularised proliferative

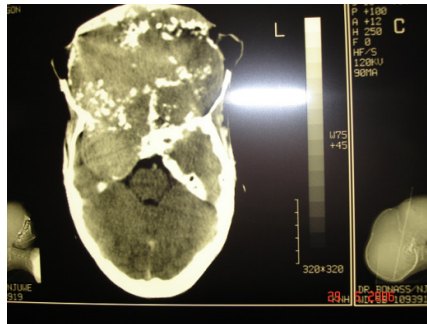


cellular fibrous tissue stroma. There was uniform cellularity and mitotic figures were absent. Based on these clinical, radiologic and histopathologic features, a diagnosis of OF was made.

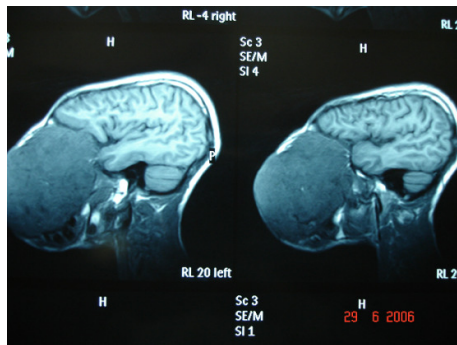
Under general anaesthesia a tracheostomy was performed and followed by tarsorrhaphy for protection of cornea. Bicoronal flap was raised and craniotomy was performed to approach the tumor (fig. 10). The tumor was separated from the dura and removed in piece meals. The part which involved the middle cerebral artery was not removed due to the fear of bleeding. Weber Ferguson and circumvestibular incisions were used to approach and remove the maxillofacial part of the tumor .The defect left behind in the maxillofacial region was packed by gauze soaked in a betadine and it was removed on the 4<sup>th</sup> day postoperatively. The craniotomy was closed and bicoronal flap was stitched back to its original position. Central venous line was inserted for feeding. Postoperative healing was good but the patient remained with severe deformity of the midface (fig. 11)



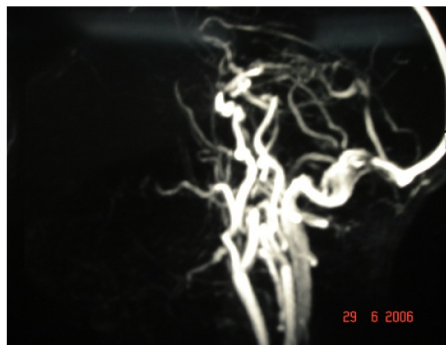
**Figure 6 .** Patient with OF involving midface bilaterally.



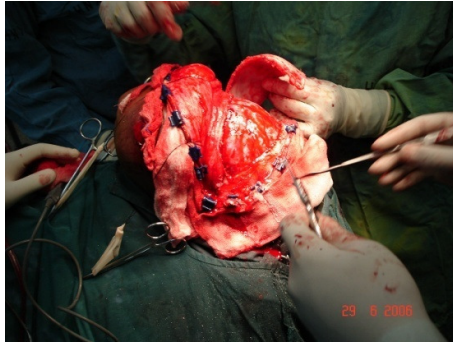
**Figure 7.** CT-scan showing extension of the Tumor to anterior and middle cranial fossae .



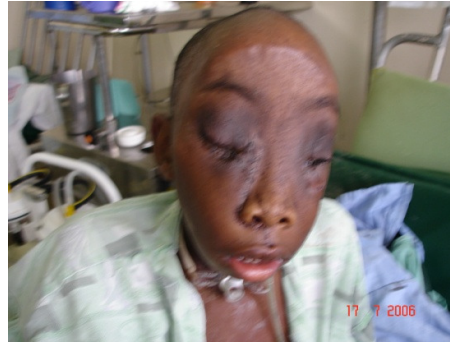**Figure 8.** MRI showing delineation of the tumor from brain tissue .



**Figure 9.** MRA displaying intracranial vessels.  
See the displacement of middle cerebral artery by the tumor .



**Figure 10.** Craniotomy procedure to Approach the tumor.



**Figure 11.** Patient in Figure 6 After the operation. See the gross deformity of the face .

## Management Protocol

### *Preoperative management*

The preoperative should include:

- Clinical evaluation (assessment) of the primary tumor and the status of the lymph nodes. This should include detailed history on how the lesion started, progressed and if there's any associated symptoms. It should also include proper physical examination of the tumor, associated structures and patient in general.
- Radiological assessment of the extent of bone involvement and the presence of soft tissue extension. This should include plain x-rays especially for small lesions and will give you the radiographic appearance of the tumor itself, associated structures (eg. Teeth) and status of the margins. For extensive lesions like the ones described will need CT-scan for evaluation of the extent and involvement of important craniofacial structures. MRI and MRI-Angiography will be needed for those lesions which have already extended to the cranium. Note that each radiological investigation has got its importance in the management for these lesions and hence radiological investigation ordered should focus on the size, location and extent of the lesion.
- Nutritional status assessment. This is important since most of the patient with extensive craniofacial lesions have nutritional deficiency. They cannot chew or swallow properly because of the tumor extension to oral cavity and the derangement of the occlusion; some of them are severely anaemic. Nutritional deficiency if found should be corrected before surgery.
- Histological confirmation of the tumor .Its important before surgery in order to know the type of the tumor you're dealing with. Also it's important to differentiate other tumors like osteosarcoma, chondrosarcoma, which have histological appearance similar to ossifying fibroma and of which will need different surgical management.
- Specialist assessment for extensive craniofacial ossifying fibroma, since many important craniofacial structures are involved (nose, orbital cavity, eye, maxillary sinus, ethmoid sinus, anterior cranial fossa, middle cranial fossa and even perforation of the dura). Therefore Maxillofacial surgeon, Neurosurgeon, ophthalmologist, ENT-surgeon is highly needed in order to plan how to manage those structures during the operation and after operation. Remember some of the patient presents with airway obstruction and they might need tracheotomy even before the operation (for example in case- 3).
- Assessment of the patient for fitness of surgery. This assessment should include the assessment of the liver function, renal and cardiovascular function. It should also include blood grouping and x-matching and assessment of fluid status. Therefore the

following investigations should be performed (urea and electrolytes, serum creatinine, liver function test, chest x-ray especially in old patients and full haemogram). If there is any abnormality in regard to the test performed, necessary corrections should be done before the surgery. Liver and Renal systems are important in handling the drugs given, including anesthetic drugs. Cardiovascular system is important in ensuring good circulation of oxygenated blood which is important during anesthesia and during postoperative wound healing phase.

- Explanation to the patient and family the basic nature and extent of the operation. Because of the extensiveness of these lesions, the postoperative deformity is high and is usually associated with psychological effects. The patient and the family must be informed so that they could prepare to handle these problems.
- Prophylactic antibiotic should be mandatory for this kind of patient since the operation period is long and extensive with the involvement of the cranial cavity. This is important in preventing the patient from developing postoperative infection for example meningitis, brain abscess and others.

### ***Intraoperative management***

Due to the extensiveness of these lesions and the involvement of important structures in the craniofacial region, multidisciplinary management should be followed. Maxillofacial surgeons, Neurosurgeons, ENT-surgeons, and Ophthalmologist should be involved during the operation. They should be part of the operating team. Wound closure should be proper with the avoidance of dead space. Drainage should be inserted if required but most of these operations need packing the defect with gauze soaked in a beta dine or antibiotic cream. The patient should be covered with proper antibiotics and pain should be controlled with proper analgesics. They should be nursed at the intensive care unit until they are stabilized.

### ***Postoperative***

The postoperative management should involve proper wound surveillance. This will include proper dressing of the wound, inspection of the wound for infection, postoperative wound bleeding monitoring, postoperative blood pressure monitoring, fluid and electrolyte monitoring. Proper nutrition is important during postoperative period. Proper wound healing will not occur in a situation where there is nutritional deficiency. Nutritional deficiency also increases the rate of wound infection.

### **Discussion**

The importance of the above protocol offers a systematic approach to the diagnosis and proper planning for surgery. It also reduce the risk of intraoperative and postoperative complications since complication risk factors will be pointed out early and corrected before the surgery . All the 3-cases reported were managed through the above protocol and have shown good results as shown in figures 2, 5, and 11. Proper clinical evaluation (history and physical examination) will give you characteristics relative to ossifying fibroma (OF). Clinically OF most commonly present as a painless expansion of the jaw. It is asymptomatic and slow growing but in some cases may show aggressive behavior. Deformity and migration of teeth may be an early clinical feature <sup>6, 7, 8</sup>.

Review of the literature shows difficult in establishing a definitive diagnosis through a single modality, for example clinical evaluation alone<sup>9</sup>. Therefore adjunctive radiographic aids as well as histopathological studies are important to arrive at definitive diagnosis. This is important to differentiate OF from other benign and malignant neoplasms which may resemble the lesion. The radiographic modalities important for evaluation this tumor ranged from plain x-rays, CT-scan, magnetic resonance imaging and magnetic resonance angiography. Each of these radiographic modalities has an importance in the management of OF Involving craniofacial region. Plain x-ray will show radiographic characteristic of mixed radiopaque and radiolucent, well demarcated borders around the lesion and resorption of the roots of teeth associated with the lesion. CT-scan is important for extensive lesions involving the paranasal sinuses, eye, nose, and those with intracranial extension.

CT-scan is superior to other radiographic modalities whenever extension into the orbit is suspected. It demonstrates the involvement of important craniofacial structures, location and nature of the lesion. According to Ito<sup>5</sup>, CT-scan is useful in identifying the tumor and its extension into the intracranial and infraorbital cavity. Magnetic resonance angiography (MRA) is important for intracranial extension of the lesion. It is important in ruling out the involvement of the intracranial vessels. This has been exemplified in case-3 where the intracranial extension of the tumor has displaced the middle cerebral artery. Magnetic resonance imaging (MRI) is also important for intracranial extension of the tumor. It provides multiplanar information about the extent and characteristic of the lesion.

Reaume et al.<sup>10</sup> concluded that, multiple parameters should be evaluated before a specific diagnosis of OF is assigned. This is important criteria especially in the management of these types of giant lesions with intracranial extension. Note that craniofacial OF can be differentiated from other lesions affecting craniofacial area on combined clinical, radiological and morphological (histological) grounds<sup>12,13</sup>. OF may resemble well differentiated osteosarcoma as OF may be more cellular and may have high number of mitosis than osteosarcoma<sup>11</sup>. Also OF must be well diagnosed as it has cancer like radiographic appearance<sup>7</sup>. Therefore biopsy of the lesion is an important aid in the management of the craniofacial OF. If the prescribed protocol for the management is followed, proper diagnosis will be obtained and there would be no mismanagement of the patient like in case-2 where the patient was given 2 cycles of cytotoxic drugs.

The approach for excision of this type of expansile long standing lesions depends on the location in the craniofacial region. The location of the tumor will determine the type of incision to be used. When there is intracranial extension, combined craniofacial approach would be relevant, hence a combined coronal, Weber- Ferguson and circumvestibular incisions should be used to approach and excise the tumor. When the base of the skull is not involved, and the lesion is totally limited to the midface region, then Weber-Ferguson and circumvestibular incisions are enough to approach and excise the tumor. Following excision of the tumor, reconstruction of the defect left behind in the form of surgical splint or prosthesis should be considered. This is important since it improves the patient's remaining quality of life. However, for those extensive lesions as in case -3, it is impossible to provide surgical splint or prosthesis since the deformity is so extensive with minimal facial skeleton remained. This underlined the importance of explanation to the patient and family the basic nature and the extent of the operation in order to prepare them to handle the situation. I therefore remind clinician to be aware of these long standing expansile lesions of the midfacial region and the importance of following the explained management protocol in order to obtain good surgical results.

## Conclusion

It is worth to note that the protocol avoid misdiagnosis, mismanagement and postoperative complications if properly followed. This is especially when dealing with massive craniofacial ossifying fibroma.

## Acknowledgement

I wish to thank the Kenyatta National Hospital Administration for allowing me to report these cases. Special thanks go to the specialists who were involved in the management of the three cases reported in this article.

## References

1. Khanna JN, Andrade NN: Giant ossifying fibroma. Case report on a bimaxillary presentation. *Int J Oral Maxillofac Surg* 1992; 21: 233-235.
2. Tomita T; Huvos AG; Shah J; Sundareson N: Giant ossifying fibroma of the nasal cavity with intracranial extension. *Acta Neurochir (Wien)* 1981; 56: 65-71.
3. Levin P A; Wiggins R; Archibald RW; Britt R: Ossifying fibroma of the head and neck: Involvement of temporal bone and unusual challenging site. *Laryngoscope* 1995; 16: 1132-1134.

4. Takayama H ; Koyama H ; Iwata T ; Murase I ; Mukai M ; Mukarami H : A case of ossifying fibroma of the skull . No Shinkei Geka 1985; 13: 669-673.
5. Ito H; Hasagawa T; Hwang WZ; Yamotos S: Ossifying fibroma for the frontoethmoid sinus. Surg Neurol 1984; 22: 397-402.
6. Charles A.Waldron: Fibro-osseous lesions of the jaws. J Oral Maxillofac. Surg. 1985; 43: 249-262.
7. Tarsar F; Giray CB; Tasman U; Saysel MY: Ossifying fibroma. A case report .Turk J Pediatr. 1996; 38: 265-270.
8. Lan Su; Dwight R; Charles A. Waldron: Distiguishing features of focal cemento-osseous dysplasia and cemento-ossifying fibromas II. A clinical and radiographic spectrum of 316 cases. Oral Surg. Oral Med. Oral Pathol. Endod. 1997; 84: 540-549.
9. Walter JM Jr; Terry BC; Small EW; Matterson SR; Howell RM: Aggressive ossifying fibroma of the maxilla. J Oral Surg. 1979; 37: 276-286.
10. Reaume CE; Schmid RW; Wesley RK: Aggressive ossifying fibroma of the mandible. J Oral Maxillofac. Surg. 1985; 43: 631-635.
11. Sloomweg PJ : Maxillofacial Fibro-osseous lesions : Classification and differential diagnosis : Semin . Diagn. Pathol 1996; 13: 104-112.
12. Jeremiah Moshy, Elizaberth Dimba, Tom Ocholla, Mark Chindia: Characteristic radiological and histologic patterns of fibrous dysplasia and ossifying fibroma of the jaws. Surgical Science 2012; 3:189-193.
13. J Moshy; HA Mwakyoma; ML Chindia. Evaluation and Histological Maturation Characteristics of Fibrous Dysplasia and Ossifying Fibroma. A Case Series. EAMJ 2010; 87:42-46.