

## Management of Ingested Foreign Bodies in Paediatric Patients: An Experience from a Tertiary Hospital in Ethiopia

A. Tadesse<sup>1</sup>, A. Feyo<sup>2</sup>

<sup>1</sup>Assistant professor and consultant pediatrics surgeon, Department of surgery, school of medicine, Addis Ababa University

<sup>2</sup>Final year surgery resident, Department of surgery, School of Medicine, Addis Ababa University

*Correspondence to:* Dr. Amazene Tadesse, Email: amezenet@yahoo.com

**Background:** *The problem of FB ingestion is commonly seen in young children, with most of the cases being aged between 6 months and 5 years. Oesophagoscopy is the gold standard for their management although McGill forceps, Fogarty catheter and bouginage may also be used when appropriate.*

**Methods:** *This was a retrospective study of paediatric patients presenting with features of FB ingestion at Black Lion Hospital between September 2011 and February 2013. A total of 85 cases were analyzed.*

**Results:** *A total of eighty five (61.5%) males and 33 (38.8) females with a mean age of 2.86 years were analyzed. Vomiting (70.6%) and difficulty in swallowing (50.6%) were the most common symptoms. Coins were the most commonly ingested FB items. Plain X-rays located 78.85% of FBs in the proximal oesophagus. The vast majority of patients (92.9%) had their FBs retrieved using McGill forceps. Foley's catheter was used in 15 (17.6%) and Oesophagoscopy in 9 (10.6 %) cases*

**Conclusion:** *McGill's forceps with the aid of a McIntosh laryngoscope is a safe and effective method for proximal oesophageal foreign body removal.*

### Introduction

Foreign body (FB) ingestion is a problem commonly seen in accident and emergency departments, occurring mostly in children (80%), especially those ones aged 6 months to 5 years<sup>1-5</sup>. Even though majority of ingested FBs pass spontaneously, some of the ingested FB can lead to major complications. FBs with smooth edges usually don't pose significant problems, but sharp foreign bodies, not timely retrieved may penetrate the wall of the viscus and cause complications. The same goes for button type batteries.<sup>1,2,3</sup> According to the literature, 90% of ingested FBs pass through the gastrointestinal tract without complications, 10-20% necessitates endoscopic removal whereas only 1% will finally need surgical intervention<sup>1</sup>.

Although a variety of methods have been described for removal of ingested FBs, rigid oesophagoscopy is the gold standard against which other treatments are compared. It is safe and effective but relatively expensive; unfortunately the expertise may not be readily available in some ill equipped medical institutions in the developing world.<sup>1,2</sup> MC-gill forceps, Foley catheter, Fogarty catheter and oesophageal bouginage are also used for FB removal where appropriate<sup>1,2</sup>.

In clinical practice, one is often confronted with the dilemma of choosing the appropriate treatment modality. The purpose of this retrospective study is to analyze our experience, assess characteristics of ingested FB and methods of treatment.

### Patients and Methods

This was a study of all paediatric patients undergoing oesophageal FB removal at Tikur Anbessa Hospital (TAH) from September 2011 to February 2013. The vast majority of ingested FBs are managed in this main referral and University teaching hospital in Addis Ababa. A total of 110 cases of FB ingestion were treated in the hospital during the study period. In addition, case notes and charts of 85 patients who had undergone treatment before September 2011 were also retrieved and studied.

Data was collected using a structured questionnaire on age, sex, address of the patient; time elapsed before presenting to the hospital, type and location of the FBs, diagnostic tests, treatment techniques utilized and outcome of the treatments. Complications developing during and after procedures were also recorded. The FBs locations were recorded as pharyngeal, proximal esophagus, middle esophagus, distal esophagus, appendix and rectum depending on the radiological or treating physician impression finding documented in the patient's chart. At our institution, most esophageal FB extraction is performed by senior general surgery residents using either McGill forceps or Foley's catheter method. Paediatric surgeon or pediatric surgery fellow will be consulted for sharp objects, radiolucent objects, long stay coins or failed McGill or Foley catheter procedure for endoscopic evaluation and removal.

All procedures were performed as inpatient procedure under general anaesthesia which was delivered via a mask for McGill and Foley's catheter procedure while those undergoing oesophagoscopy had anaesthesia delivered via an endotracheal tube. There were no anesthesia related complications. After data collection, variables were categorized, compiled and presented on tables, pie charts and analysis done.

## Results

There were a total of eighty-five children, 52 (61.5%) males and 33 (38.8%) females aged between 3 months and 11 years in the study. The mean age was 2.86 +/- 1.82 years old. Male to female ratio was 1.58. Seventy three (85.9%) patients were aged six months to five years. Most of the patients (61.2%) were living out of Addis Ababa. Fifty-six (65.9%) patients were referred from both peripheral and city hospitals.

The duration of presentation ranged from thirty minutes to two years. In 39(45.9%) patients the duration of illness was less than 24 hours. The presentation was after one week in 20(23.5%) patients (Table 1). Seventy-three (85.9%) patients had definitive history of FB ingestion. Patients had mixture of symptoms and only one (1.2%) patient was asymptomatic. The commonest presenting complaints were 'vomiting' and difficulty of swallowing occurring in 60 (70.6%) and 43(50.6%) respectively. Drooling of saliva 9(10.6%) and repeated respiratory tract infections, 4(4.7%) were also a presenting features.

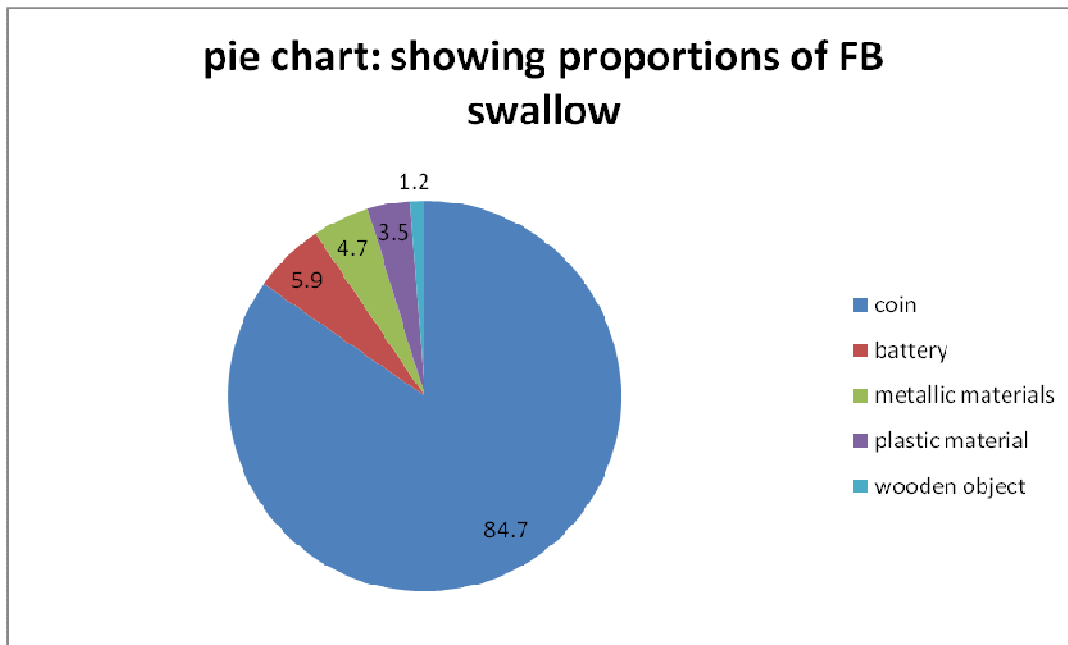
The most common FB ingested was coin recorded in 72 (84.7%) patients, followed by button batteries 5 (5.9%) and metallic materials 4(4.7%). Other ingested FBs included plastic pieces 3 (3.5%) and small wooden object 1(1.18%). (pie chart). All patients were x-rayed to localize the objects and 80 (94.1%) of them were radio opaque. Only 5(5.9%) were radiolucent. So depending on the plain x-rays, 67 (78.8%) FBs were lodged in the proximal esophagus, 11 (12.9%) in middle oesophagus, 1 (1.2%) in the appendix and 1 (1.2%) in the rectum. Of the radiolucent objects, a CT scan was done for 1 patient localized the FB in the middle esophagus and oesophagoscopy localized 1(1.2%) in distal oesophagus. (Table 1)

The majority of our patients 79(92.9%) were successfully treated. McGill forceps was used in 53(62.4%), Foley catheter method in 15(17.6%) and rigid oesophagoscopy in 9(10.6%). Appendectomy was done in 1(1.2%) who had a nail lodged in the appendix and anal dilatation and extraction of coin with forceps from rectum for one year was done in 1(1.2%) child aged one year & six months old following post PSARP anal stenosis.(Table 3) In six patients (7.1%) presenting with coin ingestion and an and having radio-opaque shadow in the oesophageal lumen, no FB was found at oesophagoscopy, the FB having spontaneously passed per rectum.

In proximal esophageal FBs, of the 54 attempts done under direct laryngoscope and McGill forceps (including 2 cases of pharynx) removal was successful for 52( 96.3%) and failed in 2 (3.7%) patients. Use of Direct laryngoscope and McGill's forceps in removal of FB was successful in 52 (96.3%) cases with proximal oesophageal and pharyngeal foreign bodies and failed in 2 (see table 3). Foley catheter

technique was successful in 10 (83.3%) out of twelve cases in whom post-operative X-rays located the foreign bodies in beyond the oesophagus. Oesophagoscopy done for 3 cases of proximal esophageal FBs, removal was successful only in 1 (33.3%) and failed in 2 (66.7%). In oesophagoscopy failed removal, Foley catheter method was able to remove 1 battery and 1 coin successfully.

In mid oesophageal FBs, in 2 patients removal was tried with McGill forceps and laryngoscope, removal was successful in one (50%) and failed in one (50%), which was removed by Foley catheter. Foley catheter used in 6 patients, removal was successful in 5 (83.3%) and failed in 1 (16.7%). In a failed procedure repeat x- ray showed FB in stomach and expectantly managed. Oesophagoscopy done for 8 patients and removal was successful in 7 (87.5%) and failed in 1 (12.5%). The failed removal with oesophagoscopy was successful with Foley catheter.



There was one case of distal oesophageal FB (hair band) which was difficult to grasp and pushed to the stomach successfully. We had two serious post procedure complications, which happened among cases of battery ingestion. The first complication was in a one year and two months old male child who came after 12 hours of watch battery ingestion and way lodged in the pharynx and removed under direct laryngoscope with McGill forceps. But post procedure the patient developed upper air way obstruction 2° to laryngeal edema and managed with tracheostomy and discharged cured.

**Table 1.** Radiological localization of FB at TAH September 2011 to February 2013

Sites	Frequency	Percentage
Proximal oesophagus	67	78.8
Mid oesophagus	11	12.9
Distal oesophagus	0	0
Appendix	1	1.2
Rectum	1	1.2
Foreign Body not seen	5	5.9

\*\*\*Of the radiolucent FBs, CT was done for one patient which localized the FB in the mid oesophagus; Oesophagoscopy localized one in distal esophagus.

The second complication happened in two years and four months old male child who came seven days after battery ingestion and admitted with the diagnosis of aspiration pneumonia and FB ingestion and removal done with McGill forceps and direct laryngoscope from proximal esophagus. He developed TEF which was managed conservatively.

## Discussion

In this study, children aged 6 months to 5 years were found to be at greatest risk of FB ingestion and this finding is similar to what was reported in previous studies done elsewhere<sup>1-5</sup>. Such children may present with refusal to feed, drooling, vomiting and respiratory symptoms<sup>1, 2, 6</sup>. Such presenting complaints were noticed in our study. A significant proportion (23.5%) of our patients came as late as after one week. The reasons for late presentation included long distance from Addis Ababa, misdiagnosis and less severe symptoms ingested FB. Late presentation contributed significantly to the complications we recorded which included recurrent respiratory tract infection 4(4.7%) and one case of trachea-oesophageal fistula secondary to battery button ingestion. Most previous studies document that the commonest ingested FB was a coin<sup>1-5</sup>, which accounted for 84.7% of cases in this series.

Besides history and physical examination, radiology is a very important diagnostic tool for identification of the nature of the FB and its location. In pediatric population, 60-80% of objects get caught at the level of the cricopharyngeous muscle in the proximal esophagus, 10-20% become trapped at the level of the aortic cross over and 5-20% are found at the level of the lower esophageal sphincter<sup>4</sup>. In our series x-ray showed 78.8% in proximal esophagus and 12.9% in mid esophagus. No radio opaque FB was seen in the distal esophagus. However, oesophagoscopy localized 1(1.2%) radiolucent object in distal esophagus. This is in agreement with other reports<sup>1,4</sup>

Radio-lucent objects in the esophagus, such as plastics or wood are difficult to detect on plain films. In this case CT, contrast radiography or endoscopic examination should be obtained.<sup>4</sup> However, because of its risk of aspiration, high rates of false positivity and false negativity, the use of contrast radiography is not encouraged by some<sup>2</sup>. In our study, a CT scan ordered for one referred patient, managed to localize a radiolucent object in the mid esophagus. We also encourage the use of CT scan if there is high suspicion of radiolucent object and no endoscopic set is available.

The best modality of FB removal has been a subject of much controversy for years. The choice of treatment is influenced by many factors, such as the patient's age, clinical condition, the size and shape of the ingested FB, the anatomic location and the skills of the doctor<sup>1, 2, 4</sup>. The most important consideration is airway control. Once the airway is controlled, any modality allowing direct visualization of the FB may be used for removal<sup>2, 4</sup>. Baral<sup>8</sup> and Cetinkursun S.etal<sup>9</sup> reported success rate of 100% and 96.7% respectively using McGill forceps in proximal esophageal coins. Our success in McGill forceps in proximal esophagus including 2 cases of pharynx was 96.3%. which is similar to the above mentioned authors result.

In 1966, Bigler reported a method of extracting smooth esophageal FBs using a Foley balloon catheter. He hypothesized that distension of the Foley balloon inferior to the FB would dilate the esophagus, free the impaction, and allow safe extraction of the FB<sup>12</sup> subsequently many have adopted and recommended its use in children. Several large studies have documented the safety and reliability for balloon extraction. The review of Dokler et al of 86 children noted that balloon extraction was successful in 86%of children<sup>12</sup>. The review by O'Neill et al noted an 84% success rate for oral extraction<sup>12</sup>. Another review of 302 consecutive children with impacted esophageal coins noted a success rate of 93% without fluoroscopic control.<sup>12</sup> Complications are rare and generally minor after Foley balloon extraction.

We do not attempt balloon extraction, if the FB has been impacted for more than one week, if the FB is not smooth, there is radiographic evidence of esophageal or air way perforation (or sepsis) and if there are underlying structural esophageal abnormalities.<sup>12</sup> The Foley catheter method done by

experienced personnel, involves inserting the deflated catheter orally past the object. The balloon is then inflated and the catheter is slowly with drawn, pulling the FB ahead of it<sup>8</sup>. Foley catheter may be cost effective compared to endoscopy but it does not offer airway protection nor does it allow visual evaluation of GIT. In our study Foley catheter method applied for 12 proximal and 6 midesophageal FBs and success rate was 83.3% for both, which is in agreement with above mentioned studies. In this study, no Foley catheter related complications were noted.

Although a variety of methods have been described for removal of FBs from the esophagus rigid oesophagoscopy is the standard against which other treatments are compared<sup>1</sup>. It is safe and effective but relatively expensive unfortunately the expertise may not be available easily in some centers in the developing world<sup>1,4</sup>. In this study rigid oesophagoscopy was used when sharp metallic objects, long stayed coins and radiolucent FBs were encountered, partly because of the limited number of experts and partly because the majority of the FBs were in proximal esophagus, which can be removed easily with McGill forceps. Overall, we used endoscopy on 12 patients out of whom 9 (81.8%) of the FBs were successfully extracted. Even though failure of the procedure is one of the complications of oesophagoscopy has also been noticed by other authors<sup>2,5</sup>. Old, faulty and defective oesophagoscopes such as that one used in our unit may also contribute to the high failure rate noted in this study.

Complications of FB ingestion can occur throughout the GIT. These include airway compromise, abrasions, perforations, fistula formation, or vascular injuries. With the advent of endoscopy, more FBs are successfully removed resulting in less complications<sup>1,4,10</sup>. In our study such complications happened in two (2.4%) children. Both of them ingested button battery. The complications were upper air way obstruction secondary to laryngeal edema and tracheoesophageal fistula which were managed by tracheostomy and nasogastric suction respectively.

Disk or button batteries are small, coin shaped batteries used in hearing aids, watches, and calculators. The danger of batteries is that they contain mercury, silver, zinc, manganese, cadmium, lithium, sulfur oxide, copper & sodium or potassium hydroxide. If the battery is lodged in the gastrointestinal tract it may cause pressure necrosis, low voltage burns, or ulceration due to liquefaction necrosis stimulated by leakage of the batteries alkaline solution. As little as one hour of contact between the battery & esophageal mucosa may result in injury. Because of those damages endoscopic removal should be done immediately after localization by radiographic imaging. On the anteroposterior projection, disk batteries distinguished from coins by the double density shadow of its bilaminar structure.

Finally, surgery is only considered inevitable when perforation or aorto-esophageal fistula is present, or the extraction is either dangerous or impossible to be done by the endoscopist. The surgical approach depends on the location of the FB.<sup>1,2,4</sup>

### Acknowledgement

We would like to thank Dr. Abebe Bekele for his invaluable assistance.

### References

1. JAA Awe. Overview of the management of swallowed gastrointestinal tract foreign body. *Global advanced Research journal of microbiology* June 2013; 2(6): 099-106.
2. Kalliopi Athanassiadi, M. Gerazounis, E. Metaxas, Nikolitsa Kalantzi. Management of esophageal foreign bodies. *European Journal of Cardiothoracic Surgery* 2002; 21: 653-6.
3. A. Bane, A. Bekele. Management of foreign bodies using flexible endoscopy an experience from Addis Ababa, Ethiopia. *East and central African journal of surgery* Nov/Dec 2012; 17 (3):32-6.
4. R. Byaruhanga. A rare case of a patient with a foreign body in the esophagus for two years which perforated into the mediastinum. *AfrHealth Sci.* 2012 December; 12(4): 569–571.
5. Lu'ukia Ruidas. Gastrointestinal foreign bodies. -In: Loren G. Yamamoto, Alson S. Inaba, Jeffrey K Okamoto, Mary Elaine Patrinos, Vince K. Yamashiroya, eds. *Case based pediatrics*

- for medical student and residents. Honolulu, Hawaii. Department of pediatrics, University of Hawaii John A. Burns school of medicine, April 2002:353-5.
6. AtilaTurkyilmazi. Esophageal foreign bodies, analysis of 188 cases. Turkish Journal of trauma and emergency surgery 2009; 15 (3): 222 -7.
  7. Sewagegyeshiwas, Danteshemeli. Patterns of foreign body in the aero-digestive tract of the pediatric patients in TikurAnbesa Hospital. Ethiopian Journal of Pediatrics and child health July 2010; VI (6):4-13.
  8. Baral BK, et al. Removal of coin from upper esophageal tract in children with McGill's forceps under propofol sedation. Nepal Medical Journal J March 2010; 12 (1): 38-41.
  9. Cetin kursum S, et al. Safe removal of upper esophageal coins by using McGill forceps two centers' experience. ClinPediater (phila) Jan-Feb 2006; 45 (1): 71-3.
  10. Conners GP. A literature based comparisons of three methods of pediatric esophageal coin removal. PediatrEmerg Care April 1997; 13 (2): 154-7.
  11. Russell RT. Tracheo esophageal fistula following button battery ingestion: successful non-operative management. J pediaterurg Feb 2013; 48(2): 441-4.
  12. Danny C. Little, et al. Esophageal foreign bodies in the pediatric population: our first 500 cases. Journal of pediatric surgery 2006; 41: 914-8.