

Results of Operative Fixation of Fractures of the Ankle at a Tertiary Hospital in a Developing Country.

O.J. Ogundele¹, A.O. Ifesanya¹, O.A. Oyewole¹, O.O.Adegbehingbe²

¹Department of orthopaedics and Trauma, University College Hospital, PMB 5116, Ibadan, Oyo state, Nigeria.

²Department of orthopaedics and traumatology, Obafemi Awolowo University, PMB 5538, Ile-Ife, Osun state, Nigeria.

Correspondence to: O.J. Ogundele, Email: ogunjosh@yahoo.com, ogunjosh128@gmail.com.

Background: Operative fixation of ankle fractures is becoming popular in developing countries. The concern however is the outcome of care. The objective was to evaluate the results of open reduction and internal fixation (ORIF) of fractures of the ankle in our hospital.

Methods: All cases ORIF of fractures of the ankle at the University College Hospital (UCH), Ibadan between March 2010 and December 2012 were recruited into the study. The indications for surgery, techniques of fixation, time interval between injury and presentation as well as outcome measures like time to union, complications and functional outcomes were evaluated.

Results: Seventy patients who had ORIF of ankle fractures were studied. Twenty-one (30%) were open fractures while forty-nine (70%) were closed. Sixty (85.7%) patients presented within the first week of injury, 4 (5.7%) after 4 weeks, 4 (5.7%) after 6 weeks and 2 (2.9%) after 52 weeks. Time to union averaged 12.6±4.1 weeks. Complications included wound infection 14.3%, wound dehiscence with exposed implants 2.9%, malunion 8.6% and non union 5.7%. Good to excellent functional outcomes were achieved in 77.1% of the patients.

Conclusion: ORIF is a viable option in the treatment of ankle fractures.

Introduction

Ankle fractures are some of the most common injuries managed by orthopaedic surgeons. Common causes of ankle fractures include trauma which ranges from motor vehicular crashes, motorcycle and pedestrian traffic injuries, sports injuries to falls and assaults. Many ankle fractures are simple and their management is straight forward leading to successful outcomes. Some fractures, however, are unstable, thus posing significant problems and questions about how best to manage them to achieve an optimal outcome¹. Anatomical reduction and satisfactory fixation usually leads to a rapid return of function². Several studies have also indicated that internal fixation of displaced fractures of the ankle gives better results compared to non-operative treatment^{3,4,5}. Fractures of the ankle are heterogeneous and hence the decision to operate is usually individualized^{4,5}. We have employed the AO methods of fracture fixation in our centre in the last 18 years.

The objectives of this study were to evaluate the results of operative treatment of ankle fractures and the functional outcomes.

Patients and Methods

A prospective study of all patients with ankle fractures who had open reduction and internal fixation of fractures of the ankle in our hospital between March 2010 and December 2012 was carried out. A questionnaire was completed for each patient presenting with ankle fracture to the emergency and the surgical outpatient departments. Patients presenting acutely were initially assessed and resuscitated based on the ATLS[®] protocol. Patients with Gustillo and Anderson type IIIb fractures were excluded from the study. Other patients with open fractures had initial wound debridement before operative fixation. Data collated included age, sex, type and patterns of fractures, time interval between injury and presentation in the hospital, indications for surgery, techniques of fixation, outcome measures like time to union, functional outcomes and complications. Functional outcome measurement was determined using the Olerud and Molander scoring system.⁶

Results

Seventy patients who had ORIF for ankle fractures were recruited. Twenty-one (30%) were open fractures while forty-nine (70%) were closed fractures. The ankle fractures consisted of 9 (12.9%) Weber type A, 25 (35.7%) Weber type B and 36 (51.4%) Weber type C fractures. The mean age of presentation is 44.5 ± 2.8 years (peak age 40-49 years, range 17-80 years) with a male: female ratio of 1.3:1. This is shown in Figure 1.

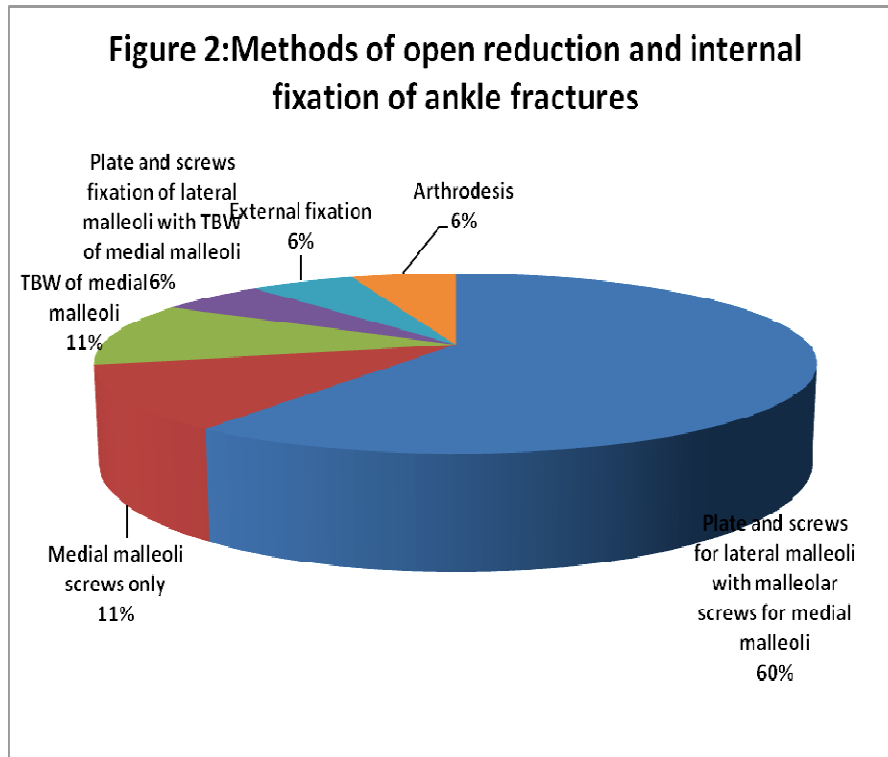
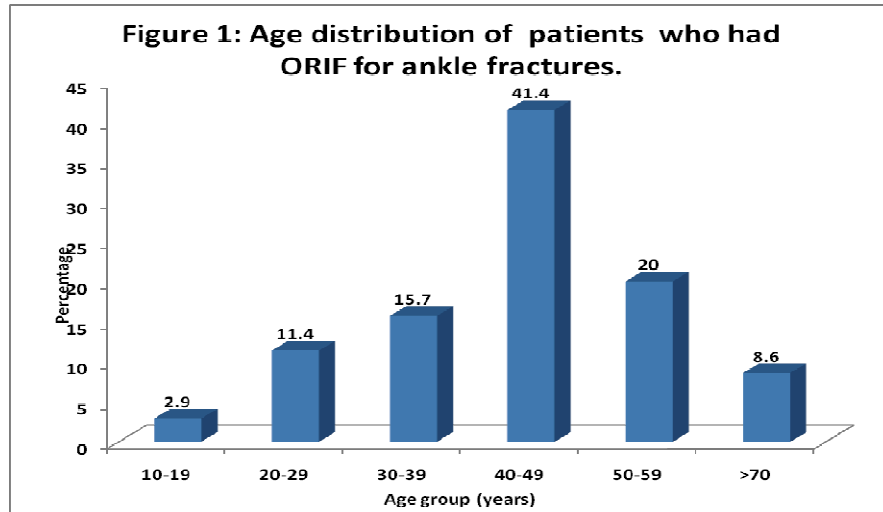
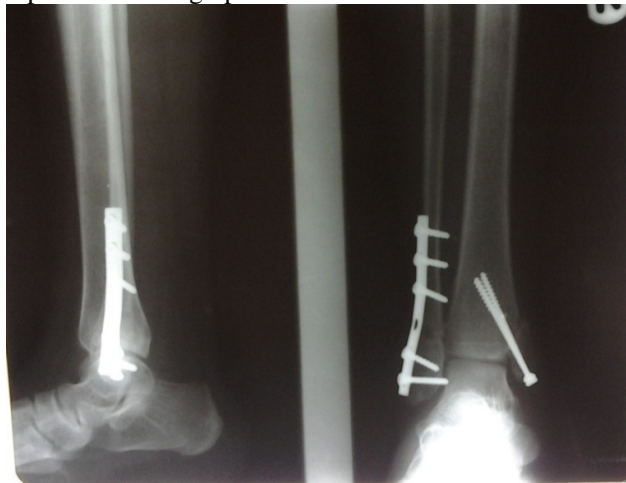

Table 1. Time Interval before Presentation, Types of Ankle Fractures, Complications and Functional Outcomes.

Variable	Type of fracture	0-30	31-60	61-90	91-100	Total
Time interval						
1 week	Closed	0(0.0)	4 (33.3)	8 (66.7)	27 (64.3)	39
	I	2(50.0)	0 (0.0)	4 (33.3)	4 (9.5)	10
	II	0(0.0)	2 (16.7)	0 (0.0)	5 (11.9)	7
	IIIa	0(0.0)	0 (0.0)	0 (0.0)	4 (9.5)	4
4 weeks	Closed	2(50.0)	2 (16.7)	0 (0.0)	0 (0.0)	4
6 weeks	Closed	0(0.0)	2 (16.7)	0 (0.0)	2 (4.8)	4
52 weeks	Closed	0(0.0)	2 (16.7)	0 (0.0)	0 (0.0)	2
Total		4	12	12	42	70
Complications						
Wound infection	Closed	2 (50.0)	0 (0.0)	0 (0.0)	0 (0.0)	2
	I	0 (0.0)	0 (0.0)	2 (25.0)	0 (0.0)	2
	II	0 (0.0)	0 (0.0)	2 (25.0)	0 (0.0)	2
	IIIa	2 (50.0)	0 (0.0)	0 (0.0)	2 (33.3)	4
Wound dehiscence		0 (0.0)	0 (0.0)	0 (0.0)	2 (33.3)	2
Malunion		0 (0.0)	0 (0.0)	4 (50.0)	2 (33.3)	6
Non union		0 (0.0)	2 (100.0)	0 (0.0)	0 (0.0)	2
Total		4	2	8	6	20

0-30= Poor outcome, 31-60=Fair outcome, 61-90=Good outcome, 91-100=Excellent outcome.

Figure 3. Postoperative Radiograph of a Patient Who Had ORIF for Ankle Fractures



Twenty patients (28.6%) had been involved in motor vehicular crashes. Motorcycle injuries accounted for 16 (22.9%) and falls for 22 (31.4%) of the cases. There were 8 (11.4%) pedestrian road traffic injuries and 2 (2.9%) patients each were involved in assaults and bull fights respectively. The average follow-up period was 18 ± 1.3 weeks. Methods of open reduction and internal fixation of ankle fractures is shown in figure 2 and a postoperative x-ray in figure 3. Time to union averaged 12.6 ± 4.1 weeks. (Range 6-20 weeks) Complication rate was 31.4%; wound infection in 14.3% (wound infection rate in closed fractures is 2.9% and 11.4% in open fractures) wound dehiscence with exposed

implants in 2.9%, mal-union with unstable ankle joint in 8.6% and non union in 5.7%. The functional outcomes using the Olerud and Molander⁶ scoring of symptoms after ankle fracture is shown in Table 1.

Discussion

Open reduction and internal fixation is the foremost treatment employed for displaced ankle fractures^{5,7}. Results are generally favourable with the majority of patients having a good functional outcome^{3,7}. Proponents of open reduction and internal fixation suggest that restoration of the normal anatomy will reduce the risk of subsequent osteoarthritis due to incongruity of the joint. Michelson et al⁸, however, have shown by using computerized tomography that the apparent displacement and external rotation of the distal fragments are actually due to internal rotation of the proximal part of the fibula.

Operative treatment for ankle fractures restores sufficient stability to allow full mobility at the ankle joint. Options of treatment include plate and screws or malleolar screws for the lateral malleolar fractures and tension band wiring or malleolar screws for the medial malleolar fractures depending on fracture configuration or bone stock. In the older patient, there are concerns about poor fixation, poor bone quality and impaired wound healing which makes some authors believe that open reduction and internal fixation carries an unacceptable risk especially in women^{5,9}. There is however, paucity of data on management of ankle fractures in our environment. Makwana et al^{3,9} compared 22 cases of ORIF and 21 cases of conservatively treated patients with ankle fractures and found that ORIF treatment yielded a significantly higher functional outcome score and a significantly better range of movement of the ankle.

Ponzer et al¹⁰ demonstrated satisfactory outcomes in 76%-83% of operatively treated type- B malleolar injuries. Although we did not compare the outcome of patients treated conservatively versus operatively, we were able to achieve 77.1% of good or excellent outcomes in our patients. This is presented in table 1. Miller¹¹ reported infections in 2.2% of 1841 patients after foot and ankle surgery while Butterworth et al¹² in a similar study found 3.1%. Our wound infection rate of 14.3% was rather high. This may be attributed to the inclusion of open fractures in our series which was responsible for a wound infection rate of 11.4%. Antibiotic coverage is usually based on the severity of the soft tissue injury and the grade of the open fracture although this does not completely obviate the risk of infectious complications¹³. The risk of infection after internal fixation of open or closed fractures can be decreased by the use of antimicrobial prophylaxis / therapy and proper surgical technique that includes proper soft tissue handling during placement of the implant¹⁴. Infection following foot and ankle surgery or trauma can range from commonly occurring superficial cellulitis to less common deep soft tissue or bone infections that can have disastrous consequences.

Infection is the most important factor in the development of non-union, loss of function and other complications after foot and ankle trauma and its prevention is essential to obtaining bony union and soft tissue coverage which ensures a functional plantigrade foot¹⁵. Patients who had wound infection in this study had more frequent wound dressing until healing while those with exposed implants were managed in-conjunction with plastic surgeons until wounds were healed and subsequently discharged from the hospital. Those with malunion and unstable ankle joints had their hardwares removed and arthrodesis of the ankle joint while those with non-union either had a repeat operative fixation with bone grafting or arthrodesis of the ankle joints.

Conclusion

Open reduction and internal fixation is a viable option in the treatment of ankle fractures in this environment in view of the high success rates. Early presentation, appropriate patient selection and good surgical techniques are required to achieve adequate post-operative functional outcome in these patients.

References

1. Anderson S, Li X, Franklin P, Wixted J. Ankle fractures in the elderly: Initial and Long-term outcomes. *Foot Ankle Int* 2008; 29(12): 1184-88.
2. Burwell HN, Charnley AD. The treatment of displaced fractures at the ankle by rigid internal fixation and early joint movement. *J Bone Joint Surg Br* 1965; 47-B: 634-60.
3. Makwana N, Bhowal B, Harper W, Hui A. Conservative versus operative treatment for displaced ankle fractures in patients over 55 years of age. *J Bone Joint Surg Br* 2001; 83: 525-29.
4. Michelson J. Fractures about the ankle. *J Bone Joint Surg Am* 1995; 77: 142-52.
5. Beauchamp CG, Clay NR, Thexton PW. Displaced ankle fractures in patients 50 years of age. *J Bone Joint Surg Br* 1983; 65: 329-32.
6. Olerud C, Molander H. A scoring scale for symptom evaluation after ankle fracture. *Arch Orthop Trauma Surg* 1984; 103: 190-94.
7. Egol K, Tejwani C, Walsh M, Capla E, Koval K. Predictors of short-term functional outcome following ankle fractures surgery. *J Bone Joint Surg Am* 2006; 88: 974-79.
8. Michelson J, Magid D, Ney D, Fishman E. Examination of the pathologic anatomy of ankle fractures. *J Trauma* 1992; 32:65-70.
9. Ahmad Hafiz Z, Nazri M, Azril M, Kassim N, Nordin N etal. Ankle fractures: The operative outcome. *Malaysian orthopaedic journal* 2011; 5(1): 40-43.
10. Ponzer S, Nsell H, Bergman B, Trnkvist H. Functional Outcome and Quality of Life in Patients with Type B Ankle Fractures: A Two-Year Follow-up Study. *J OrthopTrauma* 1999; 13(5): 363-68.
11. Miller W. Postoperative wound Infection in Foot and Ankle Surgery. *Foot Ankle* 1983; 4: 102-24.
12. Butterworth P, Gilheany F, Tinley P. Postoperative infection rates in foot and ankle surgery: a clinical audit of Australian podiatric surgeons, January to December 2007. *Australian Health Review* 2010; 34: 180-85.
13. Flynn J, Rodriguez-del Rio F, Piza P. Closed Ankle Fractures in the Diabetic Patient. *Foot Ankle Int* 2000; 21: 311-19.
14. Worlock P, Slack R, Harvey L, Mawhinney R. The prevention of infection in open fractures: An experimental study of the effect of fracture stability. *Injury* 1994; 25: 31-38.
15. Donley B, Philbin T, Tomford J, Sferra J. Foot and Ankle Infections after Surgery. *Clin Orthop Relat Res* 2001; 391: 162-70.