

## SPINE DEFORMITY SURGERY AT THE KENYATTA NATIONAL HOSPITAL: A ONE YEAR AUDIT

**A. Fazal**, MBBS, FCPS (Orth), Orthopaedic and Spine Surgeon, Firm II, Kenyatta National Hospital, P.O. Box 20723, Nairobi, Kenya. Email: akilfazal@gmail.com

### ABSTRACT

**Objective:** To evaluate the radiological and clinical outcome of surgical treatment of spinal deformity.

**Design:** Case series.

**Setting:** Kenyatta National Hospital between March 2012 and February 2013.

**Patients and Methods:** These cases were done as part of the spine project run at Kenyatta National Hospital which is held every quarter. All patients who underwent spine surgery during the four projects held during the study period were recruited into the study. Radiological outcome was assessed using Cobb angle measurement pre and post-operatively hence assessing percentage correction. All patients were followed for a minimum of two months and early complications recorded.

**Results:** A total of nine patients were recruited into the study. Eight were females and one was male. The average age at operation was 14.44 years. Seven patients had a diagnosis of adolescent idiopathic scoliosis and two had congenital scoliosis. The mean Cobb angle was 71.4° pre-operatively and 32.6° post-operatively representing a percentage correction of 54.3%. If you removed the two cases of congenital scoliosis, the mean correction of adolescent idiopathic scoliosis cases alone was 68.6%. The average operating time was 5.8 hours. There were two early complications; one superficial infection and one patient who suffered a foot drop.

**Conclusion:** In the correct indications, surgery for spine deformity surgery can be carried out safely with predictable outcomes.

**Key words:** MeSH database, Scoliosis, Adolescent, Idiopathic, Spine, Instrumentation, Congenital, Kenya

### INTRODUCTION

Scoliosis is the most common type of spinal deformity confronting orthopaedic surgeons. Its onset is usually insidious, its progression often relentless, and its end results may be deadly (1). Thus, timely recognition and treatment of idiopathic scoliosis is essential to optimize patient outcomes because effective ways exist to treat this condition.

Scoliosis is the presence of one or more lateral rotatory curves measuring  $>10^\circ$  of the spine as measured by the Cobb method in the coronal plane. Although defined as a side-to-side deformity, it is actually a three-dimensional rotational deformity. Many causes of scoliosis are known; however, 80% of cases are idiopathic. However we also see cases of congenital scoliosis at KNH.

According to age distribution, idiopathic scoliosis is described in three forms: infantile, juvenile, and adolescent (1). The adolescent form is seen between 10 years of age and maturity. This is the most common type of idiopathic scoliosis, accounting for 80% of all cases (1). The congenital variety is due to a failure of formation, a failure of segmentation, or a combination of both.

Scoliosis results in cosmetic deformity, disability, pain, and severe restriction of the patient's capacity to work. Cardiorespiratory compromise occurs in severe scoliosis (curves  $>60^\circ$ ) typically in the form of cor-pulmonale (1).

The magnitude of the curve is best determined by measurement of the Cobb angle, which is derived from a standard posteroanterior standing radiograph of the spine. Management for idiopathic scoliosis consists of observation, bracing and operative treatment. As per international guidelines, curves  $<25^\circ$  are observed. Those between  $25^\circ$  and  $40^\circ$  are braced and those above  $40^\circ$  undergo surgery (1).

Management of congenital scoliosis is mainly surgery as non-operative methods such as bracing have not been found to be very useful. Certain varieties such as incarcerated or non-segmented vertebrae however can be observed if there is no evidence of progression.

Surgical correction was revolutionized by Harrington in 1962 who introduced the first effective instrumentation system for scoliosis (1). For more than 30 years, use of the Harrington distraction rod, combined with a thorough posterior arthrodesis and immobilization in a cast or brace for 6 to 9 months, had been the standard surgical treatment for adolescent idiopathic scoliosis. Despite its success, the Harrington instrumentation system has several disadvantages including implant displacement, poor saggital contour and the need for post-op bracing.

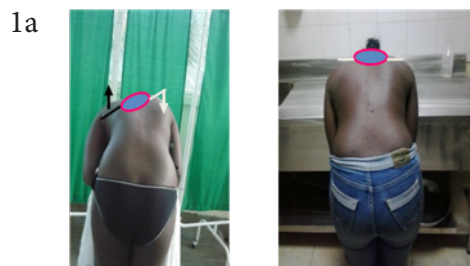These problems, paved the way for second generation implant systems which involved attaching sublaminar wires to the Harrington rods to help maintain lordosis as distraction is applied (1). In spite of these techniques, distraction across the lumbar spine inevitably lead to the loss of some degree of lumbar

lordosis, plus there was the added risk of neurological injury as the wires were inserted.

Third generation implants consists of instrumentation with Cotrel-Dubouset (CD) system. This construct uses segmental hooks reinforced with cross linked double rods. It has many advantages over first and second generation instrumentation, in that no post-operative bracing is required and correction is achieved in all three planes –frontal, saggital and horizontal (1). It also has a lower rate of implant failure and pseudarthrosis.

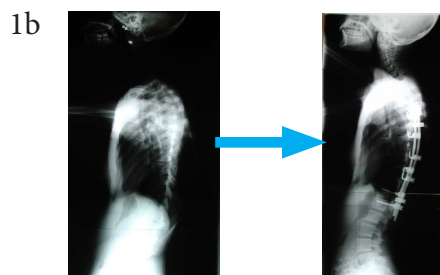
**Figure 1(a)**

*Horizontal plane correction*



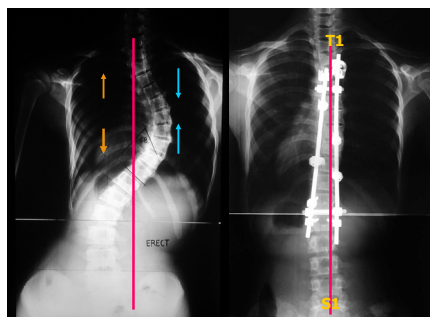
**Figure 1b**

*Saggital plane correction*



**Figure 1 (c)**

*Frontal plane correction*



The development of monoaxial and polyaxial pedical screws led to the development of fourth generation instrumentation which we have used in our patients (1). This is similar to the CD system but the screws used have an enormous pull out strength compared to standard hooks which makes the construct very strong (2).

The aim of this study was to assess the radiological and clinical outcome in terms of complications, of patients operated for adolescent

idiopathic and congenital scoliosis. Radiological outcome was determined by measurement of Cobb angle pre- and post-operatively to calculate percentage correction of deformity.

## MATERIALS AND METHODS

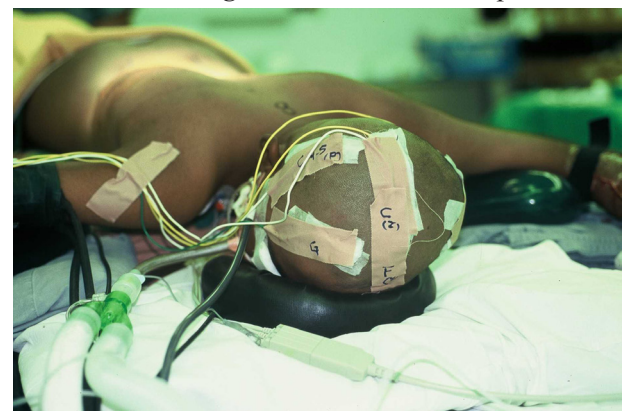This was a case series study of all patients with spine deformity who were operated upon within the spine project at the Kenyatta National Hospital between February 2012 and March 2013. The spine project is held four times a year and is sponsored by Nuvasive corporation from San Diego, USA. It consists of visiting surgeons from USA as well as local surgeons from Kenya. The aim of the project is to provide a platform for skills transfer amongst surgeons. Also, all implants for the project are provided to the patients free of charge.

Cases that had been operated for scoliosis during the spine projects were identified through the hospital in-patient database. Data collection and analysis was done by a single researcher (AF) who was part of the surgical team. Basic demographic data of all patients was retrieved from medical record files.

In every case, intra-operative monitoring in the form of Somatosensory Evoked Potentials (SSEP), Motor Evoked Potentials (MEP) and direct testing of screws was performed. This is necessary for continuous observation of spinal cord function, especially during screw insertion and manipulations when injury to the cord may occur. This was supplemented with Stagnara’s wake up test in some cases (2).

**Figure 2**

*Setup for intra-operative SSEP monitoring involves stimulating electrodes attached to the feet and recording electrodes on the scalp*



Upper instrumented level was the upper end vertebrae and lower instrumented level was the neutral vertebrae. We followed standard surgical technique consisting of exposure of spine from tip to tip of spinous process of upper and lowermost affected vertebrae. This is followed by facetectomy. Pedicle screws are then placed at each level, and a concave rod contoured to physiological kyphosis engaged and turned through 90°. This achieves saggital and horizontal plane correction. This is followed by sequential distraction on the concave side and compression on the convex side to correct frontal plane balance and therefore achieve a three dimensional correction. Less aggressive or no correction was attempted in the congenital scoliosis cases due to risk of neurological injury. In these cases, our primary aim was to carry out an in-situ fusion to prevent progression.

Bone graft was taken from the tips of the spinous processes of the vertebrae and supplemented by hydroxyapatite/calcium triphosphate (formagraft). This was placed around the instrumentation to facilitate fusion. In no patient was costoplasty or anterior release/fusion done.

Radiographic data was assessed by measuring Cobb angle on anteroposterior radiographs. The Cobb angle is the angle formed by a line drawn perpendicular to the upper vertebra upper end plate of the scoliotic curve and a similar perpendicular line drawn from the lower vertebra lower end plate.

Pre-operative Cobb angle was then compared to post-operative Cobb angle to calculate percentage change. In our service post-operative X-rays are normally done on the second or third post-op day when the patient has been mobilized.

## RESULTS

A total of nine patients with spine deformity were operated upon during the study period. Eight were female and one was male. The average age was 14.44 years. The mean follow-up was 3.6 months (range 2 months to 11 months).

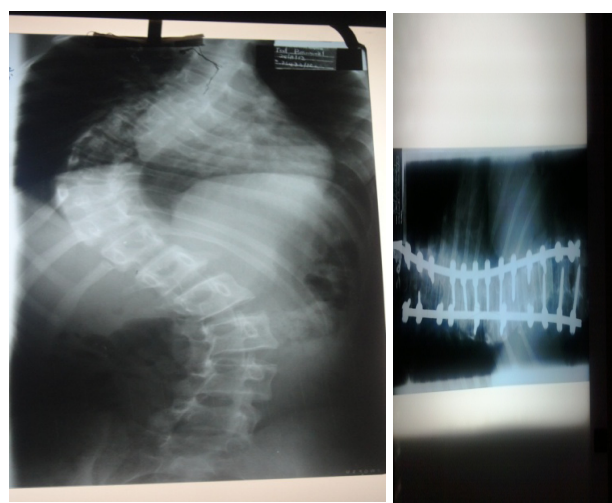
In seven patients, the diagnosis was adolescent idiopathic scoliosis. Two patients had congenital scoliosis which were due to a failure of formation. However on MRI neither patient had a cord anomaly such as diastomatelia, tethering or syrinx.

The average pre-operative Cobb angle was 71.4° and the average post-operative angle was 32.6°. This represents a percentage correction of 54.3%. However, when removing the two cases of congenital scoliosis little correction was attempted, the correction achieved improved to 68.6%.

Two early complications were noted. One of the AIS patients had superficial wound infection which resolved on antibiotics alone. One of the female patients who were operated for congenital scoliosis developed foot drop post-operatively. Imaging ruled out screw malposition. She has been managed conservatively and power has improved to 4/5 at L4-S1 at 6 months follow-up. She now walks with an AFO boot.

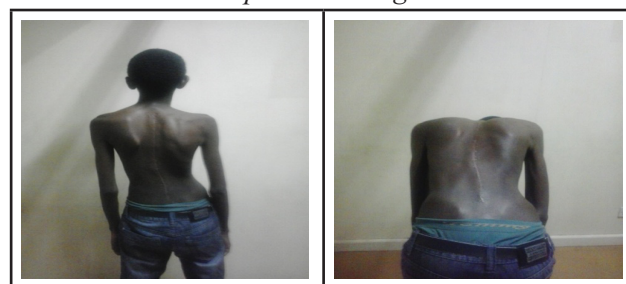**Figure 3**

*AP spine photographs of a scoliotic patient before and after surgery*



**Figure 4**

*Clinical photographs before and after surgery of the same patient as Figure 3*



## DISCUSSION

Fourth generation instrumentation and fusion for the correction of scoliosis has started being performed more commonly in Kenya. This is the first study of its kind in this country that has evaluated the outcome of this nature of surgical treatment in our population.

In the radiological outcome score, our percentage correction of 68.6% in the idiopathic group was at par with other studies on the same subject (3). This study however only looked at correction in the AP plane. Future studies should look at correction in other planes as well.

Challenges however remain in the establishment of a spine deformity service in this country. Cost of implants has been a major hurdle.

However prices are coming down, and projects such as the ones being done in cooperation with Nuvasive are helping. More investment however needs to be done on equipment, and training of local surgeons.

### **CONCLUSION**

Scoliosis surgery can be done safely and effectively in a developing country like Kenya. As more orthopaedic surgeons receive training and the cost of implants become affordable, it is hoped that more patients will benefit from scoliosis surgery in the future.

### **REFERENCES**

1. Webb, J., Burwell, R., Cole, A. and Lieberman I. Posterior instrumentation in scoliosis. *Eur. Spine J.* 1995; **4**(1): 2-5.
2. Owen, J. The application of intraoperative monitoring during surgery for spinal deformity. *Spine.* 1999; **24**(24):2649.
3. D'Andrea, L., Betz, R., Lenke, L. *et al.* Do radiographic parameters correlate with clinical outcomes in adolescent idiopathic scoliosis? *Spine.* 2000; **25**(14): 1795-1802.