

## TIBIALIZATION OF THE FIBULA IN A CHILD WITH CHRONIC OSTEOMYELITIS OF THE TIBIA: A CASE REPORT

**A. Fazal**, MBBS, MCPS, FCPS (Orth), Consultant Orthopaedic and Spine Surgeon, Kenyatta National Hospital, P. O. Box 20723 – 00202, Nairobi, Kenya, **J. C. Mwangi**, MBChB, MMed, Lecturer, Department of Orthopaedic Surgery, College of Health Sciences, University of Nairobi, **R. Kumar** MBBS, MS (Orth), Consultant Orthopaedic Surgeon, Kenyatta National Hospital and **D. Osilli**, MBChB, Registrar, Department of Surgery, College of Health Sciences, University of Nairobi, P. O. Box 19676 – 00202, Nairobi, Kenya

Correspondence to: Dr. A. Fazal, Department of Orthopaedic Surgery, Kenyatta National Hospital, P. O. Box 20723-00202, Nairobi, Kenya. Email: [akilfazal@gmail.com](mailto:akilfazal@gmail.com)

### ABSTRACT

**A case of a ten year old patient on treatment for chronic osteomyelitis of the right tibia is presented. After undergoing multiple sessions of debridement and sequestrectomy, first at a district hospital then at Kenyatta National Hospital, the patient ended up with a large bone defect of the tibia. After his infection was clinically cured, the options for surgical management of the tibial defect included: a through-knee disarticulation, segment transport with the help of a ring fixator and tibialization of the fibula.**

**Amputation was deemed too radical a procedure in a young patient especially now that the infection was cured. Segment transport would have been difficult considering that the bone defect involved almost 70% of bone length. Additionally, we were doubtful how compliant the patient would have been with distraction of the callus by fixator once discharged. We therefore employed tibialization of the fibula to treat this patient. This case discusses tibialization of the fibula as a viable option for management of large bone defects of the tibia.**

### INTRODUCTION

Management of chronic osteomyelitis remains a challenge to the orthopaedic surgeon particularly in the third world. Most cases of chronic osteomyelitis can be treated by surgical debridement and a prolonged course of antibiotics. Once in a while though, these cases result in large bone defects that threaten loss of limb in the patient; hence the need to look for alternatives that would cause lesser morbidity to the patient. Different surgical approaches have been published detailing how these bone defects can be bridged effectively (1-3).

Tibialization of the fibula has been successfully employed in the treatment of congenital dysplasia of the tibia (4). Shiha *et al* (5) medially transported the fibula using the Ilizarov device to manage two children with massive defects of the tibia and an associated active infection. A pedicled fibular flap has also been used in tibial reconstruction after resection of Ewing's sarcoma (6). A case report from Congo detailed how a 10-centimeter tibial bone loss was treated by inter-tibiofibula bone grafting, resulting in tibialization of the fibula. The patient was reviewed after 10 years;

and the clinical result was satisfactory and stable (7). This finding is similar to that of a study involving three young patients with severe tibial bone loss who underwent limb salvage surgery in which the fibula was tibialized. Long term follow-up of these patients showed complete tibialization of the fibula which replaced the bony gap (8).

### CASE REPORT

A ten year old Kenyan boy from Moyale (northern frontier of Kenya) was admitted to the Kenyatta National Hospital on 25<sup>th</sup> August 2011 with a complaint of pain and presence of a wound in the right leg persistent for two months prior to admission.

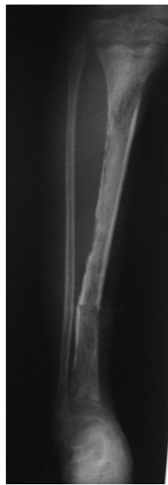He gave a history of trivial trauma to his right leg while at play. At that time he suffered pain and developed a wound that later on started discharging pus. About a month later his right tibia became exposed through the wound. He sought treatment at a local hospital in Moyale where he underwent initial debridement and sequestrectomy and was subsequently referred to Kenyatta National Hospital.

On examination he was afebrile and was not pale. Examination of the musculoskeletal system revealed a mild varus deformity of the right leg. The right tibia was exposed through an infected wound in the leg. This bone was fractured at that point of exposure. Distal neurovascular examination of his right leg was normal. Examination of his other systems was un-remarkable.

An impression of chronic osteomyelitis of the right tibia secondary to trauma was made. X-rays done confirmed this diagnosis with the presence of sequestra in the right tibia as illustrated in Figure 1.

**Figure 1**

*(a, b) X-ray right tibia AP on presentation*

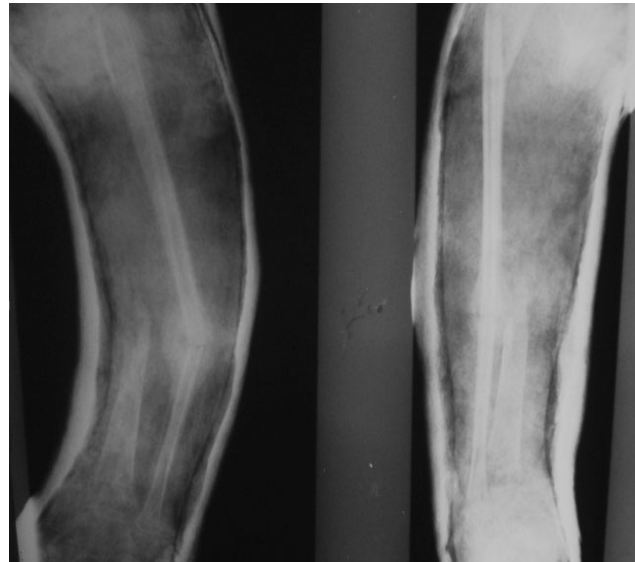


Other investigations done at our institution included a full hemogram and urea, electrolytes and creatinine. These showed values within normal ranges.

The patient was started on intravenous antibiotics (flucloxacillin 500mg QID) and sequestrectomy was done on two separate occasions resulting in a severe tibial bone loss. Culture specimens were negative for any bacterial growth. He subsequently had a fracture of his right fibula which was managed in a cast but still healed with a malunion (re-cavatum deformity) as illustrated in Figure 2 and 3.

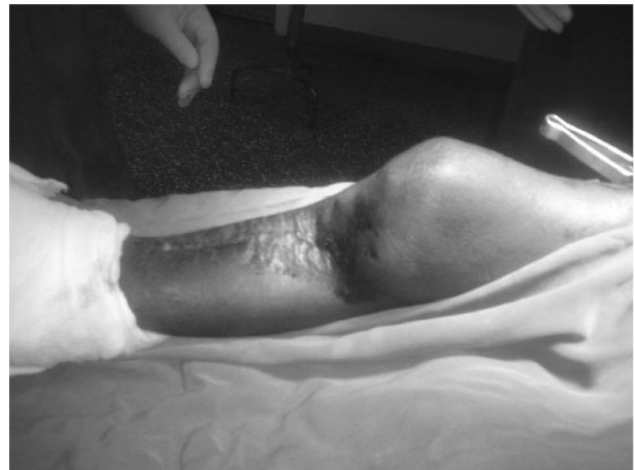**Figure 2**

*(a, b) x-ray right tibia AP and lateral after elimination of infection*



**Figure 3**

*Clinical picture of limb after elimination of infection*



A decision was then made to operate with surgical options available being: tibialization of the fibula, segment transport or a through-knee disarticulation. Tibialization of the fibula was the option chosen as it

gave us a chance to salvage his limb and did not need the long treatment and external fixator care associated with segment transport.

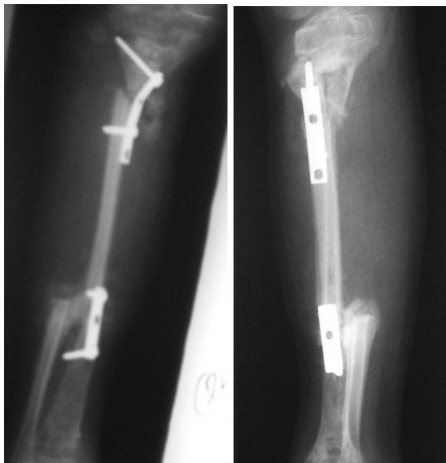Intra-operatively, the fibula was osteotomized at two places – just inferior to the fibula neck (after identification and mobilization of the common peroneal nerve) and at the junction between the middle and distal one-thirds.

These osteotomy sites coincided with the edges of the proximal and distal segments of tibia. This fibular segment was then approximated to the proximal and distal tibial segments and secured with the help of semi-tubular plates and screws (Figure 4 a,b). The fibula segment proximal to the osteotomy was found to be loose and was excised and used as bone graft. The fibula segment distal to the fibula osteotomy was left *in situ* so as to preserve the ankle syndesmosis. A Plaster of Paris backslab was then applied.

The patient remained stable post-operatively and X-rays done showed acceptable alignment between the tibia and fibula (Figure 5).

**Figure 4**

*(a, b) X-ray right tibia AP and lateral done post-operatively*



**Figure 5**

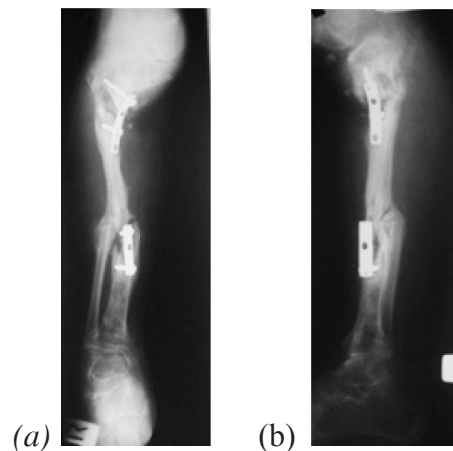
*Clinical picture of extremity showing good alignment and markedly reduced re-cavatum*



The patient did well post-operatively. He has remained infection free. The fibula has continued to remodel and increase in diameter (Figure 7 a,b).

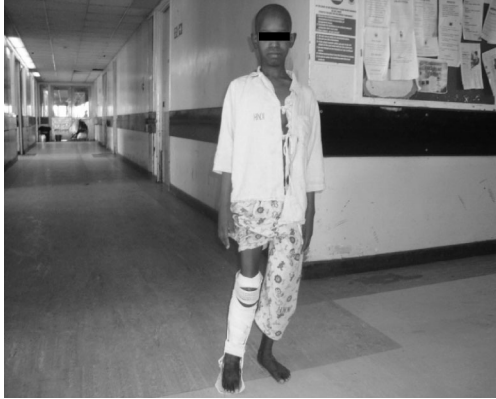**Figure 7**

*(a,b) : X-ray ( R ) tibia AP and Lateral, at 4 months showing satisfactory consolidation of transferred fibula*



**Figure 8**

*Patient at 4 months ambulating full weight bearing with the help of a splint*



## DISCUSSION

The management of chronic osteomyelitis is lengthy, very costly and may have a lasting impact on the independence and life quality of those affected (9-11). Clinicians should at all times aim at limiting the morbidity load of the patient in whatever course of management undertaken.

Limb salvage surgery when employed correctly, has shown to offer better functional outcome than amputation (12-14). Amputation is also associated with phantom limb pain which can be severe or incapacitating in 0.5 – 5% of all amputees (15, 16). The Ilizarov technique for segment transport is associated with many complications including: pin tract infection (17, 19), premature consolidation (18, 19), and nonunion (19).

Owing to its rich soft tissue coverage, the fibula can be used in limb salvage operations where defects of the tibia exist. Large defects of an infectious aetiology constitute a particularly challenging subgroup, and their management in adults appears to result in a less favorable outcome compared with that of management of uninfected defects (20). The operating team must therefore ensure complete elimination of infection in the tibia, before embarking on any reconstructive procedure.

Tibialization of the fibula was first described by Albert in 1877. He obtained fusion between the fibula and femur in a patient with congenital absence of the proximal tibia. Since then, the procedure has been employed successfully in many limb-salvaging operations (5, 21-23). This case illustrates its use in a severe case of tibia bone loss secondary to osteomyelitis. It is a cost effective technique that does not require any sophisticated instruments, and can be successfully performed in moderately equipped hospitals within Africa.

## ACKNOWLEDGEMENTS

The authors would like to thank the clinicians involved in the management of this patient and the administration of Kenyatta National Hospital for allowing us to publish this study.

## REFERENCES

1. Nast-Kolb, D. and Schweiberer, L. Treatment concepts in infected bone and soft-tissue defects. *Orthopaed.* 1994; **23**: 430-436.
2. Prochaska, V.J. and Lindgren, J.U. Treatment of chronic tibial osteomyelitis, segmental bone loss, and soft tissue defect by bone transplant. *Nebr. Med. J.* 1994; **79**: 349-352.
3. Evrard, J. Role of tibial-fibular grafting in the treatment of infected pseudoarthrosis of the tibia. *Rev. Chir. Orthop. Reparatrice Appar. Mot.* 1992; **78**: 389-398.
4. Nabil, K.M. and Ghaly, N.A. Surgical treatment of type 11 congenital dysplasia of the tibia. *Pan Arab J. Orthoped. Trauma.* 2004; **8**:129-134.
5. Shiha, A.E., Khalifa, A.R.H. and Assaghir, Y.M. Medial transport of the fibula using the Ilizarov device for reconstruction of a massive defect of the tibia in two children. *J. Bone Joint Surg. (Br).* 2008; **90**:1627-1630.
6. Oliviera, R.H. and Amarante, J.M. Ipsilateral pedicled fibular flap for tibial reconstruction after Ewing sarcoma resection. *Europ. J. Plastic Surg.* 2010; **34**:131-134.
7. Moyikoua, A. and Pena-Pitra, B. Tibialization of the fibula for a large bone loss. A case report. *Acta Orthop. Belg.* 2000; **66**(2):205-207.
8. Ofiram, E., Liebergall, M., Porat, S. *et al.* Tibialization of the fibula in the treatment of severe tibial bone loss. *Foot Ankle Surg.* 2002; **8**(3):191-195.
9. Toh, C.L. and Jupiter, J.B. The infected nonunion of the tibia. *Clin. Orthop.* 1995; **315**:176 -191.
10. Ueng, W.N. and Shih, C.H. Management of infected tibial plate osteosynthesis using a staging system for infected fractures. *J. Formos. Med. Assoc.* 1992; **91**: 531-537.
11. Hirschberg, J., Rees, R.S., Marchant, B. *et al.* Osteomyelitis related to pressure ulcers: the cost of neglect. *Adv. Skin Wound Care.* 2000; **13**:25-29.
12. Johansen, R., Nielsen, O.R. and Keller, J. Functional outcome in sarcomas treated with limb-salvage surgery or amputation. *Sarcoma.* 1998; **2**(1): 19-23.

13. Siegel, H.J., Patzakis, M.J., Holtom, P.D. *et al.* Limb salvage for chronic tibial osteomyelitis: an outcome study. *J. Trauma.* 2000; **48**(3):484-489.
14. Raewyn, C., Berry, M.G., Timothy, O. *et al.* Aggressive management of tibial osteomyelitis shows good functional outcomes. *ePlasty.* 2011; 11:e3
15. Melzack, R. and Loeser, J. Phantom body pain in paraplegics: Evidence for a 'central pattern generating mechanism' for pain. *Pain.* 1978; **4**:195-210.
16. Vassilis, M.M. Amputees and phantom limb pain: A literature review. *Physiotherapy Theory and Practice.* 1986; **2**(4):177-185.
17. Rose, R. Pin site care with the Ilizarov circular fixator. *The Internet J. Orthoped. Surg.* 2010; **16**(1) DOI: 10.5580/28c0.
18. Seung-Ju, K., Mandar, V.A., Sang-Heon, S. *et al.* Fibula-related complications during bilateral tibial lengthening: 60 patients followed for mean 5 years. *Acta Orthopaedica.* 2012; **83**(2):271-275.
19. Jean-Claude, T., Simpson, H. and Kenwright, J. Correction of complex lower limb deformities by the Ilizarov technique: An audit of complications. *J. Orthoped. Surg.* 2000; **8**(1):67-71.
20. DeBoer, H.H., Wood, M.B. and Hermans, J. Reconstruction of large skeletal defects by vascularized fibula transfer. Factors that influenced the outcome of union in 62 cases. *Int. Orthop.* 1990; **14**: 121-128.
21. Tuli, S.M. Tibialization of the fibula: A viable option to salvage limbs with extensive scarring and gap non-unions of the tibia. *Clin. Orthop. Relat. Res.* 2005; **431**:80-84.
22. Charalampos, G., Zalavras, F.D., Triche, R. *et al.* Reconstruction of large skeletal defects due to osteomyelitis with a vascularized fibular graft in children. *J. Bone Joint Surg.* 2007; **89**(10): 2233-2240.
23. Chacha, P.B., Ahmed, M. and Daruwalla, J.S. Vascular pedicle graft of the ipsilateral fibular for non-union of the tibia with a large defect. An experimental and clinical study. *J. Bone Joint Surg. (Br).* 1981; **63**(2): 244-253.