

## SPRENGELS SHOULDER AT THE KENYATTA NATIONAL HOSPITAL: A CASE REPORT

**H. O. Ong'ang'o**, MMed(Surg), MSc Ortho(London), FCS-ECSA, Consultant Orthopaedic and Trauma Surgeon, Orthopaedics Department, Kenyatta National Hospital, and Honorary Lecturer in Orthopaedics, Department of Orthopaedics, University of Nairobi and **P. Wabomba**, MMed (Surg), FRCS (Edin) Honorary Consultant Surgeon, Orthopaedics Department, Kenyatta National Hospital, P.O. Box 20723 - 00202, Nairobi, Kenya

Correspondence to: Dr. H. O. Ong'ang'o, P.O. Box 74037-00200, Nairobi, Kenya. E-mail: herbertongango@yahoo.com.

### ABSTRACT

**Sprengel's deformity is a rare complex congenital deformity of the shoulder girdle. It raises cosmetic concerns and occasions functional disability. Management is challenging at whatever age treatment is sought. Experience of surgeons is limited to one technical procedure and few cases of short-term follow-up. This study presents a male patient who presented at the Kenyatta National Hospital at the age of seventeen years and was managed by the Woodward's procedure**

### INTRODUCTION

Congenital elevation of the scapula is a complex congenital deformity of the shoulder girdle. Other names attributed to it include undescended scapula, elevated scapula, Congenital high scapula and congenital undescended scapula (1-19). Since 1891, Sprengel's deformity has become like a universal eponym for this condition. In this condition, the scapula, which arises as a cervical appendage, fails to migrate caudally to its normal position on the thorax during early development. Despite its rarity, it is considered the most frequently encountered congenital deformity of the shoulder girdle (4,8,17). The scapula is abnormally and permanently elevated (2), bilaterally in some instances. It is in addition small with a smaller vertical diameter and an apparently greater width. It is also usually adducted to some degree (3), with the lower pole medially rotated, causing the glenoid to face inferiorly (4). An omovertebral bone may be present joining the vertebral border of the scapula to one of the cervical vertebrae (4,8,15,17).

Elevation of the scapula almost always occurs sporadically, though combination with other congenital anomalies, such as failure of fusion in the midline of the laminae of some cervical vertebrae, cranium bifidum, and defects in the upper dorsal vertebrae; and with developmental anomalies of the thoracic outlet, such as cervical ribs and abnormal first thoracic ribs, hemivertebrae, congenital scoliosis, fusion of ribs and irregular vertebral segmentation is usual (1,4,8,9,15).

Also conditions like Klippel-Feil syndrome, kidney abnormalities, anal stenosis and cleft palate may coexist (4,6,15). It has been noted that these abnormalities may be more significant to the child's general health than the obvious scapula deformity (18). Developmental defects of the Shoulder musculature may exist. These may affect the trapezius, the rhomboids, the levator scapulae majorly, and the serratus anterior, pectoralis major, pectoralis minor, latissimus dorsi and the sternocleidomastoid to a minor extent (5,6,9,15).

The upward elevation of the scapula produces an asymmetry of the shoulder which is evident at birth and progresses with growth (2). There is also impairment of shoulder function, but it is the undesirable cosmetic appearance that forces the parents to seek medical attention for their child (1). More females are affected than males with a 3:1 ratio (4,6,9). At a later age, even if there is no functional impairment, the appearance of this deformity may be sufficiently objectionable to create psychological problems (3). Radiological evaluation of these patients mainly entails plain X-rays, though a scarcity of details especially of the omovertebral bone are obtained on 3D CT scan (4,5,10). MRI adds value when the omovertebral connection is cartilaginous or is just a fibrous band (5).

Despite having been first described in 1863 (2,5,8,15), it is only in 1972 that Cavendish (6) devised a classification for the Sprengel deformity. No surgical treatment is advised for Grade 1, while Surgery is advised for Grades 2 and 3 (2,6). Surgery is discouraged for severe Grade 4, as they are said to be unlikely to

derive any benefit (6). Many types of Surgical procedures have been developed and these include Schrock (1,2), Putti (2,6), Smith (2), Ober(2), Inclan (2), Koenig (1,2), McFarland (2), Chigot (2), Cabanac (2), Green (1,2,7), Petrie (11), Woodward (1,2,3,12,15), Modified Green (13,19), Modified Woodward (12,18), Allan's (6), Robinson and associates (2), among others. The results of most of these methods have, on the whole, been disappointing (6). The timing of the surgery is an aspect that has also seen no consensus, with most authors advocating the time between three and six years (1,3, 6, 8,12,16). On one extreme, Tachdjian (2) has proposed the surgery be carried out at the age of six months, whereas Borges *et al* (18) have advocated surgery even at seventeen years, an age condemned by other Surgeons (13). It is a considered point that outcome is not influenced by the age of the patient at the time of surgery, nor by the presence of an omovertebral bone (12). At the other extreme, Doita *et al* (14) have argued that surgical treatment of adult patients with Sprengel's deformity can produce good surgical results. Even then, Ross and Cruess (9), from their largest review of surgically treated patients, declared that it was not possible to determine an optimum age for surgery. The same conclusion was arrived at by Gonen *et al* (19).

Regardless of the technical procedure chosen nor the time at which it is undertaken, surgery for Sprengel's shoulder is a long, challenging and demanding undertaking requiring attention to small details (7). All surgeons seem to firmly stick to only one procedure (7, 8,13,18,19). Nevertheless the Green and Woodward procedures have appeared better than the others (8, 15, 16), though Grogan *et al* (8) and Carson *et al* (15) have declared the Woodward procedure to be the best surgical procedure available for the correction of congenital undescended scapula in children. Even then, the technique chosen is varied to meet the individual needs of the patient (7). Ahmad (17), has described a new procedure for correcting severe Sprengel deformity. Noted complications of surgical correction of Sprengel's deformity include unsightly keloid scars (3,9,13), Brachial plexus palsy (12) and scapula winging (9). Initial results of the surgical treatment were discouraging (3) but Ross and Cruess noted that it was possible to significantly improve the function of the shoulder and its position relative to the other side (9).

Because of its rarity, few surgeons have gained great experience with the condition, and published reports have usually involved a small number of cases, quite often all treated in like manner (7,8,9), and of short-term followup. Only Carson *et al* (15), Borges *et al* (18) and Gonen *et al* (19) have long-term follow-up series.

It is the purpose of this study to present a case of Sprengel's deformity that presented to the Kenyatta National Hospital at the age of seventeen years and was managed by the Woodward's procedure.

## CASE REPORT

A 17 year old male patient presented to the authors in 2006, with complaints of left shoulder pain and pain on breathing. Patient had an elevated left shoulder, noticed in childhood and at the time was experiencing limitation in Left shoulder function. Attention for this had been sought at the nearest Provincial General Hospital but no intervention had been offered.

The significant past medical history was that the patient was born with a cleft lip and palate which were repaired in childhood.

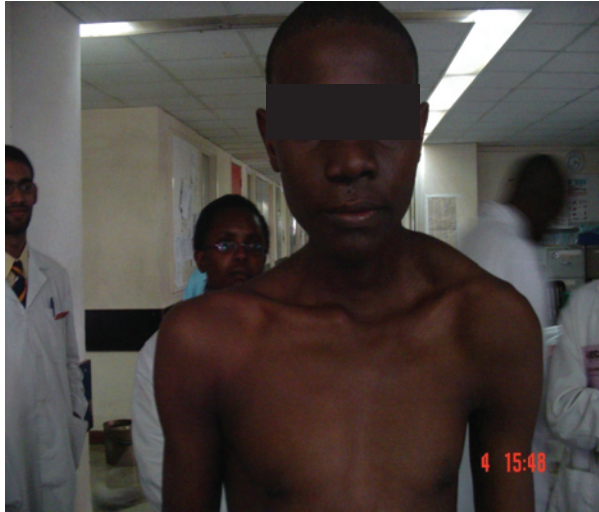Physical examination revealed an adolescent in fair general condition, with an evident cleft lip repair scar. There was a high left scapula that was fixed. There was limited elevation of the left shoulder, with gross atrophy of the supraspinatus and infraspinatus. There was apparent adduction of the left scapula on posterior inspection. The left clavicle appeared shortened and there was fullness in the supraclavicular fossa.

Plain X-ray examination revealed a fully bony omovertebral bone originating from the transverse process of C6 vertebrae and tethering the medial angle of the scapula, as well as an elevated medial portion of the supraspinous part of the scapula.

CT scans further confirmed the presence of the omovertebral bone. Patient was then prepared for surgery, and later on in 2006, a Woodward's procedure was performed on him. Immediate postoperative period was uneventful and patient was discharged after five days for outpatient physiotherapy and followup.

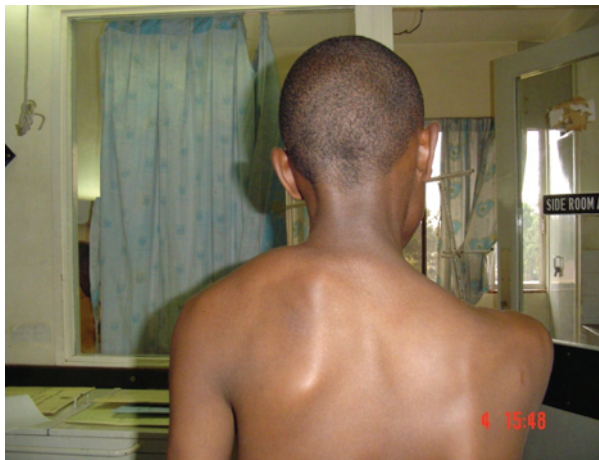**Figure 1**

Left Sprengel shoulder. Note shortened clavicle and left lip repair scar



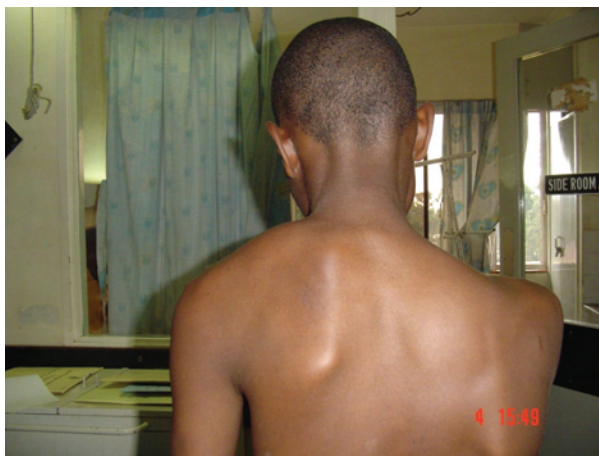**Figure 2**

Posterior view. Note supraspinous bone deformity and adduction of left scapula



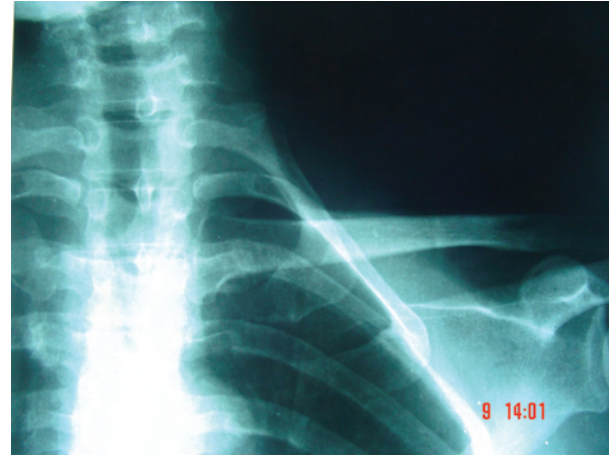
**Figure 3**

Note disparity in levels of lower poles of scapulae



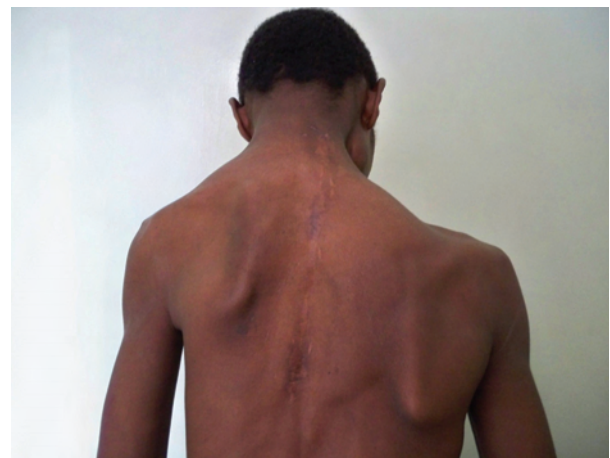**Figure 4**

X-ray. Note omovertebral bone and medial supraspinous bony deformity of scapula



**Figure 5**

Sprengel's shoulder 3 years' post operatively. No unsightly scar



## DISCUSSION

This case of Sprengel's shoulder posed unusual challenges. For a start it most likely is the second case report from the African continent after the report by Boon *et al* (4). We shared in the dilemma of Grogan *et al* (8) who found it difficult to specify criteria to define the optimal age for operative correction. Presenting at seventeen years of age, this was well above the average age of presentation and operation. Even though surgery for Sprengel deformity in adults has been performed (14), no series has short-term or long term follow-up results to guide our approach to this case, as this patient was very close to adulthood. Also being at an age where the soft tissues have lost their plasticity, the expected results of any surgical procedure would not

be marvelous. This case displayed associated congenital anomalies. The congenital cleft lip and palate that were repaired in childhood have been reported as associated before (4). The utilized modalities of investigating this case were plain X-rays and a 3D CT scan. The information obtained from these was deemed adequate for the treatment planning of this case. No new information would have been available by conducting an MRI examination. Muscle anomalies have been documented as part of the Sprengel deformity but no mention of the supraspinatus and infraspinatus atrophy noted in this case exists so far in the literature. The observed atrophy of the supraspinatus and infraspinatus would no doubt have a big role in determining the postoperative outcome and gains of surgery. The choice of the Woodward procedure as treatment for this case was arrived at by guidance from the literature as we had no prior experience with Sprengel's deformity. In line with the practice of other surgeons, we are likely to offer future patients the same basic procedure, with modifications as the experience enlightens us. What we are left wondering is why the shoulder deformity was not addressed in childhood at the time of the cleft lip and cleft palate repair. A similar scenario has been reported before from Japan (14). Had the Sprengel deformity been repaired in childhood it is possible the outcome would have been better then. Earlier in the postoperative period there were indications that the range of shoulder movement had improved. As of the last review, the patient did not have an unsightly scar but there still persisted a disparity of the levels of the scapulae.

## REFERENCES

- DePalma, Anthony F. Surgery of the shoulder. 3rd Edition. J.B. Lippincott. Philadelphia. 1983. pg 24-25.
- Tachdjian M.O. Congenital high scapula (Sprengel's Deformity). In: Tachdjian's Paediatric Orthopaedics. Vol 1. 2nd Edition. 1990. Philadelphia. WB Saunders. Pg 136-168.
- Woodward, J. W. Congenital elevation of the scapula. *J. Bone Joint Surg. AM.* 1961; **43A** (2): 219-228.
- Boon JM; Potgieter D; Van Jaarsveld Z *et al.* Congenital undescended scapula (Sprengel Deformity): A case study. *Clinical Anatomy.* 2002; **15**:139-142.
- Dilli, A Ayaz, U. Y., Damar, C., *et al.* Sprengel deformity: Magnetic resonance imaging findings in two pediatric cases. *Clinical Imaging Sci.* 2011; **1** (1):17-20.
- Cavendish, M. E. Congenital elevation of the scapula. *J. Bone Joint Surg. Br.* 1972; **54B** (3): 395-408.
- Green, W.T. The (Sprengel's deformity). *Bone Joint Surg AM.* 1957; **39A** (6):1439.
- Grogan, D.P., Stanely, E. A. and Bobechko, W. P. The congenital undescended scapula. *Bone Joint Surg. Br.* 1983; **65B** (5):598-605.
- Ross, D. M. and Cruess, R. L. The surgical correction of congenital elevation of the scapula. *Clinical Orthopaedics Related Res.* 1977; **125**:17-23.
- Cho, T., I. H., Chung, C. Y., *et al.* The Sprengel's deformity: Morphometric analysis using 3D-CT and its clinical relevance. *Bone Joint Surg. Br.* 2000; **82B** (5): 711-718.
- Petrie, J.G. Congenital elevation of the scapula. *Bone Joint Surg BR.* 1973; **55B**: 441.
- Le Saout, J. Congenital elevation of the scapula (Sprengel's deformity) In: Professor Jacques Duparc (ed) EFFORT Surgical Techniques in Orthopaedics and Traumatology. Elsevier 2003. Pg 55-210-C-10.
- Leibovic, S. J., Ehrlich, M. E. and Zaleske, D. J. Sprengel deformity. *Bone Joint Surg Am.* 1990; **72A** (2):192-197.
- Doita, M., Lio, H. and Mizuno, K. Surgical management of Sprengel's deformity in adults. *Clinical Orthopaedic Related Res.* 2000; **371**:119-124.
- Carson, W.G., Lovell, W. W. and Whitesides, T. E. Congenital elevation of the scapula. *Bone Joint Surg. AM.* 1981; **63A** (8):1199-1207.
- Siu, K. K., Ko, J. Y., Huang, C.C., *et al.* Woodward procedure improves shoulder function. In: Sprengel deformity. *Chang Guang Med.* 2011; **34** (4):403-408.
- Ahmad, A. A. Surgical correction of severe Sprengel deformity to allow greater postoperative range of shoulder abduction. *Pae Orthop* 2010; **30** (6): 575-581.
- Borges, J.L., Shah, A., Torre, B.C., *et al.* Modified Woodward procedure for Sprengel deformity of the shoulder: Long-term results. *J. Paed. Orthopaed.* 1996; **16**: 508-513.
- Gonen, E., Simsek, U., Solak, S., *et al.* Long-term results of modified green method in Sprengel's deformity. *J. Children Orthopaed.* 2010; **4**: 309-314.