

DIAGNOSTIC CORRELATION BETWEEN PLAIN RADIOGRAPHIC AND HISTOPATHOLOGY REPORTS AMONG PATIENTS WITH LONG BONES TUMOURS TREATED AT A TERTIARY HOSPITAL IN TANZANIA

A. H. Said, MD, MMed, Mnazi Mmoja Hospital-Zanzibar, **V.M. Lupondo**, MD, MMed, Department of Orthopaedic and Traumatology, Muhimbili University of Health and Allied Sciences, P.O. Box 65001, Dar es Salaam, Tanzania and Muhimbili Orthopaedic Institute, P.O. Box 65474, Dar es Salaam, **A.B. Hussein**, MD, MMed, Department of Orthopaedic and Traumatology, Muhimbili University of Health and Allied Sciences, P.O. Box 65001, Dar es Salaam, Tanzania, Muhimbili Orthopaedic Institute, P.O. Box 65474, Dar es Salaam, **M. Muhamedhussein**, MD, MMed, MSc PH, MBA, Department of Orthopaedic and Traumatology, Muhimbili University of Health and Allied Sciences, P.O. Box 65001, Dar es Salaam, Tanzania and Ebrahim Haji Charitable Health center, P.O. Box 14861, Dar es Salaam, Tanzania and **J.E. Olomi**, MD, MMed, Department of Orthopaedic and Traumatology, University of Dar es Salaam, P.O. Box 608, Mbeya and Orthopaedic Surgeon Mbeya Zonal Referral Hospital Tanzania

Correspondence to: Dr. Abdulmajid H. Said, P.O. Box 672 Zanzibar, Tanzania. Email: abdulmajidsaid90@gmail.com

ABSTRACT

Background: Bone tumours are significant global health concern, with a rising number of new cases being diagnosed each year. The incidence of bone tumours has shown a significant increase in recent years, as evidenced by a 50% rise in new cases in 2020 alone. Early and accurate diagnosis is crucial for effective treatment and improved patient outcomes. The diagnosis of primary bone tumours is based on clinical, radiological and histopathological findings.

Objective: This study aimed to determine the diagnostic correlation between plain radiographic and histopathological reports in diagnosing long bone tumours.

Methods: A cross-sectional study was conducted between 2018 and 2021. Participants who underwent a histological examination for long bone tumours and met the inclusion criteria were enrolled. Relevant information was obtained from patient records then sensitivity, specificity, and accuracy of the plain radiograph were calculated with histopathology serving as the gold standard.

Results: The study included 83 participants, the majority were aged 30 years old or younger. Forty six percent of the cases were malignant tumours while benign were 54%. Osteosarcoma was found to be the most common tumour type both by radiological and histological diagnosis and femur was the most commonly affected bone. Plain radiograph was found to have a sensitivity of 92.1%, specificity of 73.3% and accuracy of 82%.

Conclusion: This study found a strong diagnostic correlation between plain radiographic and histopathology reports in patients with long bone tumours. This suggests that plain radiography can serve as a useful screening tool for long bone tumours in resource-limited settings, allowing for early and accurate preliminary diagnoses.

Key words: Diagnostic correlation, Plain radiographic and histopathology reports, Long bones tumours

INTRODUCTION

Bone tumours are uncommon, accounting for only around 0.5% of all tumours. Primary bone tumours account for around 0.19% of all tumours in the USA (1). The incidence of bone tumours has shown a

significant increase in recent years, as evidenced by a 50% rise in new cases in 2020 alone (2). In Tanzania the prevalence of bone tumours is not known, however in a study conducted in North Tanzania the prevalence of long bone tumours was found at 56% of all musculoskeletal tumours (3).

A primary bone tumour is diagnosed using a triad combination of clinical, radiological, and histological markers (4). Despite advances in CT-scan and MRI, a plain radiograph is still beneficial for the first identification of bone tumours and correlates well with the final histology (3).

However, in resource-limited settings like Tanzania, the diagnosis still relies on clinical presentation and plain radiographs of which some are misinterpreted making the diagnosis inconclusive and limiting early diagnosis and treatment.

We found few studies in Africa and none in Tanzania on the diagnostic correlation between plain radiographs and histopathological diagnosis of primary bone tumours. Hence this study aimed to determine the diagnostic accuracy of plain radiographs in diagnosing bone tumours in comparison with histopathology.

MATERIALS AND METHODS

This cross-sectional study was conducted at the Muhimbili Orthopaedic Institute (MOI). Ethical clearance to conduct this research was sought from the Institutional Research Ethical review board of the Muhimbili University of Health and Allied Sciences (MUHAS). A permission letter to collect data was obtained from the MOI Director's office and Muhimbili National Hospital Directors office. Data obtained during the study was kept anonymous.

The study included all patients from MOI who had undergone histopathological examination between the years 2018 and 2021. All patients from MOI who had histopathology results of primary long bone tumours were included and exclusion criteria were:

- Participants who had missing plain radiograph images.
- Participants who had missing patients records i.e medical files.

The sample size was 83

Using Central Pathology Laboratory (CPL) registry book, all patients who had a long bone biopsy done between the years of 2018 and 2021 were gathered. This period was chosen because of the availability of X-ray images on the MOI database that dates

back to 2018. Names and dates on which the biopsy was taken, were used in obtaining the registration numbers from the MOI theatre registry book. All patients with incomplete data (missing plain radiograph images) were excluded from the study and convenient sampling was used to select a total of 90 participants who were included in the study.

Histology reports of all participants were obtained from Central Pathology Laboratory (CPL) records (these reports are written after an agreement among senior pathologists from a panel discussion), where medical files of the study participants, were obtained from the MOI medical records department.

Age, sex, residence, chief complaint, and duration of the complaint of all participants were recorded from the medical files obtained at MOI medical records, then histopathology diagnosis was obtained from histology reports of the sampled participants.

By using patients' registration numbers, plain radiographs of both the anteroposterior view and lateral view were traced and downloaded from the Clear Canvas software available in the MOI IT department and stored in a USB drive which was password protected.

A panel consisting of two senior radiologists was made and all downloaded plain radiograph images of each participant, together with their corresponding information obtained from medical files (age, sex, area of residence, chief complaints, and duration since onset) were taken to the radiologist. The panel was blinded to the histological diagnosis of the participants. The panel was requested to state whether the bone tumour is malignant or benign and also provide the final diagnosis after reaching a joint agreement (in case of differential diagnosis only the first diagnosis was taken) and in case of disagreement between the panelists this was regarded as inconclusive and was not used in subsequent analysis.

The data were loaded into a computer and analyzed by STATA statistical software version 15. For each variable, relevant frequencies and tables were provided. The diagnostic correlation between plain radiograph and histopathology was obtained by calculating using a measure of accuracy: sensitivity, specificity, and accuracy in a 2 by 2 table with histopathology as the gold standard (4).

RESULTS

The research involved a total of 83 individuals, with 58 (69.88%) being male and 25 (30.12%) being female. The age of participants ranged from 7 to 79 years, with a mean age of 27.9 years (standard deviation: 15.96 years). As indicated in Table 1, the majority of participants (68.67%) were aged 30 years or younger, while 20.48% were aged between 31 and 50 years, and 10.84% were aged 50 years or above.

Table 1

Socio-demographic characteristics of research participants (n=83)

Variable	Frequency	(%)
Sex		
Male	58	69.88
Female	25	30.12
Age group (years)		
≤30	57	68.67
31 - 50	17	20.48
>50	9	10.84

The study included 83 participants, and according to Figure 1, 45 of them (54%) had benign primary long bone tumours while 38 of them (46%) had malignant tumours as determined by histological analysis.

Figure 1

Histological diagnosis of primary bone tumours

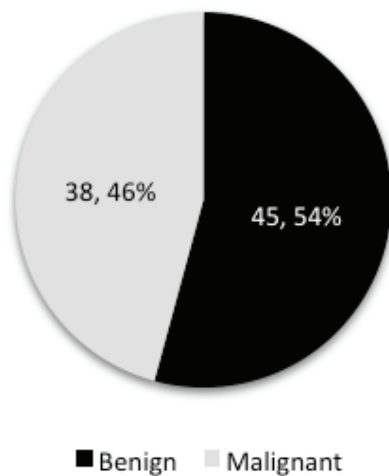


Table 2 above provides a summary of the radiological diagnoses of the cases included in the study. Out of all the bone tumours included in the study, 11 were diagnosed radiologically. Osteosarcoma was found to be the most frequently diagnosed tumour by plain radiography, accounting for 29 (34.94%) cases. This was followed by chondrosarcoma, which accounted for 11 (13.25%) cases. The least commonly diagnosed tumours were osteoid osteoma and multiple myeloma, each accounting for 2 (2.41%) cases.

Table 2

Summary of radiological diagnosis

Radiological diagnosis - benign	Frequency	(%)
Aneurysmal bone cyst	7	8.43
Fibrous dysplasia	9	10.84
Enchondroma	5	6.02
Giant cell tumour	6	7.23
Chondroblastoma	4	4.82
Osteochondroma	3	3.61
Osteoid osteoma	2	2.41
Radiological diagnosis - malignant		
Osteosarcoma	29	34.94
Chondrosarcoma	11	13.25
Ewing sarcoma	5	6.02
Multiple myeloma	2	2.41
Total	83	100

Table 3 presents the distribution of bone tumours according to histological diagnosis. A total of 13 different types of bone tumours were diagnosed, and osteosarcoma was found to be the most common type, accounting for 22 (26.51%) cases out of all cases. The second most common type was aneurysmal bone cyst, accounting for 9 (10.84%) cases. The least common types of tumours were ossifying fibroma, non-ossifying fibroma, chondroblastoma, and osteoid osteoma, with each of them accounting for 2 (2.41%) cases.

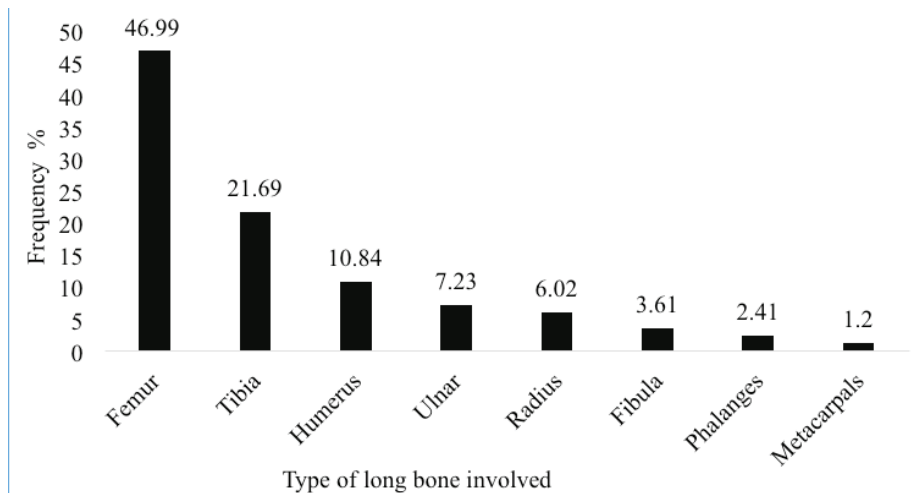
Table 3
Summary of histopathological diagnosis

Histological diagnosis - benign	Frequency	(%)
Aneurysmal bone cyst	9	10.84
Enchondroma	8	9.64
Giant cell tumour	8	9.64
Osteochondroma	8	9.64
Fibrous dysplasia	4	4.82
Chondroblastoma	2	2.41
Ossifying fibroma	2	2.41
Non-ossifying fibroma	2	2.41
Osteoid osteoma	2	2.41
Histological diagnosis - malignant		
Osteosarcoma	22	26.51
Chondrosarcoma	5	6.02
Ewing sarcoma	7	8.43
Multiple myeloma	4	4.82
Total	83	100

Among all bones, the femur was the bone that exhibited the highest incidence of bone tumours, accounting for 46.99% of cases. The remaining bones affected were ranked in descending order

of frequency, with the tibia accounting for 21.69%, humerus 10.84%, ulna 7.23%, radius 6.02%, fibula 3.61%, phalanges 2.41%, and metacarpals 1.2% (Figure 2).

Figure 2
Distribution of bone tumours in relation to different bones



The location of the long bone affected was analyzed, and it was found that the most common site was the proximal and distal metaphysis,

accounting for 33.73% and 32.53% respectively. The least common locations were the proximal and distal physis regions (Figure 3).

Figure 3

Anatomical site of bone lesion

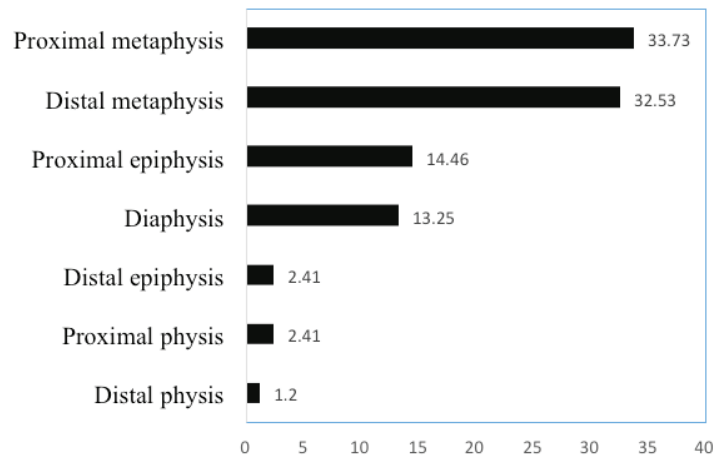


Table 4 is a 2 by 2 table that compares the number of cases diagnosed using plain radiography with the gold-standard histopathology diagnosis. The table shows that plain radiographs have a sensitivity of 92.1% in

detecting malignant tumours and a specificity of 73.3% in detecting benign tumours. Out of these, 47 cases have shown a consistent alignment between the radiological diagnosis and the histopathological diagnosis.

Table 4

Comparison of plain radiographical versus histopathological diagnosis of bone tumours

Plain radiographic diagnosis test	Histopathology diagnosis-gold standard		Sensitivity	Specificity	Accuracy
	Malignant (Positive)	Benign (Negative)			
Malignant (Positive)	35	12	92.1%	73.3%	82%
Benign (Negative)	3	33			
Total	38	45			

(Accuracy is from $35(TP)+33(TN)/83(TP+TN+FP+FN)$)

DISCUSSION

Social demographic and baseline characteristics

The study included a majority of male participants, with 69.88% males compared to 30.12% females. The age range of participants varied from 7 to 79 years, with a mean age of 27.9 years and a standard deviation of 15.96 years. Other studies particularly in Africa have reported similar findings (5–7).

Moreover, the age distribution of participants in this study indicated that individuals under the age of 30 years were the most commonly affected group, accounting for 68.67% of cases, followed

by those in the age range of 31 to 50 years (20%), and those above 50 years (10%). This result is in line with other studies conducted in Ethiopia and Zambia, which also reported a higher incidence of primary bone tumours in younger age groups (8,9).

The femur and tibia were the most frequently affected bones, with incidences of 46.9% and 21.69%, respectively. Additionally, the study found that the tumours mostly affected the proximal and distal regions of these bones. These findings were consistent with a study conducted in Zambia, which similarly reported the femur as the most commonly affected bone, followed by the tibia

(9). However, another research study showed that the most frequent anatomical locations were the distal femur at 33%, proximal tibia at 24%, and humerus at 7% (10). The reason for this occurrence can be attributed to several factors, including their size, weight-bearing function, rich blood supply, and high metabolic activity, which increase the likelihood of tumour growth.

Histopathological patterns

Benign and malignant primary bone tumours: We found benign lesions to be 54% of all cases a similar result like that in Nigeria where 53.7% of all the tumours were benign (11). This dominance of benign bone tumours over malignant bone tumours was also seen in Brazil (12).

A total of 13 different types of bone tumours were diagnosed histologically, with 9 types being benign and 4 being malignant. Osteosarcoma was found to be the most common malignant tumour, accounting for 57.8% of all malignant tumours. Similar trends have been reported in previous studies (4,6,8,9,13,14).

Thus, osteosarcoma being the most common malignant primary bone tumour, as supported by various studies can be explained by its peak incidence during adolescence, which corresponds to the period of rapid bone growth and high metabolic activity making it prone to mutations.

Among the benign tumours, Aneurysmal Bone Cysts (ABC), osteochondroma, enchondroma, and giant cell tumours were found to be the most common, as seen in previous studies other studies (13,14).

Sensitivity and specificity of plain radiograph in diagnosing benign and malignant long bone tumours

In resource-limited settings where sophisticated diagnostic tools such as CT scans and MRIs may not be widely available, plain radiographs remain a valuable tool for detecting and diagnosing certain types of tumours, including bone tumours. In these settings, plain radiography is often used as a screening tool, allowing healthcare providers to

make early accurate preliminary diagnoses or early referrals to those having malignant tumours.

Results findings in this study suggest that plain radiography has a high sensitivity (92.1%) for detecting malignant tumours, meaning that it correctly identifies a large proportion of patients who have malignant tumours. However, the specificity of plain radiography is somewhat lower (73.3%), indicating that there is a risk of false positives, where patients may be diagnosed with malignant tumours based on the radiograph even though they have benign conditions.

The high sensitivity of plain radiographs in detecting malignant tumours can be attributed to the fact that these tumours often result in changes to the bone structure, such as destruction, erosion, and periosteal reaction, which are easily identifiable on radiographs. Additionally, radiographs are widely available and easy to perform, making them a convenient and cost-effective screening tool, however, biopsy must also be done.

On the other hand, the lower specificity of plain radiographs in detecting benign tumours can be explained by the fact that many benign lesions can have imaging characteristics that are similar to malignant tumours. For example, some benign tumours may show cortical destruction or periosteal reaction, which are also features of malignant tumours. Therefore, it can be difficult to differentiate between benign and malignant lesions based solely on the radiographic appearance, and a biopsy may be necessary to make an accurate diagnosis.

The study's findings align with previous research conducted in Cape Town, which found that plain radiographs had a sensitivity ranging from 93% to 98% and a specificity ranging from 53% to 73% in diagnosing biopsy-proven bone malignancy (4).

Similarly, in a retrospective study on the correlation between the immunological and histological diagnosis of bone tumours, plain radiographs had a sensitivity of 92.9% and a specificity of 87.5% (12). Furthermore, in a study done in Kenya on assessing the sensitivity and specificity of plain radiography, the sensitivity was found to be 88.2% and the specificity was 86.7% (15).

Accuracy of plain radiograph in diagnosing primary bone tumours

The results of our study demonstrated that the diagnostic accuracy of plain radiographs was 82%, which is comparable to the diagnostic accuracy reported in a previous study conducted in Pakistan (86.95%) (16). However, another study conducted by Torres *et al.* (12) reported a higher diagnostic accuracy of 90%, suggesting that there may be variations in the accuracy of plain radiographs in detecting primary bone tumours.

The variations in diagnostic accuracy of plain radiographs in detecting primary bone tumours may be due to several factors. One potential factor is the quality of the radiographs themselves. Poor-quality radiographs may not provide clear enough images to identify tumours, leading to a lower accuracy rate. Additionally, differences in imaging techniques, such as the positioning of the patient, can also influence the accuracy of the radiographs. These differences in techniques may have varying sensitivity and specificity in detecting bone tumours, leading to different accuracy rates.

CONCLUSION

The findings of this study show a strong diagnostic correlation between plain radiographic and histopathology reports in patients with long bone tumours treated at MOI. The high sensitivity specificity and diagnostic accuracy of plain radiography in detecting both benign and malignant tumours, particularly in resource-limited settings where more sophisticated diagnostic tools may not be widely available, highlights the importance of this diagnostic modality in the management of bone tumours.

Overall, this study underscores the value of plain radiography in diagnosing long bone tumours and emphasizes its potential as a cost-effective and widely available diagnostic tool in resource-limited settings allowing healthcare providers to make early and accurate preliminary diagnoses or referrals.

Conflict on interest: None to declare.

ACKNOWLEDGMENT

We would like to acknowledge Dr Respicious Boniface, Prof Abel Makubi, Dr Anthony Assey, Dr Joseph Mwanga, Prof Billy Haonga and the Muhimbili Orthopaedic Institute for the support and permission to conduct this study.

REFERENCES

1. Ghert, M., Mwita, W. and Mandari, F.N. Primary bone tumors in children and adolescents treated at a referral center in Northern Tanzania. *JAAOS Glob Res Rev.* 2019; **3**(3):e045.
2. Vemuri, N.V., Songa, R., Azzopardi, C., Thaker, S., Gupta, H. and Botchu, R. Bone tumors management survey in India – Radiologist perspective. *Indian J Musculoskelet Radiol.* 2020; **2**(2):108–114.
3. Costelloe, C.M. and Madewell, J.E. Radiography in the initial diagnosis of primary bone tumors. *Am J Roentgenol.* 2013; **200**(1):3–7.
4. Gerber, E., Said-Hartley, Q., Gamielien, R., Hartley, T. and Candy, S. Accuracy of plain radiographs in diagnosing biopsy-proven malignant bone lesions. *South Afr J Radiol.* 2019; **23**(1):1–7.
5. Aina, O.J., Adelusola, K.A., Orimolade, A.E. and Akinmade, A. Histopathological pattern of primary bone tumours and tumour-like lesions in Ile-Ife, Nigeria. *Pan Afr Med J.* 2018; **29**:1–9.
6. Oyemade, G.A.A. and Abioye, A.A. Primary malignant tumors of bone: Incidence in Ibadan, Nigeria. *J Natl Med Assoc.* 1982; **74**(1):65–68.
7. Paul, E.J., Zacharie, S., Adrian, H., André, M., Bruno, D.D. and Roger, A.G. Primary malignant bone tumors in Cameroon. *Epidemiol Histopath Data.* 2020; **1857**(7): 163-169.
8. Negash, B.E., Admasie, D., Wamisho, B.L. and Tinsay, M.W. Bone tumors at Addis Ababa University, Ethiopia: Agreement between radiological and histopathological diagnoses, a -5-year analysis at Black-Lion Teaching Hospital. *Int J Med Med Sci.* 2009; **1**(4):119–125.

9. Sakala, D., Munthali, J.C. and Mulla, Y. Primary malignant bone tumours at the University Teaching Hospital in Lusaka Zambia. *Med J Zambia*. 2016; **43**(1):24–30.
10. Mbchb, P. and Sa, F.C.O. Primary malignant bone tumours: Epidemiological data from an Orthopaedic Oncology Unit in South Africa. *SA Orthop J*. 2016; **15**(4):12–16.
11. Obalum, D.C., Giwa, S.O., Banjo, A.F. and Akinsulire, A.T. Primary bone tumours in a tertiary hospital in Nigeria: 25 year review. *Niger J Clin Pract*. 2009; **12**(2):169–172.
12. Torres, J., Sousa, A., Leite, M. and Salazar, C. Correlación entre el diagnóstico imagenológico e histológico de tumores óseos. Un estudio retrospectivo. *Acta Ortopédica Mex*. 2019; **33**(6):386–390.
13. Lasebikan, O.A., Nwadinigwe, C.U. and Onyegbule, E.C. Pattern of bone tumours seen in a regional orthopaedic hospital in Nigeria. *Niger J Med J Natl Assoc Resid Dr Niger*. 2014; **23**(1):46–50.
14. Aina, O.J., Adelusola, K.A., Orimolade, A.E. and Akinmade, A. Histopathological pattern of primary bone tumours and tumour-like lesions in Ile-Ife, Nigeria. *Pan Afr Med J*. 2018; **29**:1–9.
15. Kiplagat, N.J. Comparison between radiographic and histopathological diagnosis of primary bone tumors at Moi teaching and referral hospital. Moi University; 2019.
16. Azad, H., Ahmed, A., Zafar, I., Bhutta, M.R., Rabbani, M.A. and KC, H.R. X-ray and MRI correlation of bone tumors using histopathology as gold standard. *Cureus*. 2022; **14**(7):1-9.