

PROXIMAL FEMORAL BONE MORPHOLOGICAL MEASUREMENTS: RELEVANCE IN ORTHOPAEDIC AND FORENSIC MEDICINE

O.I. Akinmokun. MBBS, FWACS, FMCOrtho, Department of Surgery, College of Medicine, University of Lagos, Idi-Araba, Nigeria and Department of Orthopaedics, Lagos University Teaching Hospital, Idi-Araba
N.M. Ibeabuchi. MBBS, MSc, PhD, MPA, Department of Anatomy, College of Medicine, University of Lagos, Idi-Araba, Nigeria, **I.A. Oyebiyi,** MBBS, MWACS, Department of Orthopaedics, Lagos University Teaching Hospital, Idi-Araba, Nigeria, **O.A. Akinde, I.S. Hussein, O.O. Thomas** and **S.A. Duro-Emmanuel,** Medical Students, College of Medicine, University of Lagos, Idi-Araba, Nigeria

Correspondence to: Dr. O.I. Akinmokun, Orthopaedic Unit, Department of Surgery, College of Medicine, University of Lagos, Idi-Araba, Nigeria. Email: israelakinmokun@gmail.com; oakinmokun@unilag.edu.ng.

ABSTRACT

Background: Numerous surgical procedures are performed on and around the proximal femur to restore the anatomy and maintain the function of the limb. Hip joint prostheses and surgical implants that are usually used for these procedures were manufactured using dimensions from other populations.

Objective: This study documented the anatomic dimensions of proximal femur of Nigerians, devised various equations through regression analysis for pre-operative estimation of certain parts of the proximal femur and for use in forensic medicine. This study also correlated the dimensions of the proximal femur with different surgical implants available.

Methods: A total of 56 adult dry femoral bones were studied. Parameters measured were Maximum Femoral Length (MFL), length of the femur between the tip of the greater trochanter and the lateral condyle (termed Trochanteric Length (TL) of the femur), Femoral Neck Length (FNL), Femoral Neck Diameter (FND), Femoral Neck Axial Length (FNAL), Femoral Neck Shaft Angle (FNSA) and Proximal Femoral Shaft Diameter (PFSD). The monographs of surgical implants were obtained. Analyses were done with Microsoft excel 2010 (Microsoft Corporation, Redmond, Washington, United States) and STATA version 13 (StataCorp, Texas, USA). Statistical significance was set at $p \leq 0.05$.

Results: The average measured values of the parameters were: MFL was 47.9cm, TL was 45.8cm, FNL was 22.9mm, FNAL was 96.9mm, FND was 30.3mm, PFSD was 28.4mm and FNSA was 130.8°. Regression analysis revealed significant statistical relationship between the lengths of femur and other parameters measured; with equations that can be used in clinical settings to estimate certain parameters:

$MFL = 2.5 + TL$; range ± 1 cm. $FND = 6 + 0.05*TL(mm)$; range ± 5 mm; $FNAL = 5 + 0.206*TL(mm)$; range ± 15 mm. TL was used in the equations because it can be measured easily in clinical settings. In forensic medicine, MFL can be estimated from the FND and FNAL, using the equations: $MFL = 30.5 + 0.18*FNAL$ and $MFL = 42.14 + 0.19*FND$.

Conclusion: This study has provided data of the dimensions of proximal femur in Nigerians. Various equations generated from this study will be useful in pre-operative planning, clinical settings and forensic medicines.

Key words: Femur, Proximal, Fracture, Fixation, Pre-operative, Orthopaedic, Forensic, Length, Measurement, Anthropometry

INTRODUCTION

The proximal femur includes the femoral head, femoral neck, the greater and lesser trochanters, the intertrochanteric region and it extends to 5 centimeters below the lesser trochanter (1). Numerous surgical procedures are performed

on and around the proximal femur as indicated by various causes. Total hip replacement and hemiarthroplasty are two common joint procedures that are performed whenever indicated, to restore painless functions of the hip joint. Fracture fixations with implants are usually performed following either traumatic,

pathologic or fragility fractures. This is done to restore the anatomy of the proximal femur which will help in the optimal function of the hip joint and the limb. Corrective osteotomies remain vital surgical procedures in the armamentarium of the orthopaedic surgeons, as these procedures are used to correct deformities, reshape the bone and to redirect the load trajectories appropriately (2). Hip joint prostheses and surgical implants, in various forms, such as plates, various types of screws and proximal intramedullary nails are utilized during these aforementioned procedures. However, the available surgical implants and prostheses being used in our environment were manufactured using bony dimensions from other populations. It has been documented that dimensions of bones differ from one geographical location to another and between racial groups (3-5). Surgical implants made using dimensions from another geographical location may not fit another population in another geographical region. In a study done amongst Egyptians, 35 patients had their intertrochanteric fractures surgically fixed with Dynamic Hip Screws (DHS) surgical implants. It was documented that the application of the surgical implants changed the dimensions of the proximal femur after surgery. Although majority of the changes in the dimensions were not statistically significant, it was reported that the application of the DHS changed the mean Neck Shaft Angles (NSA) on the operated sides to 136.5° as compared to the mean of 125.5° on the sides not operated (6). Normally, neck shaft angles are usually similar on both sides (7,8). The difference in the mean NSA of both sides can be attributed to the application of 135° barrel DHS plates for fracture fixations of the intertrochanteric fractures, thereby causing the increase of the NSA on the operated sides. The average femoral axial length was also reduced on the operated sides (the uninjured sides has an average values of 72.8mm while the operated sides with DHS recorded a mean of 70.2mm) (6). In another study by Muller *et al* (9), significant statistical changes were noted between the pre-operative and post-operative mean neck shaft angles from 128° (range 119° to 147°) to 131° (range 127° to 136°), mean anteversion angle from 24.9° (range 7.9° to 39.1°) to 7.4° (-11.6° to 25.9°) and mean femoral offset from 39.7mm to 41.7mm) after conventional total hip arthroplasty with prostheses of fixed neck shaft angles of 131° . It is pertinent for orthopaedic surgeons to be aware of the anatomical dimensions of the populace where their practices are located and to do proper pre-operative planning to decide appropriate implants to be used for the surgery. It is equally important

for the implants manufacturers to produce and provide implants of different dimensions that would be appropriate for a particular region.

This study documented the anatomic dimensions of proximal femur of Nigerians. It also devised various equations through regression analysis that can be used to estimate certain dimensions as part of pre-operative planning and for use in forensic medicine. This study also correlated the dimensions of the proximal femur with different surgical implants available.

MATERIALS AND METHODS

Ethical approval was obtained from the Hospitals' Ethics and Research Committee before the commencement of the study. Dry femoral bones measured were from the Department of Anatomy, College of Medicine, University of Lagos. A total of 61 femoral bones were retrieved but five were deformed and distorted and were therefore, excluded from the study. The remaining 56 non-sexed, non-paired, adult dry femoral bones were sorted into laterality resulting in 27 right and 29 left femoral bones. Each of the bone was given an alphanumeric identity and labeled. The femoral bones with right laterality were labeled from R1 to R27 while those of the left laterality were labeled L1 to L29. The dimensions measured were:

- a) *Maximum Femur Length (MFL)*: The distance between the highest point of femur head to the lowest point of the medial condyle (Figure 1)
- b) *Femoral Trochanteric Length (TL)*: The distance between the tip of the greater trochanter of femur to the lowest point of the lateral condyle (Figure 2)
- c) *Femoral Neck Length (FNL)*: The anterior distance between the base of femoral head and inter-trochanteric line (Figure 3)
- d) *Femoral Neck Diameter (FND)*: The breadth of neck of femur in vertical axis in its narrowest part (Figure 4)
- e) *Femoral Neck Axis Length (FNAL)*: The distance between the tip of head of femur through the midpoint of the femoral neck to the base of the lateral part of the greater trochanter (Figure 5)
- f) *Proximal Femoral Shaft Diameter (PFSD)*: The coronal diameter of the femoral shaft, measured 3cm below the lesser trochanter
- g) *Femoral Neck Shaft Angle (FNSA)*: The angle formed between the long axis of femoral head and neck (line joining the center of head of femur and the midpoint of neck diameter) and long axis of shaft (vertical line joining

the midpoint of the diameter of the femoral shaft at two different points separated by 5cm below the lesser trochanter (Figure 6).

Figure 1

Measurement of Maximum Femoral Length (MFL)



Figure 2

Measurement of Trochanteric Length (TL)



Figure 3

Measurement of anterior Femoral Neck Length (FNL)

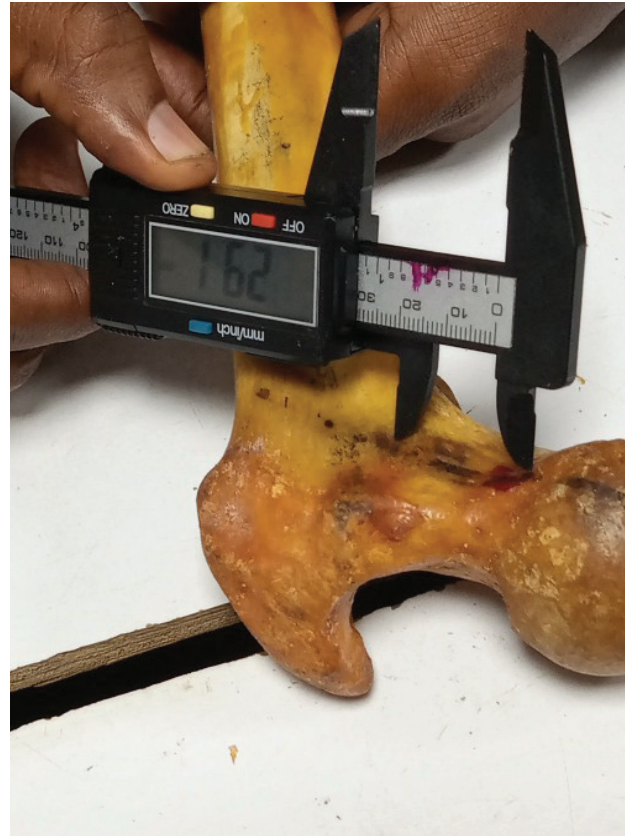

Figure 4

Measurement of Femoral Neck Diameter (FND)



Figure 5

Measurement of Femoral Neck Axial Length (FNAL)



Figure 6

Measurement of Femoral Neck Shaft Angle (FNSA)



The Maximum length of the femur (MFL) and the Trochanteric length of the femur (TL) were measured using the osteometric board. All other measurements were done using digital vernier

calipers except the Femoral Neck Shaft Angle (FNSA) that was measured with Goniometer. All measurements were done twice, and average values recorded. The monographs of surgical implants were obtained to document the dimensions of the implants. The femoral neck volume and volumes of the screws/implants were calculated using:

$$\text{Volume} = \pi (d/2)^2 h$$

Analyses were done with Microsoft excel 2010 (Microsoft Corporation, Redmond, Washington, United States) and STATA version 13 (StataCorp, Texas, USA). Mean and standard deviation were documented. Chi square and regression analysis were done for associations. Scatter plots generated. Statistical significance was set at $p \leq 0.05$.

RESULTS

Fifty- six dry femoral bones, comprising of 27 of right laterality and 29 of left laterality, were analysed. Table 1 shows a summary of the measured parameters. There were no significant differences between the dimensions of the left sided and right sided proximal femur specimens. Table 2 shows a comparison of the measured dimensions with measurements from other populations. Thirty six percent of the FNSA were between 130° and 134° , while 19% had FNSA between 125° and 129° (Figure 7).

Figure 7

Femoral neck shaft angle distribution

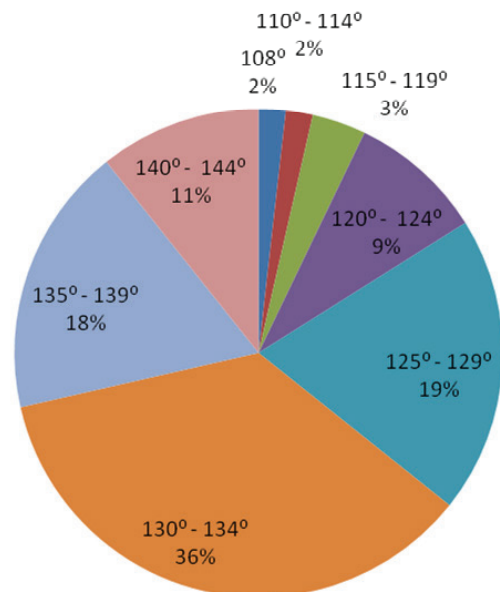


Table 1*Measured parameters*

Parameter	Right	Range	Left	Range	Average	Range	P-value
MFL (cm)	47.8 ± 2.2	42.0 – 51.4	48.0 ± 2.0	42.1 – 51.2	47.9 ± 2.1	42.0 – 51.4	0.8569
TL (cm)	46.0 ± 2.1	41.1 – 50.0	45.5 ± 1.9	40.2 – 48.5	45.8 ± 2.0	40.2 – 50.0	0.7701
FNL (mm)	21.6 ± 3.1	17.2 – 30.9	24.2 ± 4.1	16.6 – 32.4	22.9 ± 3.9	16.6 – 32.4	0.8721
FNAL (mm)	98.7 ± 7.3	82.5 – 110.8	95.3 ± 6.0	81.9 – 108	96.9 ± 6.9	81.9 – 110.8	0.8198
FND (mm)	31.7 ± 2.7	22.5 – 35.9	28.9 ± 2.6	23.1 – 33.7	30.3 ± 2.9	22.5 – 35.9	0.5445
PFSD (mm)	28.4 ± 2.1	23.3 – 32.3	28.3 ± 2.1	23.9 – 34.0	28.4 ± 2.1	23.3 – 34.0	0.8994
NSA (°)	130.6 ± 8.4	108 – 144	130.9 ± 6.3	112–140	130.8 ± 7.3	108 – 144	0.6539

Table 2*Comparison of measured parameters with values from other racial groups*

Authors	Ethnicity	Type of study	MFL(cm)	FNL(mm)	FNAL (mm)	FND(mm)	FNSA(°)
Isaac <i>et al</i> (13)	Indians	Dry bones	43.47± 2.78	28.4± 4.5	–	-	126.7
Mukhia <i>et al</i> (14)	Nepalese	Dry bones	42.0 ± 2.81	41.2± 3.2	–	29.4±3.0	127.1
Baharuddin <i>et al</i> (20)Malay	Radiograph (Male)	91.08 ± 5.65	28.88 ± 3.38	132.33			
	Radiograph (Female)	81.78 ± 4.33	25.95 ± 4.31	129.87			
Hoaglund <i>et al</i> (3)	Caucasians	Dry bones (Male)	45.1	–	-	33	136
	Caucasians	Dry bones (Female)	43.7	-	-	30	133
	Chinese	Dry bones (Male)	43.0	-	-	31	135
	Chinese	Dry bones (Female)	39.0	-	-	27	134
de Farias <i>et al</i> (15)	Brazilians	Radiograph	36.54	108.42	37.48	130.47	
Pires <i>et al</i> (16)	Brazilians	Radiograph	35.7	113.4	36.6	129.2	
Ravichandran <i>et al</i> (18)	Indians	Dry bones	31.9	31	126.55		
Lakati <i>et al</i> (19)	Kenyans	Dry bones	29.36	129.03			
Present study	Nigerians	Dry bones	47.9	22.9	96.9	30.3	130.8

Figure 8

Scatter plot showing the relationship between MFL and TL

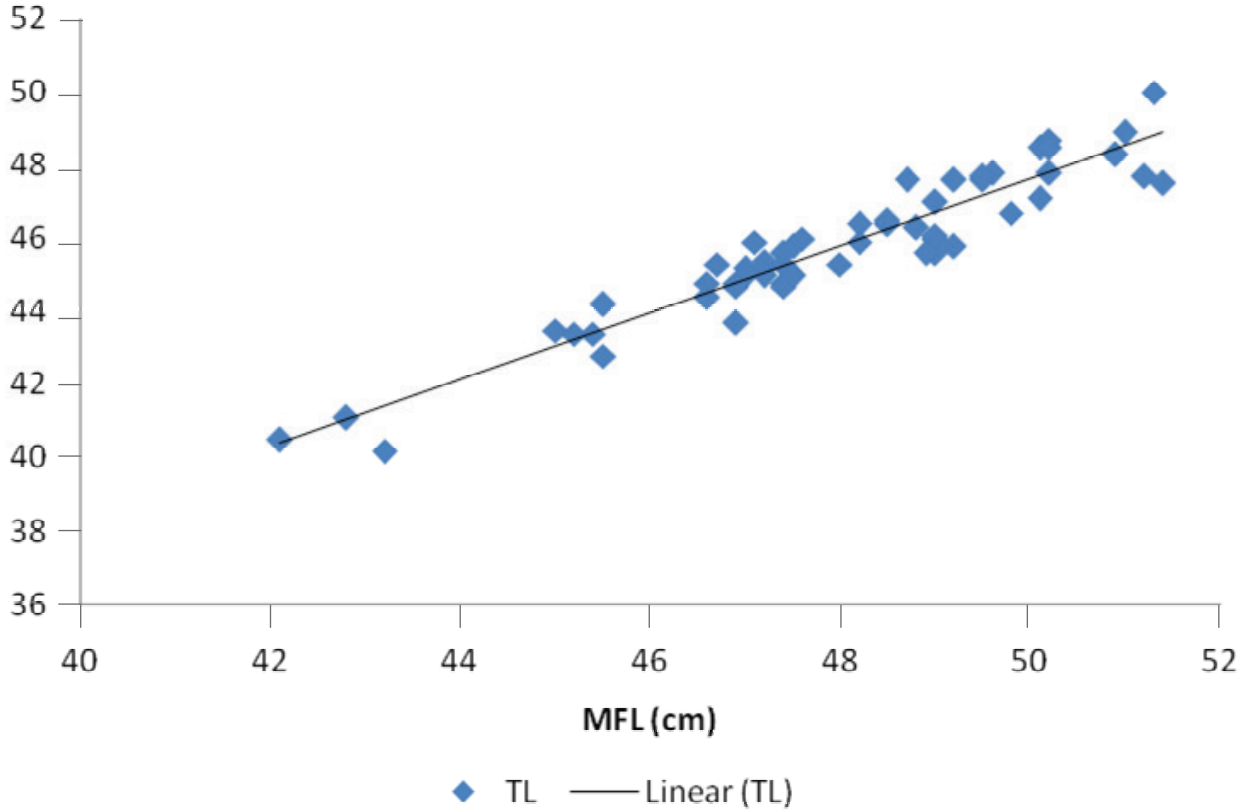


Figure 9

Scatter plot showing the relationship between MFL, FNAL, FND and FNSA

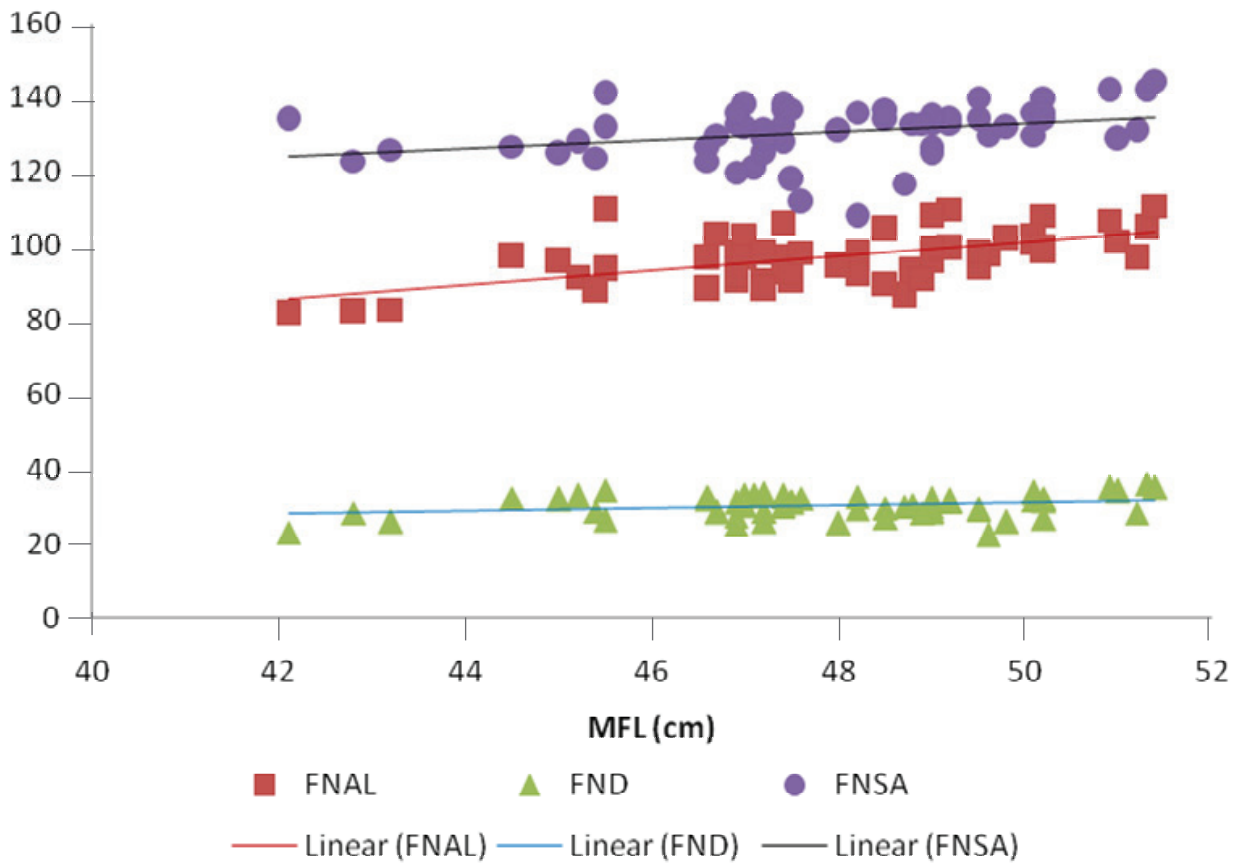
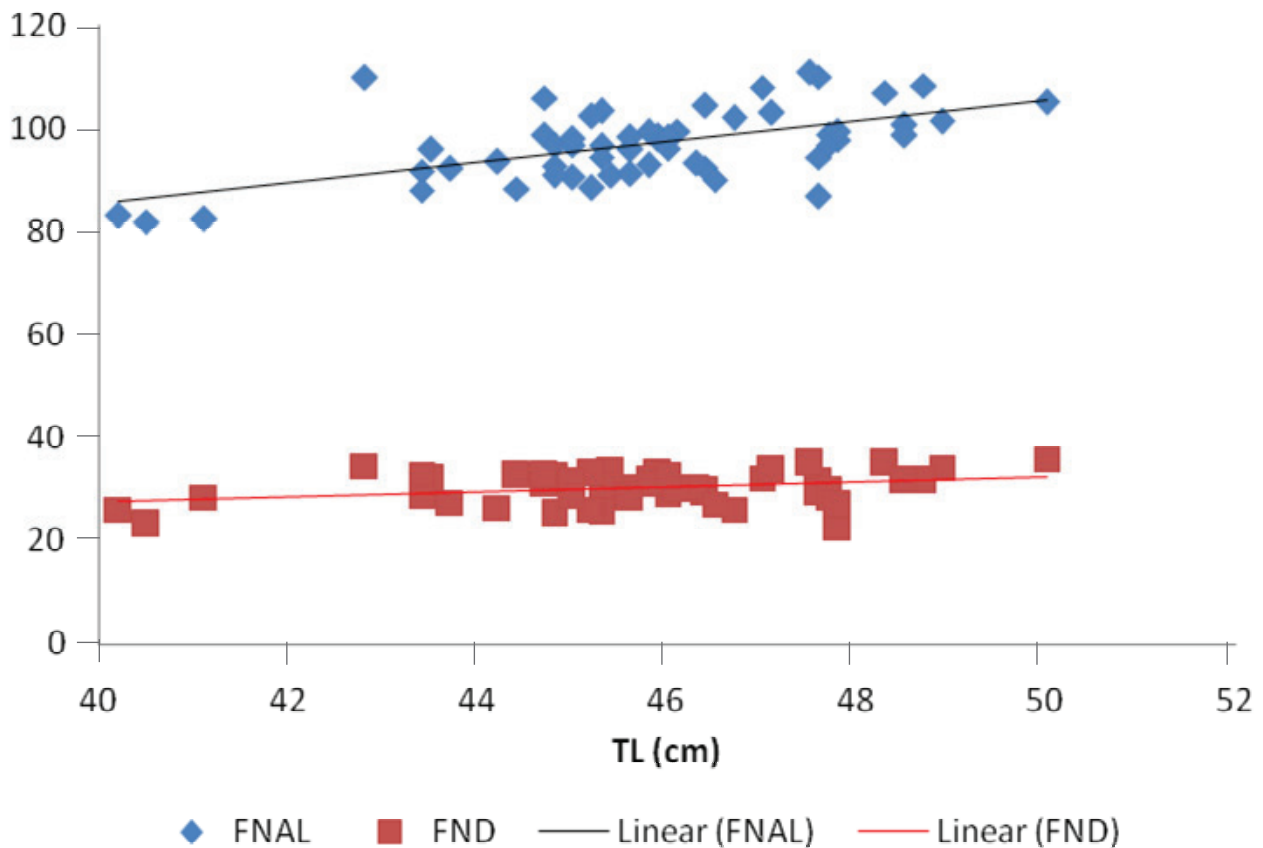


Figure 10
Scatter plot showing the relationship between TL, FNAL and FND



Regression analyses done revealed:

1. Significant statistical relationship between MFL and TL (p value = 0.0001) (Figure 8) and it generated an equation:
MFL = [2.5 + TL]
2. MFL had statistically significantly relationship with FNSA. (p value = 0.0127) (Figure 9)
FNSA = 75.6 + 1.15(MFL)
MFL = 35.45 + 0.095(FNSA)
3. There was no significant statistical relationship between TL and FNSA, (p value = 0.0780)
4. Significant statistical relationship between MFL and FNAL (p value = 0.0001) (Figure 9) generating the equation:
FNAL = 5.05 + 1.9(MFL)
MFL = 30.5 + 0.18(FNAL)
5. Statistically significant relationship between the TL and FNAL (p value = 0.0001) (Figure 10) generating the equation:
FNAL = 2.06(TL) + 5
6. TL had statistically significantly relationship with FND, with a p value of 0.0169, (Figure 10) generating the equation:
FND = 6 + 0.5(TL) ± 5mm
7. MFL had a significant statistical relationship with FND (p = 0.043)
MFL = 42.14 + 0.19(FND)

DISCUSSION

The proximal femoral dimensions obtained from this study were FNL = 22.9 ± 3.9mm, FNAL 96.9 ± 6.9mm, FND = 30.3 ± 2.9mm, PFSD = 28.4 ± 2.1mm and FNSA 130.8° ± 7.3°. It also documented significant statistical relationships between parts that made up proximal femur and the femur length, unlike a similar study amongst Indians by Ghosh *et al* (10) where they documented no significant statistical relationships between parts of proximal femur. The anteversion angles were excluded in this study because a previous study has documented the average value of anteversion angle to be 20.50° ± 5.50° and 21.30° ± 6.00° using the Kingsley Olmsted (KO) method and digital measurements with IC measure® respectively (11).

The Femoral Neck Length (FNL) obtained from this study was corroborated by another study done amongst Nigerians, which documented the neck length to be 20.8±1.1 and 17.9±1.0 in male and female respectively (12). The femoral neck length in Nigerians seems to be shorter than the average values documented from various parts of the world (5,13-18). More studies should be conducted to unravel the reason and implication of the shorter femoral neck length among Nigerians.

The Femoral Neck Axial Length (FNAL) measured was also noted to be shorter than the values documented in Brazilians (15,16) but longer than the values documented in the study from Egypt (6). It is important to know the average value and the range of the FNAL in a population. This is important for implants' manufacturers to know the range of hip screws length that would serve the population appropriately. Though the traditional method to estimate the FNAL during pre-operative planning is from plain anteroposterior pelvic radiograph, this study revealed an equation that can also be used as an adjunct for the estimation of FNAL. It would be useful to confirm measured values, or when the magnification factor of the radiograph is not known and cannot be calculated during pre-operative planning. The equation derived was:

Estimated value of FNAL = $0.206 \times TL + 5$ (TL in mm)

The actual value of FNAL will be within ± 15 mm of the estimated value obtained from the equation.

The Femoral Neck Diameter (FND) documented in this study is similar to the value documented from Kenyans (19), Nepalese (14), Malay (20) and Indians (17,18,21) but smaller than the values documented for the Brazilians (15,16). The femoral neck diameter is important in orthopaedic surgery as screws used for fracture osteosynthesis transverse through the femoral neck to the head. In Dynamic Hip Screw (DHS) fixation, the outer diameter of the hip screw that is used is 12.5mm. Based on volume, the DHS screw occupies approximately 17% of volume of an average diameter of the femoral neck. The emergency hip screw of the DHS, which is usually used for revision cases, has an outer diameter of 14mm, and will occupy 21% of the volume of the femoral neck. These screws sizes will not cause stuffing of the average femoral neck in Nigerian populace. In Proximal Femoral Nail Antirotation (PFNA), two screws are passed through the neck, a 6.5mm outer diameter hip pins which is for rotational stability and an 11mm outer diameter femoral neck screw, both of which are of various lengths. Summation of the 2 screws diameters (17.5mm) with a minimum of 5mm in between these screws will give a summation of 22.5mm, which the average femoral neck diameter can still accommodate appreciably. Volume wise, both screws will occupy 18% volume of the femoral neck. Moreover, in Gardens' fracture of the neck of femur without displacement or minimal displacement, at least three 7.3mm screws are placed through the neck to the head. These three screws will occupy a total volume of 17.4% of an average femoral neck of the populace. The screws used during plate osteosynthesis

of 4.5mm proximal femoral plate (LCP® Plating System) - two 7.3mm screw and one 5mm screw will occupy a total 14.3% volume of the neck. For the proximal femoral plate system (PERI-LOC® PFP) which allows for different combination of either 4.5mm locking, or 6.5mm cannulated locking or 5.7mm cannulated locking screws placement, the maximum volume that the screws would occupy, if only 6.5mm screws are used will be 19.6% of the femoral neck. The dimension of the blade part of the angled blade plate, will occupy 8.8% of the volume of the neck. Therefore, the screws used for fixation, of any of the aforementioned surgical implants which will transverse the femoral neck would be accommodated by the average femoral neck diameter without causing stuffing of the marrow. The blade part of the angled blade plate is also accommodated comfortably by the femoral neck. Although, the FND can be measured easily from a plain anteroposterior radiograph of the pelvis, this study also provided an equation that can be used to estimate FND. The equation is

Estimated value of FND = $6 + 0.05 \times TL$ (TL in mm)

The actual value of the femoral neck diameter will be within ± 5 mm of the estimated value. This equation can be used as an adjunct to the measurement from the radiographs.

The NSA documented in this study was $130.8^\circ \pm 7.3^\circ$, which is similar to value documented by Adekoya-Cole *et al* (7). It is also similar to the value documented by other studies (15,16,19,22,23) but larger than the values in Indians (13,17,18,21) and Nepalese (14) and smaller than the values documented in Caucasians and Chinese (3). Though, it is advisable for the orthopaedic surgeon to estimate the neck shaft angle of the uninjured side before deciding on the surgical implant to be utilized, the desirable implant with correct estimated neck shaft angle size should also be made available for the use of the surgeons. For example, the 135° Barrel plate of the Dynamic Hip Screw (DHS) is the most common in our environment, though the barrel plate ranged from $130^\circ - 150^\circ$. Thirty six percent of the bones studied had angles that were 129 and below. The barrel plates range (130° to 150°) would be ideal for 64% of the bone used in this study. It would be ideal if barrel plates with smaller angles can be manufactured for regions with population whose average FNSA are 130° and below. The 130° barrel plates should also be made available for use in our environment. The proximal femoral nail comes in three different neck shaft angles, 125° , 130° and 135° but the 135° is the most commonly available implants, whereas the 125° and 130° degrees nails

will fit more proximal femurs in our environment. The Egyptian study by Tarek (6) has demonstrated the effect of using implants with larger angles, with resultant distortion of the native anatomy of the proximal femur. It is pertinent that the manufacturers and vendors avail the orthopaedic surgeons the opportunity of using the appropriate implants for the populace in a particular region. It is also important that hospital administrators stock appropriate implants for use by the surgeons.

The regression analyses of the data obtained from this study generated several equations that would be useful in the estimation of parts of proximal femur and the femoral length, either in clinical scenarios or in forensic medicine. In many researches involving living subjects, the trochanteric length of the femur (length from the tip of greater trochanter to the lateral condyle) is usually assumed as the Maximum Femoral Length (MFL) (from the head of the femur to the medial condyle of the femur). However, measurements in this study had shown that the variation between the MFL and TL was between +1.4cm to +3.9cm. An equation that can help give the best estimate of the actual femoral length is important. The regression analysis of the data from this study generated the equation:

Estimated value of MFL = 2.5 + TL (TL in cm)

The actual femoral length will be within ± 1 cm of the estimated value obtained from the equation. The actual length of the femur can be easily estimated from this equation. This would be useful in forensic medicine and in researches where the actual femoral length is needed, especially in living subjects. The trochanteric length is easily measured in living subjects and therefore, it was used as the parameter from which the estimate of other parts of the proximal femur can be obtained. It is measured from the tip of the greater trochanter to the lateral knee joint, with a tape rule. In forensic medicine, the femoral length can be estimated from the femoral neck shaft angle or remnant of the proximal femur. The estimated length of femur can then be used to estimate the height of the patients or victims. These equations are:

MFL = 35.45 + 0.095 (FNSA)

MFL = 30.5 + 0.18 (FNAL)

MFL = 42.14 + 0.19 (FND)

CONCLUSION

This study has provided data that would enable orthopaedic surgeons aware of the dimensions of proximal femur in Nigerians. It has also provided data for implants manufacturers to know the

dimensions of implants that would fit Nigerians. Various equations generated from this study will be useful in pre-operative planning, clinical settings and forensic medicine. Most of the surgical implants available will serve our population except that implants made with neck shaft angle of 130° and below should also be made available for use.

ACKNOWLEDGEMENT

The authors are indebted to Messrs. Wale Oladele and Michael Izegebu for the assistance rendered during the collection of the specimens used for this study

Conflict of interest: None to declare.

REFERENCES

1. Konda, S.R. Anatomy of the proximal femur. In: Egol K., Leucht P. (editors). Proximal femur fractures. Springer, Cham. 2018:1 – 7.
2. Nayagam, S. Warwick, D. Orthopaedic operations. In: Solomon, L. Warwick, D Nayagam, S editors. Apley's system of orthopedics and fractures. 9th edition. London. Hodder and Arnold; 2010:311 – 314.
3. Hoaglund, F.T. and Low, W.D. Anatomy of the femoral neck and head, with comparative data from Caucasians and Hong Kong Chinese. *Clin Orthop Relat Res.* 1980; **152**:10-16. PMID: 7438592.
4. Siddiqi, N., Valdevit, A. and Chao, E.Y.S. Differences in femoral morphology among the Orientals and Caucasians: a comparative study using plain radiographs. *Anat Sci Int.* 2019; **94**:58–66.
5. Tang, Z.H., Yeoh, C.S. and Tan, G.M. Radiographic study of the proximal femur morphology of elderly patients with femoral neck fractures: is there a difference among ethnic groups?. *Singapore Med J.* 2017; **58**(12):717-720. doi:10.11622/smedj.2016148.
6. Tarek, A. Importance of restoration of proximal femur geometry in the management of intertrochanteric fractures using dynamic hip screw in Egyptian population. *Ortho Rheum Open Access.* 2017; **8**(4): 555744. DOI: 10.19080/OROAJ.2017.08.555744.
7. Adekoya-Cole, T.O., Akinmokun, O.I., Soyebi, K.O. and Oguche, O.E. Femoral neck shaft angles: A radiological anthropometry study. *Niger Postgrad Med J.* 2016; **23**(1):17-20. doi: 10.4103/1117-1936.180130. PMID: 27098944.

8. Shrestha, R., Gupta, H.K., Hamal, R.R. and Pandit, R. Radiographic anatomy of the neck-shaft angle of femur in Nepalese people: correlation with its clinical implication. *Kathmandu Univ Med J.* 2018; **16**(62):124-128. PMID: 30636752.
9. Müller, M., Abdel, M.P., Wassilew, G.I., Duda, G. and Perka, C. Do post-operative changes of neck-shaft angle and femoral component anteversion have an effect on clinical outcome following uncemented total hip arthroplasty? *J Bone Joint Surg.* 2015; **97-B**(12):1615-22. doi: 10.1302/0301-620X.97B12.34654. PMID: 26637674.
10. Ghosh, I., Sengupta, G., Basu, P. and Alpana, De (Bose). Assessment of relationship between neck shaft angle and neck length with interepicondylar distance in femur. *Int J Anat Res.* 2015; **3**(4):1710-1715. DOI: 10.16965/ijar.2015.322.
11. Akinmokin, O.I., Akinsulire, A.T., Ibeabuchi, N.M., Akinbode, O.O., Oyebiyi, I.A., et al. Femoral anteversion angles in dry bones of adult Nigerians: A comparison of two methods. *West Afr J Med.* 2020; **37**(4):391-395. PMID: 32835401.
12. Obikili, E.N. and Omotoso, D.R. Morphological evaluation and clinical significance of proximal femoral dimensions among Southern Nigerian population. *Int J Res Med Sci.* 2020; **8**:4180-84.
13. Isaac, B., Vettivel, S., Prasad, R., Jeyaseelan, L. and Chandu, G. Prediction of the femoral neck-shaft angle from the length of the femoral neck. *Clin Anat.* 1997; **10**(5):318-323. doi: 10.1002/(SICI)1098-2353(1997)10:5<318::AID-CA5>3.0.CO;2-M. PMID: 9283729.
14. Mukhia, R. and Poudel, P.P. Morphometric study of proximal end of femur of Nepalese people. *Nepal J Med Sci.* 2019; **4**(1):9-14.
15. de Farias, T.H., Borges, V.Q., de Souza, E.S., Miki, N. and Abdala, F. Radiographic study on the anatomical characteristics of the proximal femur in Brazilian adults. *Rev Bras Orthop.* 2015; **50**(1):16-21. doi:10.1016/j.rboe.2015.02.001.
16. Pires, R.E., Prata, E.F., Gibram, A.V., Santos, L.E., Lourenço, P.R. and Belloti, J.C. Radiographic anatomy of the proximal femur: correlation with the occurrence of fractures. *Acta Orthop Bras.* 2012; **20**(2):79-83. doi:10.1590/S1413-78522012000200004.
17. Sreenivasa, R. P. and Kumar DA. Morphometry of proximal end of femur in population of Telangana state and its clinical application. *Indian J Clin Anatomy Physiol.* 2019; **6**(1):57-60.
18. Ravichandran, D., Muthukumaravel, N., Jaikumar, R., Das, H. and Rajendran, M. Proximal femoral geometry in Indians and its clinical applications. *J Anatomical Soc India.* 2011; **60**(1): 6-12.
19. Lakati, K., Ndeleva, B., Mouti, N., and Kibet, J. Proximal femur geometry in the adult Kenyan femur and its implications in orthopaedic surgery. *East Afr Orthop J.* 2017; **11**: 22-27.
20. Baharuddin, M.Y., Kadir, M.R.A., Zulkifly, A.H., Saat, A., Aziz, A.A. and Lee M. M. Morphology study of the proximal femur in Malay population. *Int J Morphol.* 2011; **29**(4):1321-25.
21. Ramchander, S. Anthropometric study of proximal femur geometry and its clinical application. *Ann Natl Acad Med Sci.* 2018; **54**(4): 203-215.
22. Toogood, P.A., Skalak, A. and Cooperman, D.R. Proximal femoral anatomy in the normal human population. *Clin Orthop Relat Res.* 2009; **467**(4):876-885. DOI 10.1007/s11999-008-0473-3.
23. Waranuchitkul, S. and Lertwanich, P. Digital photographic measurements of the proximal femoral anatomy. *Siriraj Med J.* 2018; **70**(6):484-489.