

VARIATIONS IN THE COURSE OF THE COMMON PERONEAL NERVE IN THE KENYAN POPULATION: A CADAVERIC STUDY

M.M. Ayumba, MBChB, MMed (Orthop Surg Registrar), **M. K. Ndiema**, BVM, MSc, Department of Human Anatomy, **L. K. Lelei**, MBChB, MMed (Surg), Orth (UCT), FCS, Department of Orthopaedics and Rehabilitation and **M.G.Y. El-Badawi**, MBChB, PhD (Clin Anatomy), Department of Human Anatomy, Moi University, P.O. Box 4606 – 30100, Eldoret, Kenya

Correspondence to: Dr. Mwanaidi M. Ayumba, Department of Orthopaedics and Rehabilitation, Moi University, P. O. Box 4606 – 30100, Eldoret, Kenya. Email: mwanaidi@gmail.com

ABSTRACT

Background: The branches of the sciatic nerve are the common peroneal nerve and the tibial nerve. The common peroneal nerve is at most risk of injury during surgery due to its subcutaneous course at the back of the head of the fibula and at the neck of the fibula.

Objective: To demonstrate variations in the course of the common peroneal nerve in the Kenyan population.

Design: Anatomic descriptive cross sectional study that was conducted in the Moi University human anatomy laboratory.

Methods: Forty three right sided limbs were dissected (32 male, 11 female). Lateral approach to the knee was done as per Stanton. Data was collected into data sheets and fed into an electronic database. Photographs were also taken. Data was analysed and presented in means and medians.

Results: In one limb, the nerve emerged from the pelvis separate from the tibial nerve, proximal third of thigh (4 limbs-9.3%), middle thigh (8 limbs-18.6%), distal thigh (30 limbs-69.8%). The measurements of main trunk (mm) were: a mean of 212.6(±124.9), and median of 153(138, 230). The nerve branched inside the peroneus longus muscle in 39 limbs (91%), and remainder outside the peroneus longus.

Conclusion: In this population, the common peroneal nerve bifurcated from the sciatic nerve in the distal third of the thigh. This is important to know during surgeries in the knee and distal third of the thigh. In 9% of cases, the nerve divided into its 5 branches outside the peroneus longus muscle. This is especially important to know when performing knee arthroscopies and total knee replacements.

Key words: Course, CPN

INTRODUCTION

The common peroneal nerve is one of the nerves in the leg with variable bifurcation from the sciatic nerve. It runs downwards and laterally along the medial aspect of the biceps femoris muscle. It then traverses the back of the head of the fibula, and then curves around the fibular neck to pierce the peroneus longus muscle where it divides into the genicular branches, deep and superficial peroneal branches (1-3). Use of specific guidelines for dissection (4-6), various aspects of bifurcation may be demonstrated as have been addressed by several authors (1-3, 5-18). Positions of the nerve in relation to proximal fibula and tibia bones (6) have also been demonstrated. Gerdy's safe zone and its surgical importance (6) as well as the length of main trunk (19,20) have been documented. The nerve has variable number of branches (20), as well as variations in the course of these branches (21,22). The variations are of orthopaedic surgical importance (2,5,6,9,13,17,21-23).

MATERIALS AND METHODS

The study was conducted at the Moi University Human Anatomy Laboratory (MUHAL), after approval was granted by Institutional Research and Ethics Committee (IREC) and the Department of Human Anatomy. Forty three right sided formalin fixed limbs were obtained and dissected as per The Human Anatomy act (4). Right sided limbs were chosen as there were more in number compared to the left sided limbs. Dissection was carried out by lateral approach as described by Stanton, *et al.* (5), extended distally as described by Rubel, *et al.* (6) to expose the branches at the fibular neck. When the nerve was noted to bifurcate more proximally; dissection was directed posteriorly to expose the nerve at its bifurcation as described by Koshi, *et al.* (1). The nerve was then measured from its site of bifurcation from the sciatic nerve to where it branched into its five branches at the fibular neck. This measurement was then recorded as the main trunk length. Further measurements were taken to demonstrate the distances at which the five branches branched from the main trunk. These were taken with the bifurcation of the common peroneal

nerve from the sciatic nerve as the starting point. The five main branches were also noted to either branch within or outside the peroneus longus muscle.

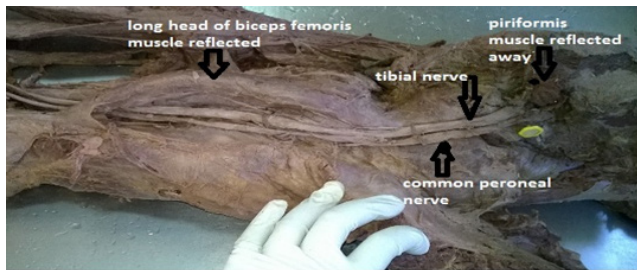
Data was collected and recorded in data sheets. Photographs of dissected exposed nerves were taken. Both data and photographs were fed into a restricted access electronic database. Data was analyzed using STATA 13 SE into means and medians then presented in tables. Statistical tests used were the *t* tests and Mann Whitney test.

RESULTS

The common peroneal nerve had a variable bifurcation. In one limb (2.3%), it emerged already bifurcated from the pelvis along with the tibial nerve below the piriformis muscle (Figures 1a and 1b).

Figure 1a

Common peroneal nerve pictured here emerging from the pelvis separate from the tibial nerve. They emerged below the piriformis muscle which has been reflected away



The common peroneal nerve was noted to bifurcate in the proximal third of thigh in 4 limbs-9.3% and the middle thigh in 8 limbs (18.6%).

Figure 1b

Sketch of the common peroneal nerve emerging from pelvis while already bifurcated

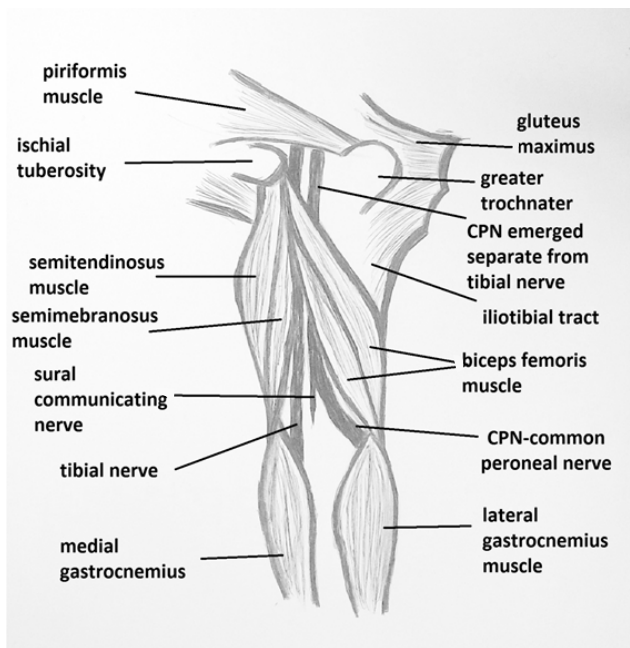
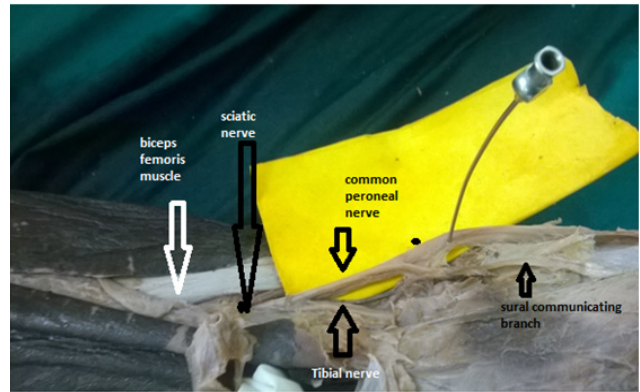


Figure 2a

Bifurcation of sciatic nerve into common peroneal nerve, in the distal third of the thigh



In 30 limbs (69.8%), the common peroneal nerve bifurcated in the distal third of the thigh (Figures 2a and 2 b).

Figure 2b

Sketch of the common peroneal nerve branching in the distal third of the thigh within the popliteal fossa

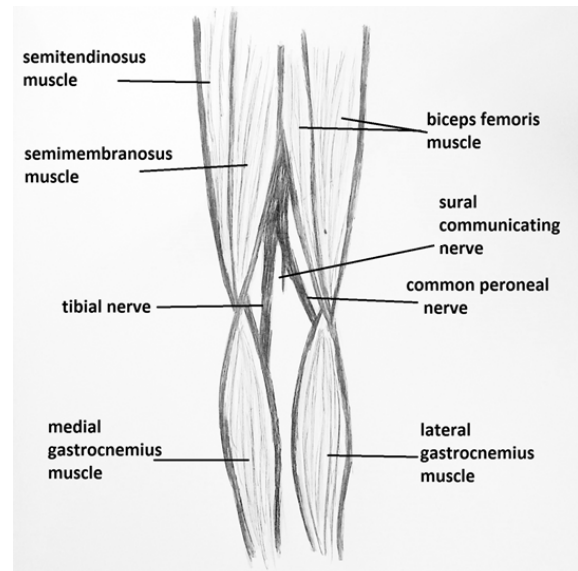
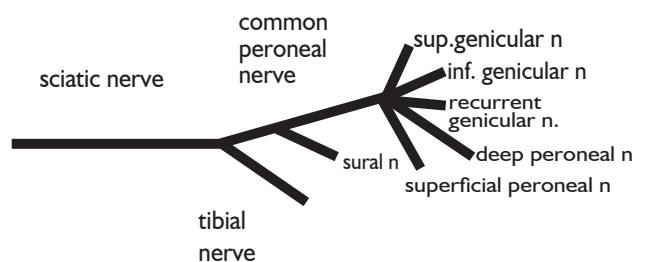


Figure 3

A schematic representation of the branching of the common peroneal nerve. The nerve divided into five branches at the neck of the fibula- superior genicular, inferior genicular, and anterior recurrent genicular branches. This was seen in 43 limbs (100%)



schematic of the branching pattern of the common peroneal nerve observed during dissection

The common peroneal nerve divided into its five branches at the fibular neck. The branches were three genicular branches-superior genicular, inferior genicular and anterior recurrent genicular branches, then the deep and superficial peroneal branches. This was seen in 43 limbs (100%). This is demonstrated in Figures 3, 4a, and 4b.

The main trunk of the common peroneal nerve had a variable length due to its variable bifurcation from the sciatic nerve. The measurements of the main trunk are summarized in Tables 1a and 1b. With regards to Table 1a, the measurements were found to be statistically significant ($p < 0.05$).

Table 1a
Main trunk measurements in 43 limbs

Variable	N	Mean (mm)	Median (mm)	Min	Max	Shapiro wilk test	
						W	P-value
Main trunk	43	212.6 (± 124.9)	153 (138,230)	105	523	0.717	<0.001

N-Number of limbs; Min- Minimum; Max-Maximum; SD- Standard deviation; IQR- Interquartile range; MT-Length of the main trunk

*All distances measured in mm

Table 1b
Main trunk measurements compared between the two genders

Variable	Female (n=11)	Male (n=32)	P-value
Main trunk (median)	175 (140,330) mm	152.5 (134.5, 212.5) mm	0.220†

† Comparison of medians using Mann whitney test

mm - Millimetres

n - Number of limbs

MT - Length of main truck

In the comparison of the main trunk median measurements between the genders, the p-value was found to be statistically not significant.

The levels at which the branches of the common peroneal nerve emerged from the main trunk were measured (in mm) from where the common peroneal nerve emerged from the sciatic nerve to where the branches exited the main trunk of the common peroneal nerve. These were then summarized into means and medians as represented in Table 2a. These were found to be statistically significant ($p < 0.05$).

Table 2a
Summary of statistics for branches of the CPN

Variable	N	Mean (SD)	Median (IQR)	Min	Max	Shapiro wilk	
						W	P-value
Sural communicating	28	90 (± 117)	55 (40,79)	5	420	0.594	<0.001
Superior genicular	43	212 (± 125.1)	155 (138,231)	90	524	0.733	<0.001
Inferior genicular	43	212.4 (± 125)	155 (139,230)	90	524	0.733	<0.001
Recurrent anterior genicular	43	214.6 (± 124.1)	165 (140,233)	100	524	0.733	<0.001
Deep peroneal	43	220.6 (± 127.2)	168 (145,230)	102	565	0.732	<0.001
Superficial peroneal	43	220.6 (± 126.6)	168 (144,234)	94	565	0.743	<0.001

N - Number of limbs; SD - Standard deviation; IQR - Interquartile range; Min - Minimum; Max - Maximum

The levels at which the branches emerged from the main trunk were compared between the genders. The difference in medians for males and females was not statistically significant

($p > 0.05$) for sural communicating nerve, superior genicular, inferior genicular, recurrent genicular, deep peroneal and superficial peroneal branches (Table 2b).

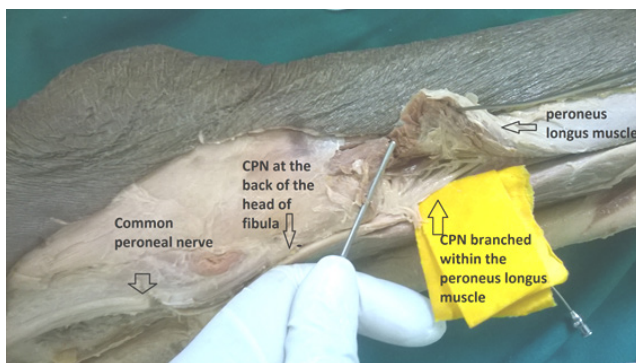
Table 2b
Summary of statistics for branches of the CPN compared between the genders

Variable	Gender	N	Mean (SD) [mm]	Min [mm]	Max [mm]	Median (IQR)[mm]	P-value
Sural communicating	Female	5	139.4 (±148.9)	12	395	82 (78, 130)	0.111
	Male	23	79 (±110.1)	5	420	55 (40, 63)	
Superior genicular	Female	11	245.3 (±141.5)	123	511	176 (143, 332)	0.186
	Male	32	200.6 (±119.3)	90	524	153 (132, 213.5)	
Inferior genicular	Female	11	245.7 (±141.4)	124	511	177 (144, 333)	0.190
	Male	32	200 (±119.1)	90	524	154 (132.5, 214)	
Recurrent genicular	Female	11	247.6(140.6)	126	512	186 (146, 330)	0.210
	Male	32	203.3 (±118.3)	100	524	158 (134, 215.5)	
Deep peroneal	Female	11	252.6 (±140.7)	126	517	207 (158, 331)	0.236
	Male	32	209.7 (±122.8)	102	565	162 (142, 213)	
Superficial peroneal	Female	11	251.4 (±138.1)	124	510	207 (158, 331)	0.259
	Male	32	210.1(±126)	94	565	160 (142, 215)	

Mann Whitney Test; n-Number of limbs; min-Minimum; max-Maximum; SD-Standard deviation; IQR-Interquartile range

Figure 4a


Branching of the nerve inside the peroneus longus muscle at the neck of the fibula



The CPN branches within the peroneus longus (Figure 4a). This was seen in 39 limbs (91%). Lastly, with regards to variations in branching at the neck of the fibula, the common peroneal nerve branched within the peroneus longus muscle as described in text books of anatomy (1- 3) in 39 limbs (91%). This is demonstrated in Figure 4a.

Figure 4b

Image of branching of the common peroneal nerve



The CPN divided into its branches outside the peroneus longus muscle in 4 limbs (9%). The peroneus longus muscle is reflected away (Figure 4b) to show the branches clearly. The branches demonstrated from superior to inferior area as follows: superior genicular (lateral) nerve, inferior genicular (lateral) nerve, recurrent genicular nerve, deep peroneal nerve and superficial peroneal nerve.

DISCUSSION

In this study, the common peroneal nerve bifurcated from the sciatic nerve then ran downwards and laterally, medial to the biceps femoris muscle then crossed the back of the head of the fibula. It then twisted around the neck of the fibula and pierced the peroneus longus muscle to divide into its genicular branches and its two terminal branches (deep and superficial peroneal branches). The finding concurs with what is described in standard anatomy text books (1–3).

In this study, the nerve bifurcated from the pelvis in 2.3% of cases which contrasts studies done where Ogeng'o, *et al.* (14), who found 20.1%, Kukiriza, *et al.* (15), who found 22.5% , Ibrahim, *et al.* (16) who found 11.7% of cases and Grewal, *et al.* (12) who found 10% of cases. The findings may differ from other authors (14–16) as they may have had larger study populations compared to this one. Grewal, *et al.* (12) had a smaller study population of 30 limbs compared to this one.

In most of the cases in this study, the sciatic nerve bifurcated into its branches in the distal third of the thigh. This concurred with other studies (7–9,12,14–18).

It contrasted other studies in Indian populations which documented lesser cases of bifurcation of the sciatic nerve in the distal third of the thigh (10,11). This knowledge is important to orthopaedic surgeons since the common peroneal nerve can get injured when performing both total hip and total knee arthroplasty (13).

With regards to main trunk mean length measurements, measurements were found to be statistically significant ($p < 0.05$). The measurements recorded in this study however contrasted those by Nayak, *et al.* (19) where they measured and compared the lengths of the main trunk of the common peroneal nerve in both the left and right lower limbs of cadaveric specimens. The team found that the trunk was longer in the left sided limbs of 19.1 ± 7.1 cm (191 ± 71 mm) while in the right lower limbs the measurements 17.7 ± 7 cm (177 ± 70 mm). The researcher found no reason for the difference found by Nayak, *et al.* (19) during literature review and conducting the study. The research findings of Nayak, *et al.* (19) lead one to question whether the levels of bifurcation of the sciatic nerve differ between right sided and left sided limbs, hence leading to different lengths of the main trunk of the common peroneal nerve in lower limbs from one cadaver, and whether this would also translate to findings in the general population. In this study, the researcher only studied right lower limbs and as such would not be in position to know if findings by Nayak, *et al.* (19) would be reproducible in this population with regards to differing lengths of the common peroneal nerve with regards to the side of the limb. The researcher also found no studies comparing the lengths of the common peroneal nerve in the genders. As such no comparisons can be made for the findings of this study with other studies.

The finding also contrasted that found by Thi, *et al.* (20) who found a mean length of 120.6 mm for the main trunk of the common peroneal nerve. The researcher found no comparable studies with regards to the levels at which the branches of the common peroneal nerve exited the main trunk.

With regards to the number of branches of the common peroneal nerve at the fibular neck, in this study, five branches were found. This concurred with Labronici *et al.* (21), but contrasted that by Takeda, *et al.* (22). In this study however, the median levels at which the branches emerged from the main trunk when compared between the genders was not statistically significant ($p > 0.05$).

The researcher found that in 4 limbs, the common peroneal nerve branched outside the peroneus longus muscle. This concurred with Deutsch, *et al.* (23) who found that in 10% of specimens, the common peroneal nerve divided into its branches proximally before reaching the fibular neck. This is of significance

especially when performing knee arthroscopies and total knee arthroplasties as documented by Brown, *et al.* (13).

CONCLUSION AND RECOMMENDATIONS

The common peroneal nerve has a variable bifurcation from the sciatic nerve. Surgeons need to know this while performing surgery in the lower limbs to avoid iatrogenic injuries to the nerve.

The variable bifurcation of the nerve from the sciatic nerve translates into variable lengths of the main trunk. In this population, since majority of the bifurcations were in the middle and distal third of the thigh. More studies need to be done with a larger study population.

More studies need to be done to see if there is a difference in the length of the main trunk of the common peroneal nerve in left and right sided limbs. More studies need to be done comparing the lengths of the main trunk in the genders.

There were five branches noted at the fibular neck of which 9% were outside the peroneus longus muscle. This is especially important to know when performing arthroscopic procedures in the knee, total knee arthroplasties, and in percutaneous procedures performed around the knee. The branches of the CPN emerged at different levels from the main trunk of the nerve. More studies need to be done on this so as to compare it in the genders and in different racial populations.

STUDY LIMITATIONS

The study had a smaller study population (43 limbs), as compared to other studies (14–16) hence comparison of findings with regard to pelvic origin of the common peroneal nerve differed.

The limbs availed for the study had already been separated from the cadavers. The right sided limbs were also more than the left sided limbs, as such, there was no way to determine if limbs came from the same cadaver, and also the disparity in the available numbers of right sided and left sided limbs made it impossible to study equal numbers of right sided and left sided limbs. The research team was not able to carry a study similar to the study done by Nayak, *et al.* (19), and thus couldn't compare findings (differing lengths of main trunk of the nerve between left sided and right sided limbs) fully.

DISCLOSURE STATEMENT

The research team did not receive any funding for this study.

ACKNOWLEDGEMENTS

To IREC and Department of Human Anatomy for permission to carry out the study, the technical staff in MUHAL, Academic staff in the Department of Human Anatomy as well as in the Department of Orthopaedics and Rehabilitation, and colleagues for their contributions.

REFERENCES

- Koshi, R., Suganthy, J. and Irodi, A. Cunningham's manual of practical anatomy; Upper and lower limbs. 16th ed. Vol. 1, Oxford University Press. Oxford University Press; 2017. 308-324 p.
- Gray, H., Standring, S., Ellis, H. and Berkovitz, B.K.B.. Gray's anatomy: The anatomical basis of clinical practice. 40th ed. Elsevier; 2008. p 1427.
- Sinnatumby CS. Last's anatomy, regional and applied. 12th ed. Horne T, Bowes J, Davies S, editors. 2011. 3:132.
- Laws of Kenya: The Anatomy Act [Internet]. cap 249 Kenya: <http://www.kenyalaw.org>; p. Cap 249. Available from: <http://guidelines.health.go.ke:8000/media/AnatomyAct21of1967.pdf>
- Stanton, J.E., Gupte, C.M. and Vishy, M. Surgical approaches to the knee joint. *Orthop Trauma*. 2010; **24**(2):92–99.
- Rubel, I.F., Leonard, A. and Cece, D. Anatomic location of the peroneal nerve at the level of the proximal aspect of the tibia: Gerdy's safe zone. *J Bone Joint Surg*. 2004; **86-A**(8):1625–28.
- Adibatti, M. and Sangeetha, V. Study on variant anatomy of sciatic nerve. *J Clin diagnostic Res*. 2014; **8**(8): AC07-9.
- Ugrenović, S., Jovanović, I., Krstić, V., et al. The level of the sciatic nerve division and its relations to the piriform muscle. *Vojnosanit Pregl*. **62**(1): 45–49.
- Okraszewska, E., Migdalski Ł., Jędrzejewski, K.S. et al. Sciatic nerve variations in some studies on the Polish population and its statistical significance. *Folia Morphol*. 2002; **61**(4):277–282.
- Kumar, M., Rani, A. and Latha, S. A cadaveric study of sciatic nerve and its level of bifurcation. *J. Clin Diagnostic Res*. 2011; **5**(8):1502–4.
- Prakash, R., Bhardwaj, A.K., Devi, M.N., et al. Sciatic nerve division: a cadaver study in the Indian population and review of the literature. *Singapore Med J*. 2010; **51**(9):721–722.
- Grewal, M., Harsimran, R., Kumar S., et al. Different levels of bifurcation of sciatic nerve: a novel classification based on a cadaveric study in Indian population. *Int J Anat Res*. 2016; **4**(3):2743–49.
- Brown, G.D., Swanson, E.A. and Nercessian, O.A. Neurologic injuries after total hip. *Am J Orthop*. 2008; **37**(4):191–197.
- Ogeng'o, J.A., Mwika, P.M., Khanbhai, M.M., et al. Variant anatomy of sciatic nerve in a black Kenyan population. *Folia Morphol*. 2011; **70**(3):175–179.
- Kukiriza, J., Kiryowa, H., Turyabahika, J. JOCBRI. Levels of bifurcation of the sciatic nerve among Ugandans at School of Biomedical Sciences Makerere and Mulago Hospital Uganda. *East Cent Afr J Surg*. 2010; **15**(2):69–75.
- Ibrahim, F.A.L, Dorazi, S.A.L., Talal, W.A.H., et al. Peroneal syndrome. In: 5th ISCAA and 1st Paneuropean Congress [Internet]. Graz – Austria, 24th to 26th May 2013: www.anatclin.com.ar; 2013. p. 100. Available from: https://mafiadoc.com/5th-international-symposium-of-clinical-and-applied-anatomy-and-1st_5c148078097c47711e8b4586.html
- Berihu, B. and Debeb, Y. Anatomical variation in bifurcation and trifurcations of sciatic nerve and its clinical implications: in selected university in Ethiopia. *Biomed Cent Res Notes*. 2015; **2**(8):633–640.
- Leishiwon, P.S., Matum, M., Devi, A.J., et al. Level of division of sciatic nerve in fetuses. *J Med Soc*. 2015; **29**(3):169–171.
- Nayak, N., D'Souza, S., Ankolekar, A., et al. Surgical anatomy of common peroneal nerve. *Biomed Rev J Basic Appl Med Sci*. 2015; **2**(3):45-48.
- Thi, C., Van Huy, N., Nguyen, N.C., et al. Applied anatomy of common peroneal nerve: A cadaveric study. *Int J Med*. 2018; **6**(1):6–10.
- Labronici, J.P., Martins, T.T., Barone de Medeiros, F., et al. Clinical and anatomical comparison of the fibular nerve in Gerdy's safe zone. *Rev Bras Orthop*. 2010; **45**(1):23–27.
- Takeda, A., Tsuchiya, H., Mori, Y., et al. Anatomical aspects of biopsy of the proximal fibula. *Int Orthop*. 2001; **6**(24):335–337.
- Deutsch, A., Wyzkowski, R. J. and Victoroff, B.N. Evaluation of the common peroneal nerve. Defining nerve-at-risk in arthroscopically assisted lateral meniscus repair. *Am J Sport Med*. 1999; **27**:10–15.