

## EARLY OPERATIVE MANAGEMENT OF PILON FRACTURES USING THE ANTEROLATERAL APPROACH: A CASE SERIES

**D. Ankit**, MBChB, Orthopaedic Surgery Resident, Department of Orthopaedic Surgery, College of Health Sciences, University of Nairobi, P.O. Box 19676 – 00202, Nairobi, Kenya and **P. Orok**, MMed (Surg), FRCS (Trauma and Orthopaedics)-UK, Department of Surgery, Aga Khan University Hospital Nairobi, Kenya

**Correspondence to:** Dr. Dave Ankit, Department of Orthopaedic Surgery, College of Health Sciences, University of Nairobi, P.O. Box 19676 – 00202, Nairobi, Kenya. Email: ankitdave26@hotmail.com

### ABSTRACT

**Background:** Pilon fractures is a management challenge due to complexity of fracture pattern and complications. The soft tissue state and its subsequent handling is crucial in its outcome. The approach overlying the subcutaneous border of the tibia has wound healing complications. The anterolateral approach has become popular as it offers improved soft tissue coverage leading to fewer wound complications but it is dictated by the fracture pattern and the anterolateral plate use. Additional exposures may be required to address other areas, such as the medial malleolus which cannot be accessed through this approach.

**Objective:** To report the results of patients with pilon fractures who were operated using the antero-lateral approach.

**Methods:** Review of patients who underwent antero-lateral plating for pilon fractures.

**Results:** Six patients were assessed retrospectively following antero-lateral plating. Five patients were operated within 24 hours and 1 operated after 10 days due to athletes' foot. Out of the 6 patients 2 were put on external fixator for reduction purpose away from the plating site. A standard antero-lateral approach was done to plate the distal tibia in all patients, a separate medial incision to plate the medial malleolus was used depending on the fracture pattern and a lateral incision to plate the fibula in all cases. All had good results radiologically and clinically. There were no wound healing problems.

**Conclusion:** Early operative management of pilon fractures using an anterolateral approach provides excellent exposure for accurate fracture reduction and no wound complications in our case series but warrants further evaluation with a larger study population before establishing it as the treatment of choice in our environment.

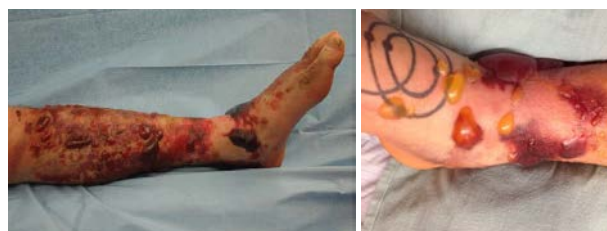**Key words:** Pilon/Tibial plafond fracture, Anterolateral approach

### INTRODUCTION

Pilon fractures have been historically known to cause several management dilemmas due to the superficial nature of the distal tibia and a thinner soft tissue cover over it. The mechanism of injury is an axial load which is most of the time a high-energy transfer injury leading to a multi-fragmentary fracture and significant soft tissue injury. The management of these fractures have been known to cause several complications including wound dehiscence, superficial infection, osteomyelitis, mal-union, non-union and on the end of the spectrum is joint arthrodesis and amputation (1). There are challenges in management and the outcome is not predictable and several studies have been done to guide in management of these injuries (2-6).

**Figure 1**

*Soft tissue injury/blistering in pilon fractures*



In the management, the surgeon has to consider the bony and the soft tissue injuries and have a balance between the two. Classically the teaching is "span-scan-plan" whereby initially the fracture is stabilized with an external fixator and the soft tissues allowed to settle followed by a CT scan which helps in planning the operation (1). It takes several days (average 12.7 days) (6) for soft

tissues to settle and the disadvantage in waiting several days is that the fracture site becomes sticky and the accuracy of reduction is affected. On the other hand, if the fracture is operated on early then the reduction may be good but this possesses a risk in wound complications (7) as mentioned above.

The study by Ruedi and Allgower (8) recommend the 4 principles that need to be adhered to achieve better outcomes:

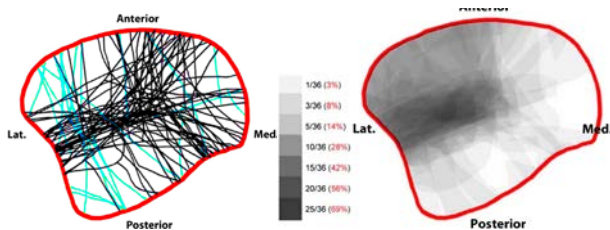
- (i) Reconstruction of the correct length of the fibula.
- (ii) Reconstruction of the articular surface of the tibia.
- (iii) Introduction of a cancellous autograft to fill in the bone defect in the metaphysis of the tibia.
- (iv) Stabilization of the medial aspect of the tibia by a plate. The AO group and worldwide these principles have been accepted and has been the teaching in managing these fractures (9).

This study was a breakthrough in the management of these fractures. Some authors have, however, advocated for staged management of these fractures (1,7,6,9). But with the advancement of healthcare technology like locking plates and the demand for early management of these fractures, there are some gaps in the management which should be in keeping with the modern times.

The Pilon map described in 2013 in the *Journal of Orthopedic Trauma* by Cole *et al* (10) described the pattern of fracture lines through the pilon. This knowledge can be applied to assist in exposure, reduction and application of implants so that the major fragments are held in a biomechanically and anatomically rigid construct.

**Figure 2**

*2a fracture lines and 2b comminution zones (intensity of grey represents frequency)*



**Figure 2A**  
Fracture lines

**Figure 2B**  
Comminution zones  
(intensity of grey represents frequency)

The most frequent zone of injury in the "pilon" is the anterolateral fragment. With this information, it makes sense to approach these fractures from

the anterolateral side in-order to buttress this fragment and assist in reduction.

The anterolateral aspect of the distal tibia also has a better soft-tissue cover compared to the medial side hence should have less wound complications, better exposure, better reduction and ultimately a good outcome for the patient.

## MATERIALS AND METHODS

This study is a case series of 6 patients who were retrospectively reviewed with the help of case notes, radiographs and patient follow up notes in the hospital database. Five patients were operated within 24 hours and 1 operated after 10 days due to athlete's foot. Out of the 6 patients, 2 were put on spanning external fixator on the medial side for the purpose of reduction.

A standard anterolateral approach was done to plate the distal tibia in all patients, a separate medial incision to plate the medial malleoli was used depending on the fracture pattern and a lateral incision to plate the fibula in all cases. AO principle was applied to fix all the fractures.

There are certain techniques used in handling soft tissues which we believe affected outcome:

- (i) No touch on skin- no self-retaining skin retractors.
- (ii) Full thickness fasciocutaneous flaps- no skin flaps.
- (iii) Expose bone only as needed-epiperiosteal bone exposure.
- (iv) Work through fracture site for articular reduction.
- (v) Careful closure.

## The approach

*Position:* Supine with tourniquet and sandbag under the ipsilateral buttock.

*Incision:* Anteriorly midpoint between the two malleoli over the distal tibia-in line with 4th metatarsal.

*Superficial dissection:* Tissue and fascia incised in line with skin incision. A plane is developed between the peroneus brevis and extensor digitorum longus protecting the superficial peroneal nerve.

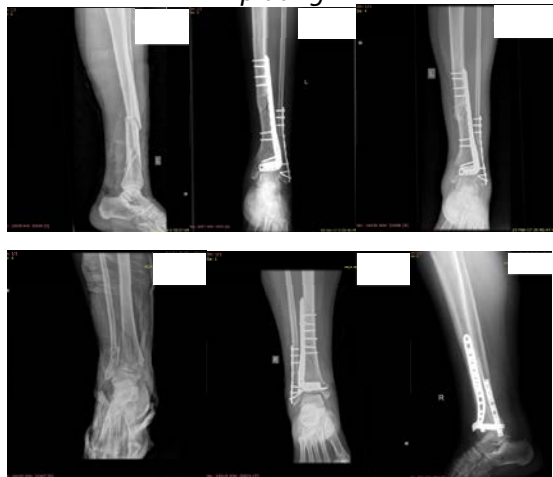*Deep surgical dissection:* Detach extensor muscles from the anterior aspect of the interosseous membrane and desired surface of tibia.

## RESULTS

All patients had radiological and clinical union and none had wound complications

**Figure 3**

Post-operative images using the anterolateral plating



## DISCUSSION

There is some literature on early primary ORIF-open reduction and internal fixation. Most notably, in 2010 White *et al* (11) did a study whereby 95 patients with 43.C pilon fracture were managed early with primary ORIF. The outcomes measures were wound dehiscence or deep infection requiring surgery, quality of fracture reduction, functional outcomes (SF-36 and foot and ankle outcome score). In this study only 6% had wound complications and 90% had fractures that were anatomically reduced.

Tang *et al* (1) compared early vs late ORIF for type C fractures. They sampled 46 patients (group A were operated within 36 hours vs group B were operated at 10 days-3 weeks). The study showed that there was no significant difference ( $p > 0.05$ ) between the two groups regarding rate of soft tissue complication, rate of fracture union and final functional score. Group A had shorter mean time to fracture union (21.5 weeks vs 23.3 weeks) and hospital stay (7.6 vs 4.2) talk about approach.

We believe that early operative management of pilon fractures using the anterolateral approach provides excellent exposure for accurate fracture reduction and there were no wound complications in our case series but warrants for further studies with a larger study population before establishing it as the treatment of choice for our environment. Haematoma drainage reduced swelling- helps in closure of wound.

## REFERENCES

1. Tang, X., Liu, L., Tu, C., Li, J., Li, Q. and Pei, F. Comparison of early and delayed open reduction and internal fixation for treating closed tibial pilon fractures. *Foot Ankle Int.* 2014; **35**(7):657-664.
2. Assal, M., Ray, A. and Stern, R. The extensile approach for the operative treatment of high-energy pilon fractures: surgical technique and soft-tissue healing. *J Orthop Trauma.* 2007; **21**(3):198-206.
3. Howard, J.L., Agel, J., Barei, D.P., Benirschke, S.K. and Nork, S.E. A prospective study evaluating incision placement and wound healing for tibial plafond fractures. *J Orthop Trauma.* 2008; **22**(5):299-305.
4. Ramlee, M.H., Abdul Kadir, M.R., Murali, M.R. and Kamarul, T. Finite element analysis of three commonly used external fixation devices for treating Type III pilon fractures. *Med Eng Phys.* 2014; **36**(10): 1322-1330.
5. Danoff, J.R., Saifi, C., Goodspeed, D.C. and Reid, J.S. Outcome of 28 open pilon fractures with injury severity-based fixation. *Eur J Orthop Surg Traumatol.* 2015; **25**(3): 569-575.
6. Wang D, Xiang JP, Chen XH, Zhu QT. A Meta-analysis for postoperative complications in tibial plafond fracture: Open reduction and internal fixation versus limited internal fixation combined with external fixator. *J Foot Ankle Surg.* 2015; **54**(4): 646 – 651.
7. McFerran, M.A., Smith, S.W., Boulas, H.J. and Schwartz, H.S. Complications encountered in the treatment of pilon fractures. *J Orthop Trauma.* 1992; **6**(2):195-200.
8. Rüedi, T.P. and Allgöwer, M. The operative treatment of intra-articular fractures of the lower end of the tibia. *Clin Orthop Relat Res.* 1979; **138**:105-110.
9. Blauth, M., Bastian, L., Krettek, C., Knop, C. and Evans, S. Surgical options for the treatment of severe tibial pilon fractures: a study of three techniques. *J Orthop Trauma.* 2017; **15**(3):153-160.
10. Cole, P.A., Mehrle, R.K., Bhandari, M. and Zlowodzki, M. The pilon map. *J Orthop Trauma.* 2013; **27**(7):e152-e156.
11. White, T.O., Guy, P., Cooke, C.J., *et al.* The results of early primary open reduction and internal fixation for treatment of OTA 43.C-type tibial pilon fractures: a cohort study. *J Orthop Trauma.* 2010; **24**(12):757-763.