

OPERATIVE TREATMENT OF PRIMARY BONE TUMOURS OF THE FEMUR AND THE TIBIA

S. Badio Seyni, MD, A. Wahab, MA, Z. Konguisé, MD, Service d'orthopédie-traumatologie Hôpital National Lamordé (CHU), Niamey/ Niger, M. Ropars, MD, J-C Lambotte, MD, H. Thomazau, MD, and D. Hutten MD, Service de chirurgie orthopédique CHU Pont Chaillou Rennes / France

Correspondence to: Dr. S. Badio Seyni, Service d'orthopédie-traumatologie Hôpital National Lamordé (CHU) Niamey/ Niger. Email: badioseyni@yahoo.fr

ABSTRACT

Introduction: Benign bone tumours of the long bones of the lower limbs are accessible to surgical treatment by resection of the tumour and reconstruction of the loss of bone substance by intercalary allograft. Massive allografts have a primary mechanical strength but pose the problem of the frequent complications that they can cause infection, pseudoarthrosis and pathological fracture.

Objective: The purpose of this study was to present the results of this conservative surgery in 15 patients.

Methods: A continuous retrospective study was carried out at the Trauma and Orthopaedics Department of the Rennes University Hospital, covering 15 interlayer allografts performed on 15 patients over a period of 16 years. Tumour resection followed the principles of surgery of primitive malignant bone tumours. The tumour was removed as a whole leaving a layer of healthy tissue in contact with the tumour. The height of the bone sections was determined on the preoperative Magnetic Resonance Imaging (MRI), performed before chemotherapy if necessary, in order to leave a margin of two centimetres of healthy bone.

Results: The average age of the series was 34.2 years (9 to 61 years). There were 8 (53.4%) female patients and 7 (46.6%) male patients. In patients with primary bone tumours of the tibia and of the femur, tumour resection was performed on the femur 11 times and on the tibia 4 times. Out of 35 surgeries, 15 cases of first surgery and 20 cases of second surgery, all of the grafts consolidated with an average period of 16 years (11 to 25 years). There were 20% cases of infections cases and 13.3% cases of fractures.

Conclusion: This study shows that consolidation of the intercalary allograft is still obtained, but after several re-surgeries.

Key words: Bone tumour, Femur, Tibia, Resection, Allograft

INTRODUCTION

The increase in life expectancy of patients that went through a malignant bone tumour surgery, notably due to advances in chemotherapy, has altered the initial surgical management, with more limbs saved and fewer amputations (1-3).

The malignant bone tumours of the long bones of the lower limbs are accessible to surgical treatment by tumour resection and reconstruction of the loss of bone by intercalary allograft. By bone allograft, we mean a bone segment taken sterile from an organ donor and stored at -80°C. It is called massive when it replaces a circular segment of a long bone or a hemi-epiphysis (4). In short term, allografts allow a valid reconstruction of a compromised anatomy. In the long term, i.e. beyond 24 months, the allograft may present complications inherent in its non-revascularization (4). Historical studies (5,6) showed that revascularization remained very limited and almost exclusively on the surface.

Massive allografts have a primary mechanical strength but pose the problem of the frequent complications they can cause, namely infection, pseudoarthrosis, pathological fracture and lack of long-term integration. Thus, according to the series of various studies (5-7), the rate of non-consolidation of the intercalary allografts varies between 17 and 57 %.

A continuous retrospective study was carried out at the Orthopaedic and Traumatology Department of the Rennes University Hospital, on 15 intercalary allografts carried out in 15 patients over a period of 16 years. The aim of this study was to present the results of this conservative surgery in these 15 patients.

MATERIALS AND METHODS

This was a continuous retrospective study of a series of 15 patients that went through surgery between 1986 and 2002 in the Department of Orthopaedic-traumatology Surgery of the Teaching Hospital of Rennes.

The average age of the series was 34.2 years (9 to 61 years). Eight (53.4%) of the patients were female and (46.6%) were male. Included in this study were all patients who went through surgery for diaphyseal or metaphyseal/diaphyseal primary tumour of the tibia and/or femur. These patients had a tumour resection with intercalary allograft and a vascularized fibula in one case. Patients with secondary or benign bone tumours with epiphyseal localization and those with bone resection with-in continuity, and those patients with prosthetic reconstruction were excluded from this study. Patients who went through surgery outside the study period were not included in this study.

Tumour resection involved the femur in 11 cases and the tibia in 4 cases. Tumour resection followed the principles of malignant bone tumour surgery (8). The whole of the tumour was removed leaving a layer of healthy tissue in contact with the tumour. The height of the bone section was determined on the pre-surgery MRI, performed before chemotherapy if necessary, to leave a margin of two centimetres of healthy bone. The scar and the biopsy tract were removed enblock in a single piece. Tumour resection and intercalary reconstruction were performed in one stage, so the bone section should be made 5 cm above and below the tumour. This interlayer allograft often is anchored by either an osteosynthesis material (locked nail TDN, condylar plate, screwed plate), or an articular prosthesis.

Histologically, the tumours were: 7 chondrosarcomas (type I and II) 6 Ewing's sarcomas, 1 osteosarcoma and 1 fibrous dysplasia. The immediate secondary and late complications were investigated and revealed early or late infections which were treated by parenteral antibiotics and by surgical debridement. This surgical procedure went from the resection of the contaminated soft and bone parts to the complete resection of the intercalary allograft in case of massive sepsis. The consolidation delay was detected and treated with "Enriched Marrow Injection".

The pseudoarthrosis was treated by periosteal osteitis deactivation and the addition of an autologous corticocancellous graft from the iliac crest; with or without change of the osteosynthesis material. The pathological fracture was handled either by internal osteosynthesis or by plaster casting. Long-term osteolysis of the interlayer allograft was investigated on the treatment of the limb segment.

Evaluation of treatment outcomes: Patients were reviewed at the greatest follow-up and this evaluation was about the evolvement of the tumour pathology (cure, death), the consolidation of the intercalary allograft, the number of surgical interventions (for mechanical or infection reasons) necessary for the consolidation of the interlayer

allograft, holding of the osteosynthesis or prosthesis material, the state of joint mobility of the joints adjacent to the intercalary allograft; the existence of inequality of length between the lower limbs, and the resumption of activity (professional or sport).

RESULTS

The median length of bone resection was 330 mm (100 to 400 mm) throughout the series. At the end of tumour resection, bone loss was bridged in 14 cases with a massive allograft (Figures 1 and 2), and in 1 case, the filling was obtained using a vascularised fibula autograft taken from the contralateral limb. The fixation of the graft was ensured by locked nail in 12 cases, by blade plate stand alone in 1 case, and by the locked nail augmented with 2 plate blades. In addition, chemotherapy treatment was given to 5 patients (33.3%). The allograft had consolidated in these patients.

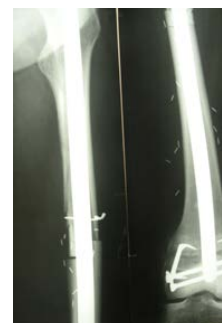
Figure 1

Assembly with perfect inter-fragmentation between intercalary allograft and the rest of the recipient tibia. Fixation by nail, blunt staples and screws

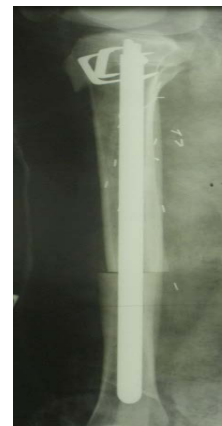

Figure 2

Intercalary allograft of the femur, fixation by locked nail and blunt staples



In 4 patients (30.7%), the allograft had consolidated without infection or any further surgical procedure (Figures 3 and 4). However, complications were observed in the rest of the patients as follows: Infection occurred in 3 patients (20%) (in one patient, infection occurred in the first month post-surgery, in another, infection occurred in the 7th month, and in the third patient infection occurred around the tenth month). Treatment of infections required 9 surgical procedures. Septic or aseptic pseudoarthrosis occurred in 8 patients (61.5%). The pseudoarthrosis occurred at the proximal junction of the allograft in 5 cases (33.3%) and at the distal junction in 3 cases (20%). Among these 5 patients, 3 were undergoing chemotherapy. The treatment of pseudoarthrosis consisted of an osteoperiosteal decortication with the addition of enriched marrow or cancellous autograft from the iliac crest.

Figure 3

Consolidation of an intercalary allograft to the tibia fixed by blount staples and locked nail

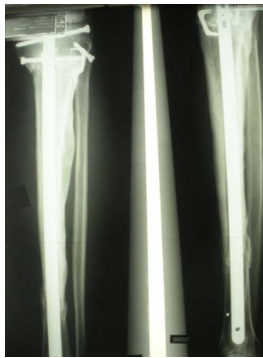
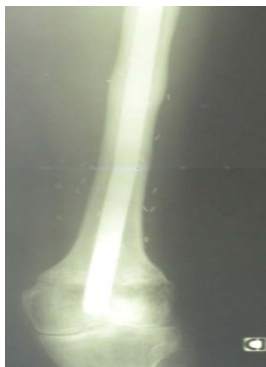
Figure 4

Consolidation of the allograft with ablation of the staples



The change of the osteosynthesis material was recorded in 4 patients (26.6%). In one case, the treatment was part of the treatment for an aseptic pseudoarthrosis in 2 cases, for the treatment of a septic pseudoarthrosis, and in one case in the treatment of a pathological fracture of the allograft. Thus, 2 (13.3%) of pathological fractures were recorded: 1 case subsequent to a fall which was treated by plaster casting, and the second, subsequent to a traffic accident and was treated by nailing.

Integral allograft osteolysis occurred in 2 patients (13.3%), without influence on the process of integration of the intercalary allograft. In terms of the sequelae: stiffness of the knee occurred in 3 (20%) patients and were treated by Judet intervention; the inequality of length of the limbs occurred in 1 patient. With a mean follow-up of 16 years (11 to 25 years), no case of insufficient tumour resection was recorded. Twenty reoperations were necessary to achieve consolidation of the intercalary allografts in the 15 patients.

DISCUSSION

The use of allografts is charged with a high rate of complications. These complications are related to the non-vascularization of the grafted bone, which should be considered as an equivalent to an inert biological prosthesis. The allograft has the advantage of offering a biological surface for the cells of the host allowing a true consolidation, although it is only partial (osteoconductive) Delloye (4). Infections, pathological fractures, and pseudoarthrosis are not uncommon as complications and require frequent re-surgeries (Table 1). Infection of an allograft results from an initial bacteraemia. It can occur during a minor surgery (autograft for example) Delloye (4). In our series, the prevalence of infection was 20%. This number is comparable to those found by other series of similar sizes (Table 2). It seems that there is a relationship between high infection rates, the importance of the length of bone resection and the use of adjuvant chemotherapy as shown by Gerhardt *et al* (16).

Table 1
Pre and post surgery data

Patient	Age (years)	AnaPath	Locali- zation	Chemo	Resection	Synthesis	Graft	Complication	Decrease
1	16	OSC	Tibia	+	Diaphysis	Nail	Frozen Allograft	0	20 years consolidation
2	46 WV	CHSC	Femur	0	Diaphysis	Nail	Frozen Allograft	0	20 years consolidation
3	48	EW	Tibia	0	Diaphysis	Nail	Frozen Allograft	Fr. Pathological Sepsis Pseudarthrosis	18 years consolidation
4	9	EW	Tibia	+	Diaphysis	Nail	Frozen Allograft	Sepsis Pseudarthrosis	17 years consolidation
5	59	CHSC	Femur	0	Diaphysis	Nail	Frozen Allograft	Fr. Pathological Judet	23 years consolidation
6	37	CHSC	Femur	0	1/3 Sup	Nail	Frozen Allograft	Pseudarthrosis Change of nail	12 years consolidation
7	23	CHSC	Femur	0	Diaphysis	Nail	Frozen Allograft	Sepsis Pseudarthrosis	10 years consolidation
8	37	CHSC	Femur	0	Femur Proximal	PTH longue queue	Frozen Allograft	Pseudarthrosis	14 years consolidation
9	53	CHSC	Femur	0	Metaphysis	Nail	Frozen Allograft	Osteolysis Judet	26 years consolidation
10	21	EW	Femur	+	Diaphysis	Nail	Frozen Allograft	Pseudarthrosis	10 years consolidation
11	16	EW	Tibia	+	Diaphysis	Nail	Frozen Allograft	0	10 years consolidation
12	46	CHSC	Femur	0	Metaphysis	Blade Plate	Hemi allograft + FIBULA vx	0	12 years consolidation
13	33	EW	Femur	+	1/3 distal	Nail + Blade Plate	Frozen Allograft	Sepsispseudarthrosis	10 years consolidation
14	44	D. Fib	Femur	0	Diaphysis	Nail	Frozen Allograft	0	
15	26	EW	Femur	0	Diaphysis	Nail		0	

Anapath = Anatomopathology; Chemo = Chemotherapy; OSC = Osteosarcoma; CHSC = Chondrosarcoma; EW = Sarcoma of EWING; Allog = Allograft; D Fib = Fibrous dysplasia

Table 2
Results of the literature

Series	Case	Average decrease in months	Type of graft	Pseudoarthrosis (%)	Sepsis (%)	Fracture (%)	Local recidivism
Khattak <i>et al</i> (13)	12	49	Autoclaved massive allograft	8	41	0	16
Suqiura <i>et al</i> (14)	15	48	Autoclaved massive allograft	14	13	13	0
Uyttendaele <i>et al</i> (15)	15	60	Massive irradiated autograft	6	13	?	13
The series	15	132	Frozen massive allograft	53.3	20	13.3	0

Allog = Allograft

On the hand, our rate of pseudoarthrosis (53.3%) is high compared to the rates presented by comparable series (Table 2). Pseudoarthrosis is the most common complication. It is favoured by an important mechanical stress, the length of the graft, the realization of an arthrodesis, a fixation with little rigidity and an interosseous distance greater than 3mm (Figure 4). Finally, pseudoarthrosis appears more frequent in patients treated with chemotherapy (17).

Pseudoarthrosis is less frequent in children. The important of pseudoarthrosis in our series can be explained first, by the length of the intercalary allograft (an average bone resection length of 330 mm), second, by the existence of inter-osseous distance of at least 3mm in our patients, and finally by the fact that we have recorded the consolidation delays in the cases of pseudoarthrosis. In our series, 3 patients who suffered from pseudoarthrosis received chemotherapy.

Fracture remains an unpredictable complication. It is progressive in most cases, going from a crack to a real discontinuity (4). We recorded 2 cases (13.3%) of allograft fracture in 15 cases. Treatment of these fractures did not require replacement of the intercalary allograft. This result is favourably comparable with the results of the authors (Table 2). The length of the resection, the type of graft and the type of osteosynthesis has been reported to be associated with the risk of secondary graft fracture (12,18). Osteosynthesis by plates or by

intramedullary nail are fewer purveyors of fractures than those by isolated screws (12,19,20).

Concerning osteolysis, we recorded 3 cases (20%) with osteolysis, without repercussions on the process of integration of the graft. There are few publications on osteolysis, maybe because of its rarity. Osteolysis, delayed incorporation, and bone erosion are other disadvantages of intercalary allografts.

The re-surgeries for pseudoarthrosis and infection are frequent and we recorded a total of 20 re-surgeries to obtain the consolidation of the 15 intercalary allografts. The patients should be informed of these constraints related to a therapeutic necessity.

CONCLUSION

This surgery of reconstruction by intercalary allograft poses a double challenge: the first is mechanical because the osteosynthesis must ensure an assembly sufficiently solid to avoid the failure of the reconstruction and the second challenge is biological namely consolidation and integration with the recipient bone. This procedure is common in orthopaedic surgery, it is a treatment of choice where there is loss of large and circumferential portion of the long bones. But the practice of this surgery requires a high level of sanitary safety, and an optimal experience with the technique.

REFERENCES

1. Harris, I.E., Leff, A.R., Gitelis, S. and Simon, M.A. Function after amputation, arthrodesis or arthroplasty for tumours about the knee. *J Bone Joint Surg Am.* 1990; **72**:1477-85.
2. Rougraff, B.T., Simon, M.A., Kneisl, J.S., Greenberg, D.B. and Mankin, H.J. Limb salvage compared with amputation for osteosarcoma of the distal end of the femur. A long-term oncological, functional, and quality-of-life study. *J Bone Joint Surg Am.* 1986; **76**:649-656.
3. Simon, M.A., Aschliman, M.A., Thomas, N. and Mankin, H.J. Limb-salvage treatment versus amputation for osteosarcoma of the distal end of the femur. *J Bone Joint Surg Am.* 1986; **68**:1331-37.
4. Delloye C. Bilan et perspectives des allogreffes massives après 25 ans d'utilisation. e-mémoires de l'Académie Nationale de Chirurgie. 2010; **9** (2): 48651.
5. Cara, J.A., Laclériga, A. and Cañadell, J. Intercalary bone allografts. Twenty-three tumour cases followed for 3 years. *Acta Orthop Scand.* 1994; **65**:42-46.
6. Mnaymneh, W., Malinin, T.I., Lackman, R.D., Hornicek, F.J. and Ghandur-Mnaymneh. Massive distal femoral osteoarticular allografts after resection of bone tumours. *Clin Orthop Relat Res.* 1994; **303**:103-115.
7. San-Julian, M. and Cañadell, J. Fractures of allografts used in limb preserving operations. *Int Orthop.* 1998; **22**:32 - 36.
8. Donati, D., Di Liddo, M., Zavatta, M., Manfrini, M., Bacci, G., Picci, P., *et al.* Massive bone allograft reconstruction in high-grade osteosarcoma. *Clin Orthop Relat Res.* 2000; **377**: 186 -194.
9. Harris, I.E., Leff, A.R., Gitelis, S. and Simon, M.A. Function after amputation arthrodesis, or arthroplasty for tumours about the knee. *J Bone Joint Surg Am.* 1990; **72**:1477 - 85.
10. Rougraff, B.T., Simon, M.A., Kneisl, J.S., Greenberg, D.B. and Mankin, H.J. Limb salvage compared with amputation for osteosarcoma of the distal end of the femur. A long-term oncological, functional, and quality-of-life study. *J Bone Joint Surg Am.* 1994; **76**:649 - 656.
11. Simon, M.A., Aschliman, M.A., Thomas, N. and Mankin, H.J. Limb-salvage treatment versus amputation for osteosarcoma of the distal end of the femur. *J Bone Joint Surg Am.* 1986; **68**:1331 - 37.
12. Brunet, O., Anract, P., Bouabid, S., Babinet, A., Dumaine, V., Tomeno, B. and Biau, D. Reconstruction des pertes de substances intercalaires après résection des tumeurs osseuses primitives du fémur et du tibia: à propos d'une série de 13 cas. *RCO et traumatologique.* 2011; **97**: 500 - 508.
13. Khattak, M.J., Umer, M., Haroon-ur-Rasheed and Umar, M. Autoclaved tumour bone for reconstruction: an alternative in developing countries. *Clin Orthop Relat Res.* 2006; **447**:138 - 144.
14. Sugiura, H., Takahashi, M., Nakanishi, K., Nishida, Y. and Kamei, Y. Pasteurized intercalary autogenous bone graft combined with vascularized fibula. *Clin Orthop Relat Res.* 2007; **456**:196 - 202.
15. Uyttendaele, D., De Schryver, A., Claessens, H., Roels, H., Berkvens, P. and Mondelaers, W. Limb conservation in primary bone tumours by resection, extracorporeal irradiation and re-implantation. *J Bone Joint Surg Br.* 1988; **70**:348 - 353.
16. Gebhardt, M.C., Flugstad, D.I., Springfield, D.S. and Mankin, H.J. The use of bone allografts for limb salvage in high-grade extremity osteosarcoma. *Clin Orthop Relat Res.* 1991; **70**:181 -196.
17. Ozaki, T., Hillmann, A., Bettin, D., Wuisman, P. and Winkelmann, W. Intramedullary, antibiotic-loaded cemented, massive allografts for skeletal reconstruction. Twenty-six cases compared with 19 uncemented allografts. *Acta Orthop Scand.* 1997; **68**:387 - 391.
18. Enneking, W.F., Eady, J.L. and Burchardt, H. Autogenous cortical bone grafts in the reconstruction of segmental skeletal defects. *J Bone Joint Surg Am.* 1980; **62**:1039 - 58.
19. Kreig, A.H., Davidson, A.W. and Stalley, P.D. Intercalary femoral reconstruction with extracorporeal irradiated autogenous bone graft in limb-salvage surgery. *J Bone Joint Surg Br.* 2007; **89**:366 - 371.
20. Araki, N., Myoui, A., Kuratsu, S., Hashimoto, N., Inoue, T., Kudawara, I., *et al.* Intraoperative extracorporeal autogenous irradiated bone grafts in tumour surgery. *Clin Orthop Relat Res.* 1999; **368**:196 - 206.
21. Vichard, P. and Cagneux, E. Traitement chirurgical des tumeurs des os. Encyclopédie médico-chirurgicale appareil locomoteur (5). Elsevier SAS. 2001; **14**; 701.