

FUNCTIONAL OUTCOME AND QUALITY OF LIFE AFTER SURGICAL MANAGEMENT OF DISPLACED ACETABULAR FRACTURES IN TANZANIA

E.N. Eliezer, MD, **B. Haonga**, MD, **F.S. Mrita**, MD, Muhimbili Orthopaedic Institute, Dar es Salaam, Tanzania, **M.B. Liu**, AB, Stanford University School of Medicine, Stanford, California, USA and **H. Wu**, BA, Institute for Global Orthopaedics and Traumatology, University of California San Francisco, California, USA

Correspondence to: Dr. Billy T. Haonga, Muhimbili Orthopaedic Institute, Dar es Salaam, Tanzania.
Email: ndalama@yahoo.com

ABSTRACT

Objective: To determine the functional outcome and quality of life of acetabular fracture patients treated operatively with open reduction and internal fixation.

Design: Retrospective case series.

Subjects: Patients aged 18 to 65 years old undergoing operative treatment for acetabular fractures from October 2010 to September 2014.

Study area: Muhimbili Orthopaedic Institute, Dar es Salaam, Tanzania.

Outcome measures: Modified Merle d'Aubigne scale and "Squat and Smile" test for functional outcome. EQ-5D for quality of life.

Results: Thirty four patients were followed-up for an average of 34 months postoperatively. Patients most commonly had elemental posterior wall fractures (59%) and were most frequently (93.8%) treated by the Kocher-Langenbeck approach. The majority of patients self-reported good to excellent scores on the Merle d'Aubigne, "no problems" on the EQ-5D, and were able to perform a full squat. Patients who were operated on >6 weeks post-injury reported lower Merle d'Aubigne (15.0 vs. 16.4, $p=0.077$) and EQ-5D (0.72 vs. 0.92, $p=0.015$) scores compared to patients operated on <6 weeks since injury. Two patients reported infection and five reported avascular necrosis, four of which required hip replacements.

Conclusions: Operative treatment of acetabular fractures, particularly posterior approaches for elemental posterior wall approaches, can lead to good outcomes with acceptable complication rates at a busy trauma center in East Africa. Operating on patients less than six weeks after injury leads to better functional outcome. Future investigation into anterior and extensile approaches performed in a LMIC hospital is warranted.

INTRODUCTION

The treatment of displaced acetabular fractures continues to be a major challenge in Low-and-Middle Income Countries (LMICs). Non-operative traction is the primary method of treatment for most of sub-Saharan Africa. This is primarily due to inadequate infrastructure and limited surgical expertise which prevent development of and access to adequate surgical care (1).

While much evidence exists to support the use of operative management of acetabular fractures, the majority of these studies were conducted in High-Income Countries (HICs) and their results may not be generalizable to LMICs (2-7). Issues such as low quality fracture reductions, limited surgical expertise, and delayed time to surgery have all been shown to be important prognostic factors for poor clinical outcome (3,6-10). These factors may affect outcomes more in LMICs (3,6-10).

The modified Merle d'Aubigné clinical hip score is a widely accepted clinical grading system

for evaluating the outcomes of acetabular fracture treatment (10). It has been shown to be negatively affected by the quality of reduction, presence of associated injuries, initial fracture displacement of >20mm, joint dislocation, and delays in surgery. Other factors such as age, gender, fracture type, and length of follow-up have been shown not to have an effect on clinical outcomes (11).

We present our early experience and outcomes associated with operative treatment of acetabular fractures in Dar es Salaam, Tanzania using the modified Merle d'Aubigne scale and EQ-5D, a validated health-related quality-of-life survey.

MATERIALS AND METHODS

This was a retrospective case series study conducted from October 2010 to September 2014 at Muhimbili Orthopaedic Institute (Dar es Salaam, Tanzania). All patients with displaced acetabular fracture treated with Open Reduction and Internal Fixation (ORIF) were identified using hospital records. Initial radiographic

images performed were reviewed and classified using the Letournel classification. Trained research coordinators assisted with data collection. The principal investigator (ENE) was responsible for surgically treating all cases.

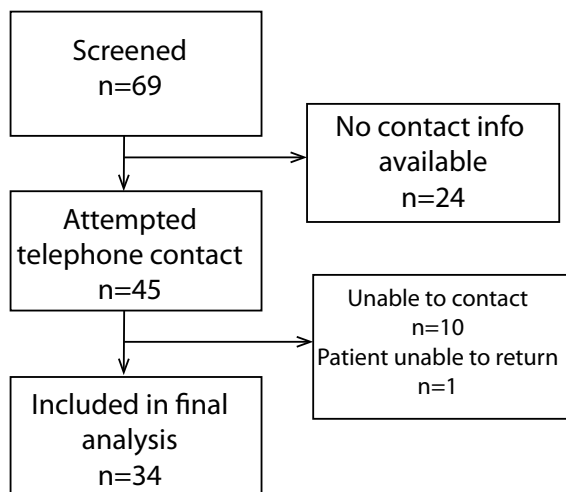
Patients who could be contacted by through hospital chart information were invited for a follow-up visit that was a minimum of one-year post-operation. At time of follow-up, patients received radiographic imaging and were clinically evaluated using the Merle d'Aubigne scale. Patients were also asked to perform a Squat and Smile test and complete an EQ-5D quality-of-life questionnaire. Descriptive statistics and two-tailed Student's T-Test were utilized to assess the data.

RESULTS

A total of 69 patients with acetabular fractures were operatively treated from October 2010 to September 2014 (Figure 1). Twenty four of these patients had no contact information recorded in their charts. Among the 45 patients who were contacted by telephone, 10 were not reachable and 1 was not available to return for a follow-up visit. Thirty four patients were available for follow-up at a minimum of one year and included in the final analysis. Average follow up was 34 months (range: 14-55).

Figure 1

Flowchart depicting the number of patients who were screened, contacted, and included in the final data analysis.



The mean age for the 34 patients was 34.2±11.6 (range: 18-61) (Table 1). Twenty five (73.5%) were males and 9 (26.5%) were females. 85.3% of injuries were caused by road traffic accidents. Other etiologies included 2 (5.9%) assaults and 3 (8.8%) falls from height.

Table 1

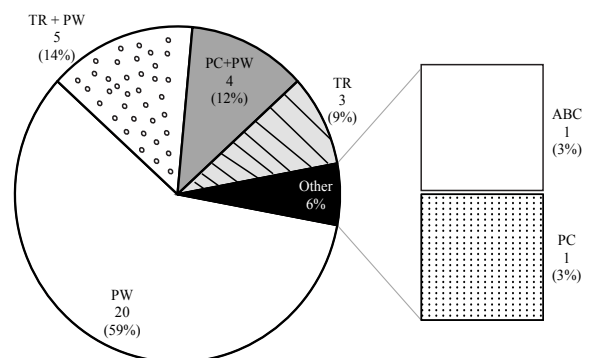
Patient demographics and mechanism of injury

Variable	Frequency	(%)
Age group (years)		
18-29	14	41.2
30-39	11	32.4
40-49	4	11.8
50-59	3	8.8
60-69	2	5.6
Gender		
Female	9	26.5
Male	25	73.5
Mechanism		
MVC (Driver)	9	26.5
MVC (Passenger)	8	23.5
MVC (Pedestrian)	3	8.8
Motorcycle	9	26.5
Fall	3	8.8
Assault	2	5.9

There were 24 (70%) elementary acetabular fractures as defined by the Letournel classification system (Figure 2), the vast majority of which had a posterior wall fracture (94%) with or without column involvement. The other 10 patients presented with associated acetabular fractures. Among these patients, 4 had concomitant femoral head fractures and 1 patient had impaction of the acetabulum. Fourteen patients with posterior wall acetabular fractures also had a posterior hip dislocation which was not reduced until the time of surgery.

Figure 2

Pattern of acetabular fracture

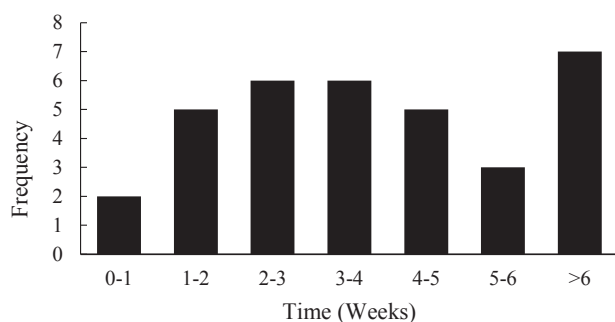


PW = Posterior Wall, PC = Posterior Column, TR = Transverse, ABC = Associated Both Column, PC = Posterior Column

Table 2*Surgical approaches and their frequencies*

Surgical approach	Frequency	(%)
Acetabular reconstruction	30	88.2
Kocher-Langenbach		
Iliioinguinal	1	2.9
Modified Stoppa	1	2.9
Total hip replacement	2	5.9

Median time from injury to surgery was 26 days (range: 2-170) (Figure 3). Thirteen (38.2%) patients were fixed within three weeks of injury. The approach used for the vast majority of patients (88.2%) was Kocher-Langenbeck (Table 2). One patient was treated using an ilioinguinal approach. Another patient was treated using the modified Stoppa technique. Two received total hip replacements.

Figure 3*Time from injury to treatment*

The average Merle d'Aubigne score was 16.1 ± 2 at the time of last follow-up (Table 3). Twenty five (73.5%) patients had good or excellent scores. Eight patients with associated acetabular fractures had scores greater than or equal to 15 (good or excellent outcomes) (Table 4). Posterior wall acetabular fractures with dislocation of the hip joint together with femoral head impaction fractures had scores ≤ 14 (poor or fair outcomes). Patients operated on within six weeks of injury (early operative group) had a mean score of 16.4 ± 0.4 while those operated on after six weeks (late operative group) averaged 15 ± 0.6 ($p=0.077$) (Table 5).

Table 3*Summary of functional outcomes and quality of life*

Measure	Outcome
Merle d'Aubigne Hip Score, mean (SD)	16.1 (2)
EQ5D Index, mean (SD)	0.876 (0.201)
EQ5D VAS, mean (SD)	85.2 (15.4)
Squat and Smile, no. (%)	
Full squat	25 (73.5)
Squat with difficulty	6 (17.7)
Unable to perform	3 (8.8)

Table 4*Modified Merle d'Aubigne functional outcome scores according to fracture pattern*

Fracture pattern	No.	Modified Merle d'Aubigne			
		Excellent	Good	Fair	Poor
Associated Both-Column	1	1	-	-	-
Posterior Column	1	-	1	-	-
Posterior Wall (PW)	3	1	2	-	-
PW + Dislocation	14	5	5	3	1
PW + Posterior Column	4	3	1	-	-
PW + PKIN III	3	-	-	3	-
Transverse (TR)	3	2	1	-	-
TR + PW	5	1	2	2	-
Total	34	13	12	8	1

The mean EQ-5D Index and Visual Analogue Scale (VAS) overall health scores were 0.876 (SD 0.201) and 85.2 (SD 15.4), respectively (Table 3). 73.5% of patients were able to fully perform the Squat and Smile test. Eighty percent of patients in the early operative group were able to successfully perform the Squat and Smile test, but only 50% of those in the late group could complete the test ($p=0.1$). Patients who were operated on within six weeks of injury reported significantly better EQ5D scores (0.92) than patients who were operated >6 weeks after the injury (0.72, $p=0.015$) (Table 5).

Table 5

Comparison between early (<6wk post-injury) and late operative (>6wk) groups

Variable	Operative Group		P-value
	Early (<6wk)	Late (>6 wk)	
Merle d' Aubigne Score (Mean \pm SD)	16.4(0.4)	15(0.6)	0.077
EQ-5D Index (Mean \pm SD)	0.92(0.03)	0.72(0.08)	0.015
Full Squat	20(80%)	4(50%)	0.1

Postoperative complications included deep infections (2 patients) and Avascular Necrosis (AVN) of the femoral head (5 patients). Four of the five patients with avascular necrosis required total hip replacement. The two who had deep infections were taken to the operating room for surgical debridement. The wound was left open and negative pressure wound therapy was applied, which led to both patients healing successfully.

DISCUSSION

This study found open reduction and internal fixation of acetabular fractures to be an appropriate treatment method in a resource limited setting. Most patients recovered with restored function and reported good to excellent outcomes. As multiple studies have illustrated, the congruency of articular surface in displaced acetabular fractures highly correlates with functional outcomes (6,12-14). This operative technique allows for the most optimal anatomical reduction to be achieved.

Posterior wall acetabular fractures were the most common types of acetabular fractures that presented to our center during the study period. These fractures were almost always associated with transient posterior dislocation of the femoral head. This combination of fractures was found to possibly be associated with an increased risk of femoral head cartilage damage and avascular necrosis. Such a finding which is similar to other studies conducted in both developed and developing countries (1,4,9, 15-17).

The Kocher-Langenbeck approach was the most common surgical approach used for the patients in this study. It was found to be a suitable technique for the pattern of fractures presenting to our center. Similar findings were found in another study published in India (1). The other approaches (Ilioinguinal and modified Stoppa) were performed depending on the nature of the fracture.

Delays in treatment significantly led to poor self-reported functional outcomes and quality of life. Regardless of the fracture pattern, those who were operated on within six weeks had higher modified Merle d'Aubigne and EQ-5D scores than those who were operated on after six weeks.

The incidence of surgical site infections found in this study (5.9%) is slightly lower than what was presented in a similar study conducted in a developing setting but is still higher than those reported from developed countries (1,4,17,18). AVN is another major concern in these types of operations. 14.7% of patients in this study were found to have developed AVN in this study; which matches the range AVN incidence reported in the literature 3% to as high as 53% (10,19). Posterior wall acetabular fractures with dislocation or impaction of the femoral head have a high risk for developing AVN (3,4,10,11,14-17,19). Limited surgical expertise also contributes to higher risk (1-3,11,15,16). Much consideration must be given to quickly identifying and treating these complications.

This study is limited by the relatively small sample size. A larger number of patients would have helped us recognize the specific types of fractures that lead to poor outcomes. Additionally, patients were operated on by a single surgeon at one study center. Results may be different with other surgeons or at other institutions. Despite these limitations, this report provides initial evidence that operative management of acetabular fractures can lead to reasonable outcomes in a low resource environment provided the surgeon has adequate knowledge and experience.

There are many difficulties associated with operative management of displaced acetabular fractures in LMICs such as Tanzania, including a limited number of implants, few surgical instruments and a lack of surgical expertise. Furthermore, there are few studies conducted in LMICs which investigate outcomes and optimal surgical techniques in resource limited settings. Still, the increasing numbers of high velocity blunt trauma in most of these countries justifies the need for adoption of effective operative procedures in order to manage the rising burden of traumatic injuries (1).

CONCLUSIONS

Operative treatment for displaced acetabular fracture lead to satisfactory functional outcomes despite limited resources. Similar outcomes may be achievable in other LMICs particularly if effort is made to providing treatment early.

REFERENCES

- Gupta, R.K., Singh, H., Dev, B., Kansay, R., Gupta, P. and Garg, S. Results of operative treatment of acetabular fractures from the Third World- how local factors affect the outcome. *Int Orthop*. 2009; **33**:347-352.
- Judet, R., Judet, J. and Letournel, E. Fractures of the acetabulum: classification and surgical approaches for open reduction: preliminary report. *J Bone Joint Surg Am*. 1964; **46**:1615-46.
- Matta, J.M. Fractures of the acetabulum: accuracy of reduction and clinical results in patients managed operatively within three weeks after the injury. *J Bone Joint Surg Am*. 1996; **78**:1632-1645.
- Rommens, P.M., Broos, P.L., Vanderschot, P. Preparation and technique for surgical treatment of 225 acetabulum fractures: 2 year results of 175 cases. *Unfallchirurgie*. 1997; **100**:338-348.
- Rice, J., Kaliszzer, M., Dolan, M., *et al*. Comparison between clinical and radiological outcome measures after reconstruction of acetabular fractures. *J Orthop Trauma*. 2002; **16**: 82-86.
- Mears, D.C., Velyvis, J.H. and Chang, C.P. Displaced acetabular fractures managed operatively: indication of outcome. *Clin Orthop Relat Res*. 2003; **407**:173-186.
- Murphy, D., Kaliszzer, M., Rice, J., *et al*. Outcome after acetabular fracture. Prognostic factors and their inter-relationships. *Injury*. 2003; **34**:512-517.
- Liebergall, M., Mosheiff, R., Low, J., *et al*. Acetabular fractures. Clinical outcome of surgical treatment. *Clin Orthop Relat Res*. 1999; **366**:205-216.
- Chiu, F.Y., Chen, C.M. and Lo, W.H. Surgical treatment of displaced acetabular fractures- 72 cases followed for 10(6-14) years. *Injury*. 2003; **31**:181-185.
- Moed, B.R., WillsonCarr SE, Watson JT. Results of operative treatment of fractures of the posterior wall of the acetabulum. *J Bone Joint Surg Am*. 2002; **84**:752-758.
- Meena, U.K., Tripathy, S.R., Sen, R.K., Aggarwal, S. and Behera, P. Predictors of postoperative outcome for acetabular fractures. *Orth Traumatol Surg Res*. 2013; **99**(8):929-935.
- Estrems-Diaz, V., Hernandez-Ferrando, L. and Balaguer-Andres, J. Acetabular fractures: short term results. *Rev Esp Cir Ortop Traumatol*. 2012; **56**(1):17-23.
- Dunet, B., Tournier, C. and Billaud, A. Acetabular fracture: long-term follow-up and factors associated with secondary implantation of total hip arthroplasty. *Orthop & Traumatol Surg Res*. 2013; **99**:281-290.
- Johnson, E.E., Matta, J.W., Mast, J.W. and Letournel E. Delay reconstruction of acetabular fractures 21-120 days following injury. *Clin Orthop Relat Res*. 1994; **305**:20-30.
- El-khadrawe, T.A., Hammad, A.S. and Hassaan A.E. Indicators of outcome after internal fixation of complex acetabular fractures. *Alex J Med*. 2012; **48**:99-107.
- Gansslen, A., Steinke, B. and Krettek, C. Internal fixation of acetabular posterior wall fractures. *Oper Orthop Traumatol*. 2009; **21**(3):283-295.
- Kumar, A., Shah, N.A., Kershaw, S.A. and Clayson, A.D. Operative management of acetabular fracture: a review of 73 fractures. *Injury*. 2005; **36**(5): 605-612.
- Pavelka, T. and Houcek, P. Complications associated with the surgical treatment of acetabular fracture. *Acta Chir Orthop Traumatol Cech*. 2009; **76**(3):186-193.
- Matta, J.M., Anderson, L.M. and Epstein, H.C. Fracture of the acetabulum. A retrospective analysis. *Clin Orthop*. 1986; **205**:230-240.