

EARLY EXPERIENCE OF OPERATIVE TREATMENT OF PELVIC AND ACETABULAR FRACTURES AT A UNIVERSITY TEACHING HOSPITAL IN KENYA

P. K. Oroko, MMed (Surg), FRCS (Ed. & Eng), FRCS (Tr. & Orth), Aga Khan University Hospital, 3rd Parklands Avenue, P.O. Box 30270- 00100, Nairobi, Kenya. Email: parmenas.oroko@aku.edu

ABSTRACT

Background: There is a large number of patients who sustain pelvic and acetabular fractures in Kenya. A number of these patients have undergone internal fixation at our institution but there is no local data to show the results of such treatment.

Objective: To review early post-operative results of pelvic and acetabular fracture internal fixation.

Design: Retrospective case series.

Methods: Case records and X-rays of all the patients who had undergone internal fixation of their pelvic and acetabular fractures over a two year period were reviewed. Information regarding operative time, post-operative complications and wound healing, level of pain, function and return to work was recorded. X-ray were reviewed for reduction, bone healing, hetero-topic ossification and avascular necrosis for acetabular fractures.

Results: Over a period of 2 years the author has carried out 11 pelvic and acetabular reconstructions. The reconstructions took a significant amount of time due to setting up, image intensifier fluoroscopy, lack of appropriate equipment for fracture reduction and fixation. Nine of the patients had a good result. Ten of the patients had returned to their previous work.

Conclusion: Internal fixation of pelvic and acetabular fractures leads to good patient outcomes. There is, however, need to invest in facilities to accomplish the fixations timeously and in special training for the surgeons to carry out the procedures safely.

Key words: Pelvic and acetabular fractures, Operative treatment, Outcome

INTRODUCTION

The incidence of pelvic and acetabular fractures in the UK is 3/100,000 with about half of the patients requiring operative treatment (1). At this incidence there would be at least 1200 such cases in Kenya with 600 needing operative treatment annually. This number could, however, be higher with the large number of road traffic accidents in Kenya. Conservative treatment, especially in a private hospital, is expensive as it requires prolonged immobilization and traction. Results of conservative treatment, especially for unstable fractures, are poor functionally. There is therefore, need to provide operative care for these injuries. Early operative experience in our centre is presented.

MATERIALS AND METHODS

Sequential early cases treated by the author at Aga Khan University Hospital Nairobi, a private tertiary

not for profit institution, are presented. Patients who were admitted after sustaining injuries were initially assessed and adequately resuscitated according to the Advanced Trauma Life Support (ATLS) protocol before pelvic and acetabular reconstruction was carried out. Operations were done in laminar flow theatres under image intensifier fluoroscopy. The main challenges of the procedures were identified in order to improve efficiency of subsequent operations. The main outcomes were early mobilization and discharge, fracture union and patient rehabilitation.

RESULTS

Internal fixation achieved stability and simplified nursing allowing patient movement with reduced analgesic requirements. It also allowed earlier mobilization and discharge from the ward. Results are summarized on Table 1.

Table 1
Summary of results

Case no.	Age (years)	Diagnosis	Operation	Outcome
1	28	Bilateral SI joint disruption, bilateral pubic rami fractures	Bilateral SI percutaneous cannulated screws	Good. Hardware removal- L5 nerve root impingement, returned to work
2	37	Posterior dislocation with posterior wall acetabular fracture	Screws	Good. Displacement of fragment, returned to work
3	21	Anterior column	Plating	Good
4	31	Pubic symphysis disruption with SI joint disruption	Plating pubic symphysis + cannulated SI screws	Good. Urine leak from bladder with infection and loose screws, returned to work
5	33	Pubic symphysis and SI joint disruption 5 month old	Cannulated SI screw with fusion SI joint and plating pubic symphysis	Good, returned to work as military officer
6	47	Posterior dislocation with retained acetabular bone fragment, posterior wall	Removal bone fragment with plating posterior wall	Good HIV positive, awaiting return to work
7	56	Loose THR implants with peri-prosthetic acetabular fracture transverse both column fracture	One stage revision with double plating acetabulum	Good. HIV- wound infection- responded to debridement and antibiotics, returned to work
8	45	SI joint disruption	Percutaneous SI joint screw fixation	Good, returned to work
9	58	Bi-columnar acetabular fracture	Plating, posterior column screw	Medial wall displacement, returned to work
10	20	Bi-columnar acetabular fracture	Double plating	Obturator nerve injury, returned to work, light duties
11	27	Avulsion ASIS	Screw fixation	Good, returned to work

Ten of the patients were male and the average age was 36.6 years. The acetabular and pelvic fixations took significantly longer than could be expected due to setting up time, issues with image intensifier use as we had different radiographers with different levels of experience and lack of a special pelvic tray with specific equipment like retractors and reduction clamps.

Of the 11 patients, 9 had good results. Unsatisfactory results included obturator nerve injury, with the nerve damaged by the drill bit entering obturator foramen. The nerve was not repaired. Patient had weakness of adduction, but was able to mobilize independently without pain. One patient had re-displacement of medial wall of acetabulum. He walks with a limp one year after operation, has stiffness of his hip but no pain. He awaits a total hip replacement for functional loss.

Two other patients had complications, though they had good results. One had posterior acetabular lip re-displacement following fixation with screws.

He is asymptomatic. The other had L5 nerve root impingement and required removal of screw about one year post –operatively. A third patient with pubic symphysis plating had urinary leak from the operation wound and infection around plate with one screw migration. The urinary leak was treated conservatively and resolved. Patient is now asymptomatic. There was wound infection in a HIV patient. Infection was controlled with debridement and antibiotics.

All the patients in the study returned to their work except one who has yet to do so 5 months after his injury. He is HIV positive and had wound infection in a leg laceration which took about 3 months to recover. This delayed his rehabilitation. He is expected to return to work about 7 months after injury. The majority of patients returned to their previous level of work, including one with a sacroiliac and pubic symphysis disruption operated 5 months after injury.

Figure 1

28 year old man with bilateral sacro-iliac joint dislocation and bi-lateral fracture of the pubic rami. Treated with per-cutaneous sacro-iliac screw fixation. Post-operatively analgesic requirements were reduced, nursing was easier as he could be moved with minimal pain and he was discharged home within 1 week on a wheelchair

Figure 1a:

Bilateral S.I joint dislocation

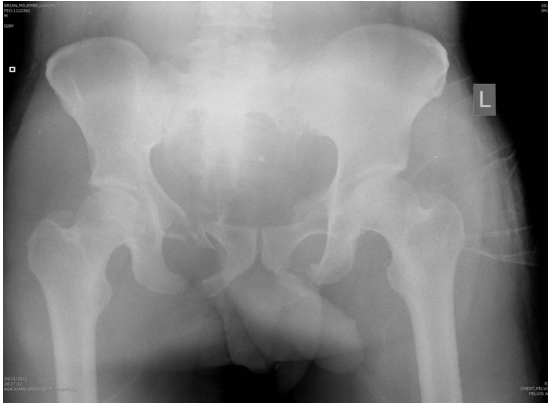


Figure 1b

Bilateral S.I per-cutaneous screw fixation

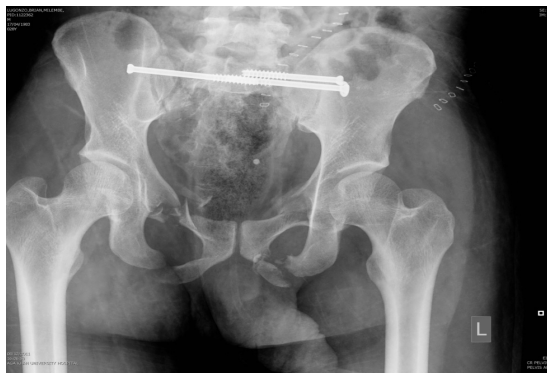

Figure 2

20 year old man with bi columnar right acetabular fracture. Treated with double plating. Sustained obturator nerve injury

Figure 2 a

20 year old. Bi-columnar acetabular fracture

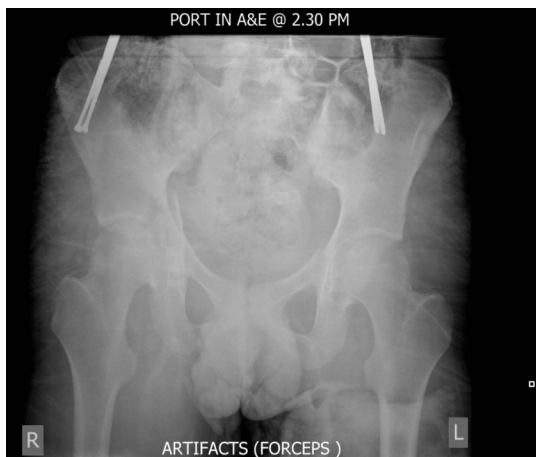
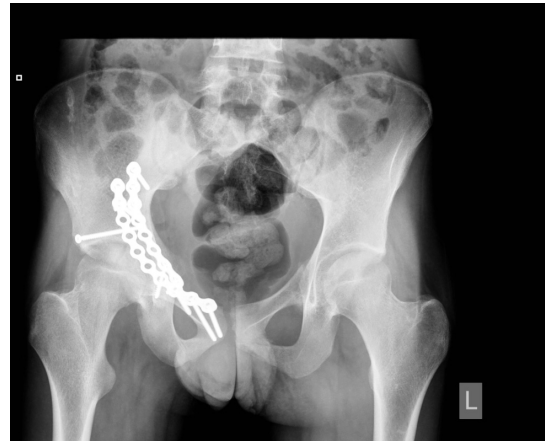
Figure 2b

Double plating



DISCUSSION

There is need to treat acetabular and pelvic fractures operatively in Kenya. Such fixation requires provision of facilities and human resources to ensure safe practice. Conservative treatment takes a long time and is expensive, especially in private hospitals. Government hospitals are also expensive but are heavily subsidized. A study at Kenyatta National Hospital (2) comparing conservative and operative costs of treatment of femoral fractures can be applied to pelvic and acetabular fractures in principle. The duration of hospitalization with conservative treatment was six times that of operative treatment and cost more. The results of treatment were, also, inferior with a higher rate of mal-union and non-union in the conservatively treated patients. The long stay required for conservative treatment, therefore, blocks valuable beds for patients requiring other orthopaedic treatment.

Most of the patients who sustained pelvic and acetabular fractures in this study were young and a bad result would affect their ability to return to work. Operative treatment of the displaced acetabular and pelvic injuries significantly helped in-patient rehabilitation. Displaced fractures should be treated operatively as this is the standard of care established internationally (3,4). However, this is not usually offered in developing countries because of lack of infrastructure, non-availability of skilled services, delayed referrals from peripheral units because of associated injuries, economic constraints and patients' unwillingness to undergo surgery (5). While conservative treatment of acetabular fractures may result in good function if congruent reduction is achieved, displaced fractures are better treated operatively (6). Unstable pelvic ring fractures, however, result in poor outcomes with conservative treatment and should be treated operatively (7).

The challenge for Kenya and the East African region is to provide operative care for these complex

injuries. Such treatment will require having centres with specially trained orthopaedic trauma surgeons which are adequately resourced with special operating sets and image intensifiers. Such centres will develop the care for such injuries regionally for the improvement of patient outcomes.

REFERENCES

1. Laird, A. and Keating, J.F. Acetabular fractures. A 16 - year prospective epidemiological study. *J Bone Joint Surg Br.* 2005; **87-B(7)**: 969-973.
2. Kamau, D.M., Gakuu, L.N., Gakuya, E.M. and Sang, E.K. Comparison of closed femur fracture: Skeletal traction and intra-medullary nailing cost-effectiveness. *East Afr Orthop J.* 2014; **8**: 4-9.
3. Matta, J.M. Fractures of the acetabulum: accuracy of reduction and clinical results in patients managed operatively within 3 weeks after injury. *J Bone Joint Surg Am.* 1996; **78**: 1632-1645.
4. Giannoudis, P.V., Grotz, M.R., Papakostidis, C. and Dinopoulos, H. Operative treatment of displaced fractures of the acetabulum. A meta-analysis. *J Bone Joint Surg Br.* 2005; **87**: 2-9.
5. Sen, R.K. and Veerappa, L.A. Long-term outcome of conservatively managed displaced acetabular fractures. *J Trauma.* 2009; **67(1)**: 155-159.
6. Magu, N.K., Rohilla, J. and Arora, S. Conservatively treated acetabular fractures: A retrospective analysis. *Indian J Orthop.* 2012; **46(1)**: 36-45.
7. Fell, M., Meissner, A. and Rahmzadeh, R. Long-term outcome after conservative treatment of pelvic ring injuries and conclusions for current management. *Zentralbl Chir.* 1995; **120(11)**: 899-904.