

FIBULAR OSTEOSYNTHESIS OF NEGLECTED FEMORAL NECK FRACTURE IN A YOUNG ADULT: CASE REPORT

U.O.E. Ikeanyi, MBBS, FWACS (Ortho), FMCS (Ortho), Consultant Orthopaedic and Trauma Surgeon, Department of Surgery, Federal Medical Centre, Umuahia, Nigeria. Email: ugoikeanyi@yahoo.com.

ABSTRACT

In order to preserve the femoral head in femoral neck non-union in young adults, the preferred option of treatment is open reduction and internal fixation. Where there are no facilities for microvascular surgery, non-vascularized fibular strut grafts can be used with screws.

This paper describes the use of fibular strut graft and cancellous screws in the open reduction and internal fixation of a neglected femoral neck fracture associated with aseptic necrosis of femoral head in a young adult that was followed up for four years.

The use of non-vascularized fibular strut grafts and screws for fixation of non-united fractures of femoral necks, even in the presence of avascular necrosis, could lead to union.

Key words: Fibula, Osteosynthesis, Femoral neck, Non-union, Aseptic necrosis, Strut graft

INTRODUCTION

Femoral neck non-union in a young adult is an uncommon but serious complication both for the patient involved and in terms of management. It is usually treated operatively with several treatment options having variable success rates. One recognized treatment option is the combined use of open reduction, internal fixation with screws and non-vascularized fibular strut graft. This method is relatively easy to perform, does not require microvascular anastomosis, offsets both the biologic and biomechanical causes of non-union, contributes to the repair of any incidental avascular necrosis, and is not encumbered by the complications of intertrochanteric osteotomy like limping.

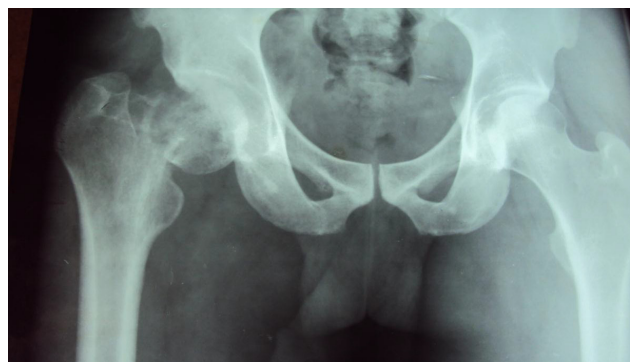This was the technique used in the current report for the subject who had a neglected femoral neck fracture and radiological evidence of aseptic necrosis of the index femoral head. His fracture healed after three months and he had no evidence of aseptic necrosis. After a follow-up of two years, he had a Harris hip score of ninety seven. The rationale behind this option is discussed and the relevant literature is reviewed. The patient gave his consent for this publication.

CASE REPORT

A 29-year-old man presented to the Accident and Emergency department of our hospital a day after he was knocked down by a motorcyclist. He sustained injury to his right hip only and could not bear weight on that hip. As soon as a diagnosis of non-displaced fracture of his right hip was made he discharged himself against medical advice and went to traditional bone setters for further management. Three months later, he came back to our out-patient clinic with a completely displaced non-united fracture of his right hip. There were femoral neck resorption and patchy sclerosis in

Figure 1

Pre-operative pelvic radiograph



the femoral head due to, probably, aseptic necrosis of the femoral head (Figure 1).

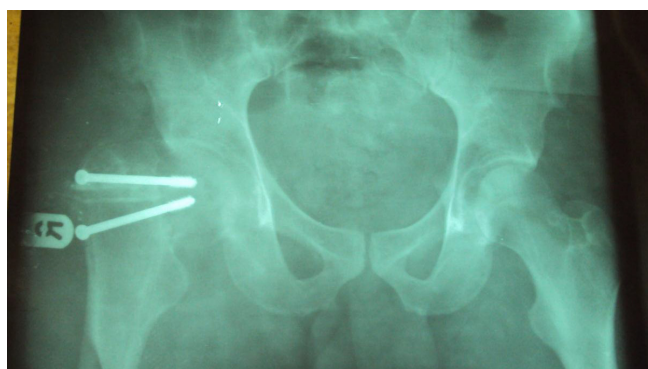
The patient had pain in his right hip, could not walk unaided, and was limping with about three centimetres shortening of his right thigh. His Harris hip score was 60. He was admitted and placed on eight kilogrammes proximal transtibial skeletal traction for nine days prior to surgery. An anterolateral approach was used to expose the right hip joint and to estimate the required length of fibular strut. Nine centimetres of the mid ipsilateral fibula was harvested subperiosteally through a lateral right leg incision. The graft was prepared by multiple drill holes along its length and nibbling of its interosseous border.

Upon exposure of the hip, fibrous tissue and cartilage were noted to be covering the fractured ends. These were curetted off to freshen the ends with the aid of Steinman pins attached to separate the greater trochanter and femoral head as joysticks. The entire neck appeared shorter than normal. A cortical window big enough to admit the graft was created on the lateral aspect of the greater trochanter and reaming was done into the femoral head. The graft was subsequently introduced into the reamed tract.

Two cancellous screws were then used to fix the fracture. Unfortunately, varus could not be prevented because of the extent of neck resorption but the construct was stable (Figure 2). The wound was closed in layers over a suction drain which was removed after forty-eight hours. One-and-a-half hip spica was applied on the fifth postoperative day and patient was discharged on the seventh day. He was advised on strict non-weight bearing.

Figure 2

Anteroposterior view showing fibular graft between two cancellous screws post fixation of neglected right hip fracture



The spica was removed after six weeks and the patient was advised to start mobilizing. Non-weight bearing on the right was assured with the use of bilateral axillary crutches for another six weeks. Serial radiographs showed progressive healing. Full-weight bearing was started about a year postoperatively when the right hip radiograph showed fracture consolidation with incorporation of the fibular strut graft.

Figure 3

Anterolateral view after removal of screws

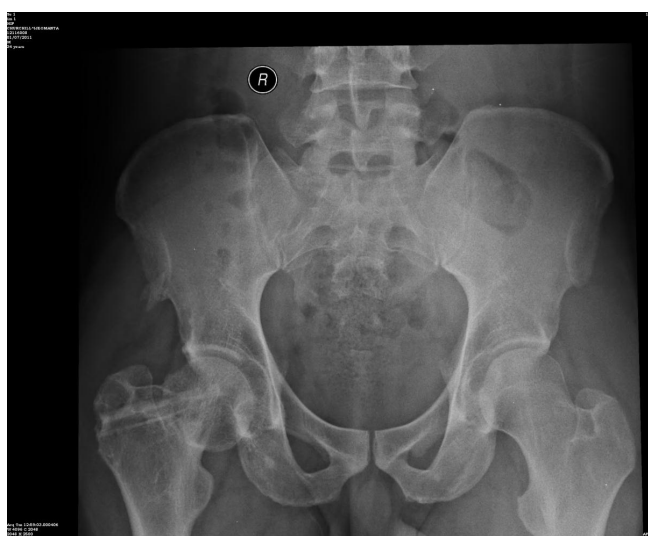
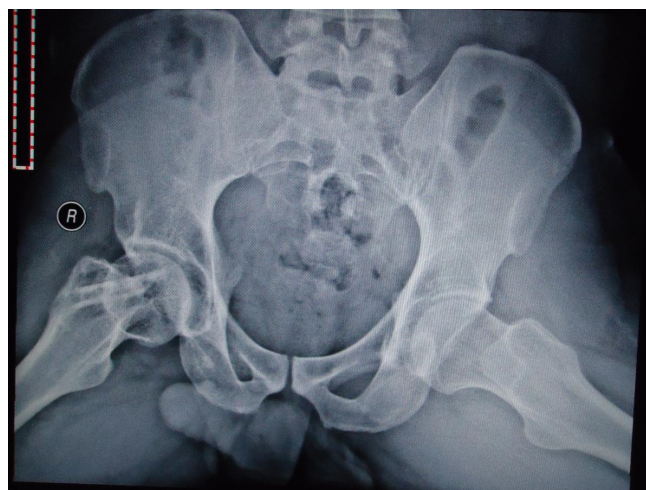
Figure 4

Frog lateral view of both femoral necks after removal of screws



Twenty-two months postoperatively, the screws were removed (Figures 3 and 4). Patient was seen in the outpatient clinic four years postoperatively and the Harris hip score was ninety-seven.

DISCUSSION

The patient whose case was presented had neglected his femoral neck fracture for three months. He then presented with an ununited femoral neck fracture and radiographic features that suggested aseptic necrosis of the ipsilateral femoral head. He was placed on a nine-day skeletal traction in order to offset the effects of contracture of hip abductors, overlap of fracture fragments and limb shortening (1). The anterolateral approach was chosen because it avoided the posterior retinacular vessels and thereby limited the damage to the blood supply to the femoral head (2). Bone graft was used to assist union and treat aseptic necrosis. It had been shown with ample evidence including experiments in dogs that cortical grafts provided structural support to the necrotic femoral head preventing its collapse and, with time, provided scaffold for revascularisation and osteogenesis along the length of the graft to the subchondral bone (3-5). By this means, union was achieved and the aseptic necrosis was treated. This had been demonstrated in recent studies (6-8). The triangular shape of the fibular strut used in this case report strengthened the immobilization of the fracture by providing rotational stability at the fracture site (6-11). Additionally two cancellous screws were used to obtain compression and more stability at the fracture site (9-11). It had been stated that the two-screw-and-fibular-strut-graft construct was sufficiently stable for

one not to use hip spica (11). However, a hip spica was used for six weeks in order to restrain the patient from bearing weight. The total period of restricted weight bearing was the time it took for union to be evident - three months. The emphasis on restricted weight bearing until obvious evidence of union has been shown to give better results (10).

In this case report, a fibular strut graft and internal fixation with two screws were chosen for the treatment of a neglected femoral neck fracture in a young adult with radiological features of aseptic necrosis of the femoral head. Union was achieved albeit with coxavarus. At four-year follow-up, there were no features of aseptic necrosis of the femoral head and his Harris hip score was 97%. The patient was told of the possibility of future osteoarthritis of the index hip and the need for regular follow-up.

In conclusion, the use of non-vascularised fibular strut grafts and screws for fixation of non-united fractures of femoral necks, even in the presence of avascular necrosis, could lead to union.

REFERENCES

1. Gupta, A. The management of ununited fractures of the femoral neck using internal fixation and muscle pedicle periosteal grafting. *J Bone Joint Surg.* 2007; **89B**: 1482-1487.
2. Trueta, J. and Harrison, M.H.M. The normal vascular anatomy of the femoral head in adult man. *J Bone Joint Surg.* 1953; **35B**:442-461.
3. Compere, E.L. and Lee, J. The restoration of physiological and anatomical function in old ununited intracapsular fractures of the neck of the femur. *J Bone Joint Surg.* 1940; **22**: 261-277.
4. Phemister, D.B. Treatment of the necrotic head of the femur in adults. *J Bone Joint Surg.* 1949; **31A**: 55-66.
5. Bonfiglio, M. and Bardenstein, M.B. Treatment by bone-grafting of aseptic necrosis of the femoral head and non-union of the femoral neck (Phemister technique) *J Bone Joint Surg.* 1958; **40A**:1329-1346.
6. Nagi, O.N., Gautam, V.K. and Marya, S.K. Treatment of femoral neck fractures with a cancellous screw and fibular graft. *J Bone Joint Surg.*1986; **68B**:387-391.
7. Nagi, O.N., Dhillon, M.S. and Goni, V.G. Open reduction, internal fixation and fibular autografting for neglected fracture of the femoral neck. *J Bone Joint Surg.* 1998; **80B**:798-804.
8. Nagi, O.N., Dhillon, M.S. and Gill, S.S. Fibular osteosynthesis for delayed type II and type III femoral neck fractures in children. *J Orthop Trauma.* 1992; **6**:306-313.
9. Elgafy, H., Ebraheim, N.A. and Bach, H.G. Revision internal fixation and nonvascular fibular graft for femoral neck nonunion. *J Trauma.* 2011;**70**: 169-173.
10. Sandhu, H.S., Sandhu, P.S. and Kapoor, A. Neglected fractured neck of the femur a predictive classification and treatment by osteosynthesis. *Clin Orthop Relat Res.* 2005;**431**:14-20.
11. Roshan, A. and Ram, S. Early return to function in young adults with neglected femoral neck fractures. *Clin Orthop Relat Res.* 2006; **447**:1.