

VARIABILITY IN OLECRANON AO FRACTURE FIXATION: A RADIOLOGICAL STUDY

V.M. Mutiso*, MBChB, MMed(Surg), FCS(ECSA), Department of Orthopaedic Surgery, College of Health Sciences, University of Nairobi, P. O. Box 19676 – 00202, Nairobi, Kenya and **J. Chigumbura**, MBBS (University of Warwick), GPST1, UHNS

**At the time of writing the author was a Clinical Fellow (Arthroscopy & Arthroplasty) in the Directorate of Orthopaedics and Trauma at the University of North Staffordshire in United Kingdom*

Correspondence to: Dr. V.M. Mutiso, Department of Orthopaedic Surgery, College of Health Sciences, University of Nairobi, P. O. Box 19676 – 00202, Nairobi, Kenya. Email: mutiso@uonbi.ac.ke

ABSTRACT

Background: Tension Band Wire(TBW) fixation of olecranon fracture is a commonly used technique by orthopaedic surgeons. However surgeons do not strictly adhere to the AO standard.

Objectives: To determine the use and variability of this technique by surgeons at the hospital.

Design: A hospital based retrospective study using anonymous radiological records.

Setting: North Staffordshire University Hospital in United Kingdom.

Materials and Methods: Computer software was used to retrieve, review and measure pre and postoperative radiographs of olecranon fracture cases. All identifying information was electronically masked.

Results: The mean age was 50.1 years with a median of 56 years. 16.9% were open fractures. Fifty percent of the TBW met the AO standard.

INTRODUCTION

Olecranon fractures are a relatively common acute injury worldwide and are commonly treated operatively. Traditionally those from the AO school of thought have treated these with parallel “K” Wire fixation and Tension Band Wiring (TBW). The recommended standard for this operative fixation is for the K wires (size 1.6mm) to engage the anterior cortex of the ulna and the cerclage (size 1.0mm) figure of eight wire to be tensioned at two sides on either side of the ulna. Many surgeons do not strictly adhere to these recommendations.

The proximal end of the Kirschner wires should be bent 180 degrees and punched flush with the proximal ulna cortex under the triceps muscle tendon. A common complication is the ‘backing out’ of these wires resulting in discomfort to the patient and a relatively high rate of secondary surgery to remove these implants. Older implants such as the 3.5 mm DCP and reconstruction plates are used by some, others opt for newer implants such as contoured low profile locking plates with self tapping screws while still others prefer to use lag cancellous screws with or without cerclage wires. Implants such as the LCDCP and contoured locking plates are increasingly being used especially for the more comminuted fractures and more so when the coronoid is involved. The options are numerous.

Anatomy: The olecranon is located at the proximal end of the ulna long bone. Fractures are often a result of direct impact following a fall. This can cause an avulsion type injury from contraction of the muscle following sudden resistance. This occurs when protecting oneself from a fall or often as part of multiple injuries in major trauma such as a fall from a height or road traffic accidents.

The triceps muscle attaches to the ulna proximally and it articulates with the distal humerus. It is subcutaneous along most of its length and is thus relatively accessible to the orthopaedic surgeons. Olecranon fractures are common and estimated to constitute up to 10% of all upper extremity lesions (1). There are many classification systems of this injury of which the Mayo is one. It is relatively simple and divides these fractures into groups based on displacement and comminution (2).

As these fractures are intra-articular, management is preferably operative to ensure accurate reduction and stabilisation with restoration of the joint surface as closely as practicable for better prospects of good long term function. A few undisplaced olecranon fractures are treated conservatively especially at the extremes of age in the paediatric and geriatric groups. Lister in 1873 used a wire loop to fix an olecranon fracture, the first to be treated by open reduction using his method of antisepsis (3).

The AO group popularised their method of open reduction and internal fixation using two parallel Kirschner wires with a figure of 8 cerclage wire and is now arguably the most widespread method of open reduction and internal fixation of this fracture (4,5). This method transforms the forces of the pull of the triceps into forces that cause compression of the fracture. This is disputed by Hutchinson *et al* (6) who was unable to demonstrate this in a cadaveric study.

It is however generally accepted that TBW of olecranon fractures gives good outcome results and some authors consider it the gold standard (1). However good tension band wiring has a high rate of minor complications such as the “K” wires backing out and causing discomfort to the patients and sometimes

resulting in infection. They also have a relatively high rate of a second operation to remove the metalwork (7).

Some authors state that engaging the K wire with the anterior cortex of the ulna reduces the rate of backing out by as much as three times in comparison with those passed down the medullary cortex (1,8). Rommens *et al* (9) disputed this and found no correlation of suboptimal placement of pins with loosening or secondary procedure.

Surgeons treat each case according to its merit and will generally tend to use plates and screws in more comminuted fractures and to use tension band wiring in simpler fractures as the reason is based on compression of the fracture. Some require bone fixation with grafting (10). Plates and screws are also an effective method (11) and have reoperation rates that tend to be lower (12) than that for tension band wiring.

The story in paediatric cases with fracture of the olecranon is much happier as they have an excellent long term outcome (13). There is a growing tendency to use bio absorbable materials in fracture fixation which reduces the need for a second operation to remove the implant (14,15). Many paediatric olecranon fractures are treated conservatively as they are less likely to displace.

Although the penetration of the anterior cortex of the ulna is advocated; it has been linked with impairment of forearm rotation (16). Overall outcomes of olecranon fractures tend to be fairly good no matter which method the surgeon uses.

The AO standard: The audit standard for tension band wiring of fractures of the olecranon was the AO method as stated in the AO manuals of fixation. There are many classifications of elbow fractures. The Mayo classification is relatively simple and assists in management decision making. Generally AO TBW is recommended for two part olecranon fractures. Surgeons use their judgement as to whether to use TBW on more comminuted types. Mason 1 and 11a are the classical indication for AO tension band wire fixation. The indications for it in olecranon fractures are two part fractures as these allow the construct to compress the fracture ends.

MATERIALS AND METHODS

A database of 100 consecutive patients diagnosed with olecranon fracture between January 2008 to June 2010 was compiled. Pre and post operative radiographs of those that had their fracture managed operatively were retrieved. All identifying stigmata on the radiographs was electronically masked rendering them anonymous. These radiographs were then studied using secure radiology computer software (Syngo computer

software) and the findings recorded. Core data included age, gender, fracture classification, type of fixation and mode of fixation.

For those that had Tension Band Wiring (TBW), bimodal data was collected using three criteria to identify variation from the standard AO technique.

- (i) Parallel K wires penetrating the anterior ulna cortex
- (ii) 180 degree bending of the proximal end of the "K" wires and placement flush with the proximal ulna cortex
- (iii) Balanced tensioning of the cerclage wire by twisting on either side of the ulna bone.

RESULTS

There were 100 cases of consecutive olecranon fractures retrieved. Nineteen (19%) were aged below 14 years and considered to be in the paediatric age group by our criteria. They were aged 3 to 92 years, with a range of 89 years. Calculated mean age was 50.1 years with a median of 56 years. Of the 100 cases only 59 satisfied the inclusion criteria and were eligible. They were aged 5 to 86 years with an age range of 81 years. The mean age of the 59 cases was 52.3 years with a median age of 56 years. The male to female ratio was 1.3:1.

Only 3 of the 59 cases were in the paediatric age group. The three were aged 5, 9 and 10 and were all male. This comprised 5% of the eligible population. Mean age was 8 years with a median of 9 years.

In the adult group there were 30 males and 26 females. Among the male cases the youngest was 16 years and the oldest 81 years old. The mean age was 39.9 years with a median of 41 years. Among the female adults the youngest was 14 years and the oldest 86 years old. The mean age was 62.1 with a median of 68 years.

Ten out of 59 (16.9%) of the fractures were open. Five of the open fractures were treated with TBW of which only one had Kirschner wires penetrating the anterior cortex of the ulna. The remaining 5 were treated with plates and screws. Four were with locking plates and screws and one was an AO semi tubular plate and screws. Of these 5 open fractures one had multiple surgeries initially with a LISS plate which was removed and an external fixation fitted across the elbow joint.

There were 49 closed fractures; of these two had a complex fixation done. One had a combination of a plate, screw and tension band wiring and the other had a reconstruction plate with screws as well as external fixator. Thus of the remaining 47 closed olecranon fractures 28 had TBW whilst 15 had some form of plates and screws (including LISS plates) and 4 had screws only.

Of the 28 who had TBW done, 14(50%) had the Kirshner wire penetrating the anterior ulna cortex. The length of the “K” wire proud of the posterior cortex of the olecranon was measured giving a range of 5.5mm minimum and a maximum of 17.1mm. No clear pattern emerged when those cases penetrating the anterior cortex were compared with those where the “K” wires were lying entirely in the medullary canal of the ulna. Measurements were taken using the Syngo computer programme on electronic images of the X-rays of the patients.

No clear pattern emerged on surgeon preference of TBW versus plating over time if one compares February to December 2008 and 2009. In 2008 there were 12 tension band wiring versus 7 platings (TBW 63.2%). In 2009 there were 18 TBW versus 13 plating (TBW 58.1%). In the period, January to June 2009 there were only 2 tension band wirings versus 5 platings which seemed to indicate an increasing preference for plating.

Figure 1

Example of mason IIA olecranon fracture

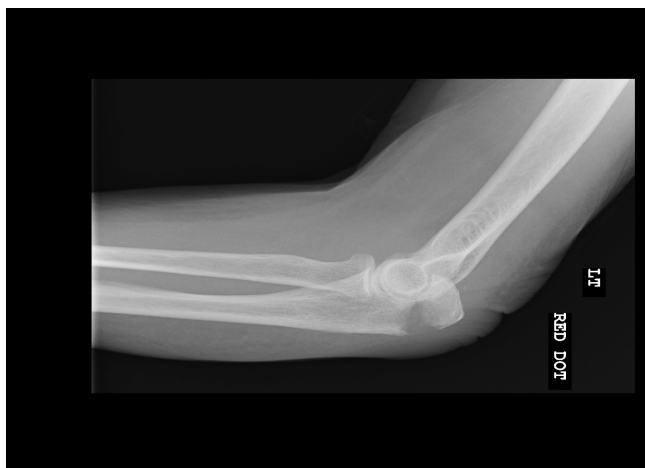

Figure 2

Non standard TBW

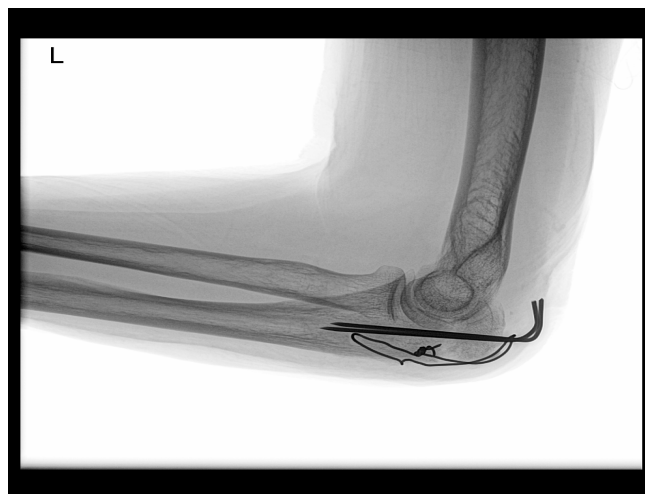
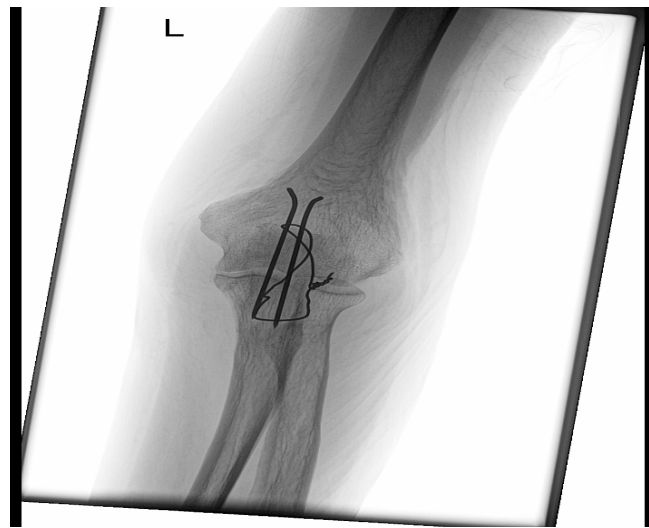


Figure 3

AP view of non standard TBW



Although no clear pattern emerges on surgeon preference of TBW versus plating over time, there is a suggestion of a tendency towards plating. The period February to December 2008 had 12 TBW versus 7 platings. January to December 2009 had 18 TBW and 13 platings. while January to June 2010 has 2 TBW and 5 platings.

It would appear that the proportion of TBW for olecranon fractures was falling. The year 2010 had twice as many platings as TBW. However the data is insufficient to draw statistically significant conclusions. The 3 paediatric patients had the following treatments: the 5 year old had a lag cancellous screw; the 9 year old had a TBW with anterior cortex of the ulna penetrated by the Kirschner wire whilst the 10 year old had a single cannulated screw with a washer. Mayo 2A was the commonest class of fracture.

Figure 4

Number of cases by Mayo classification

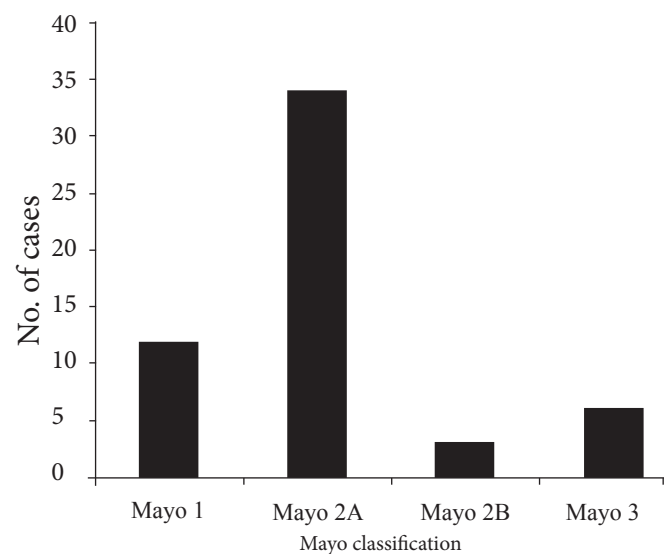


Figure 5
Method of fixation of olecranon by fracture type

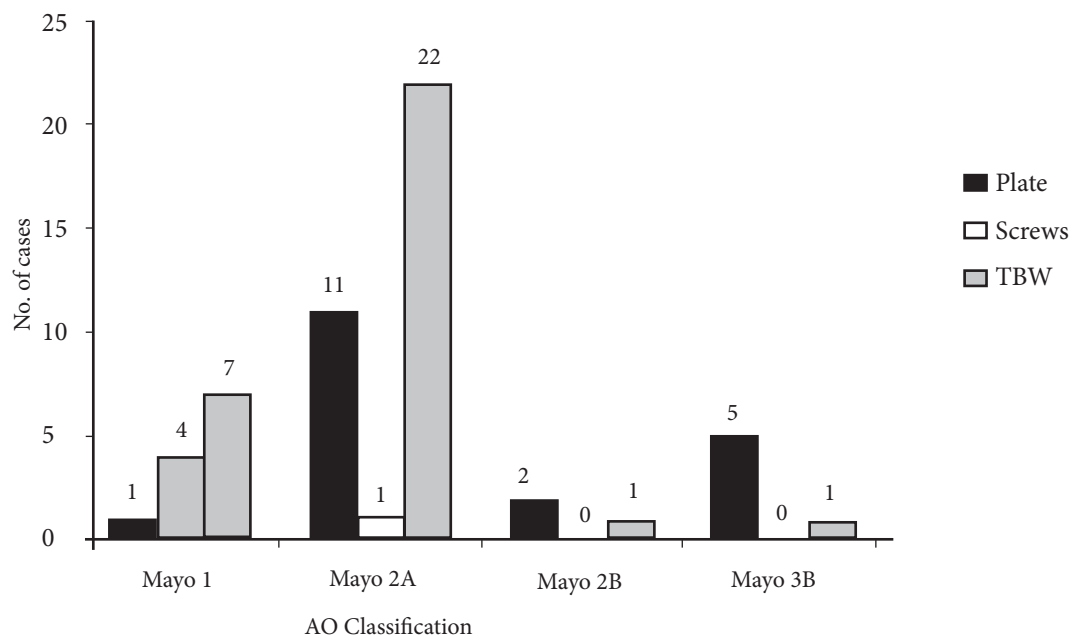
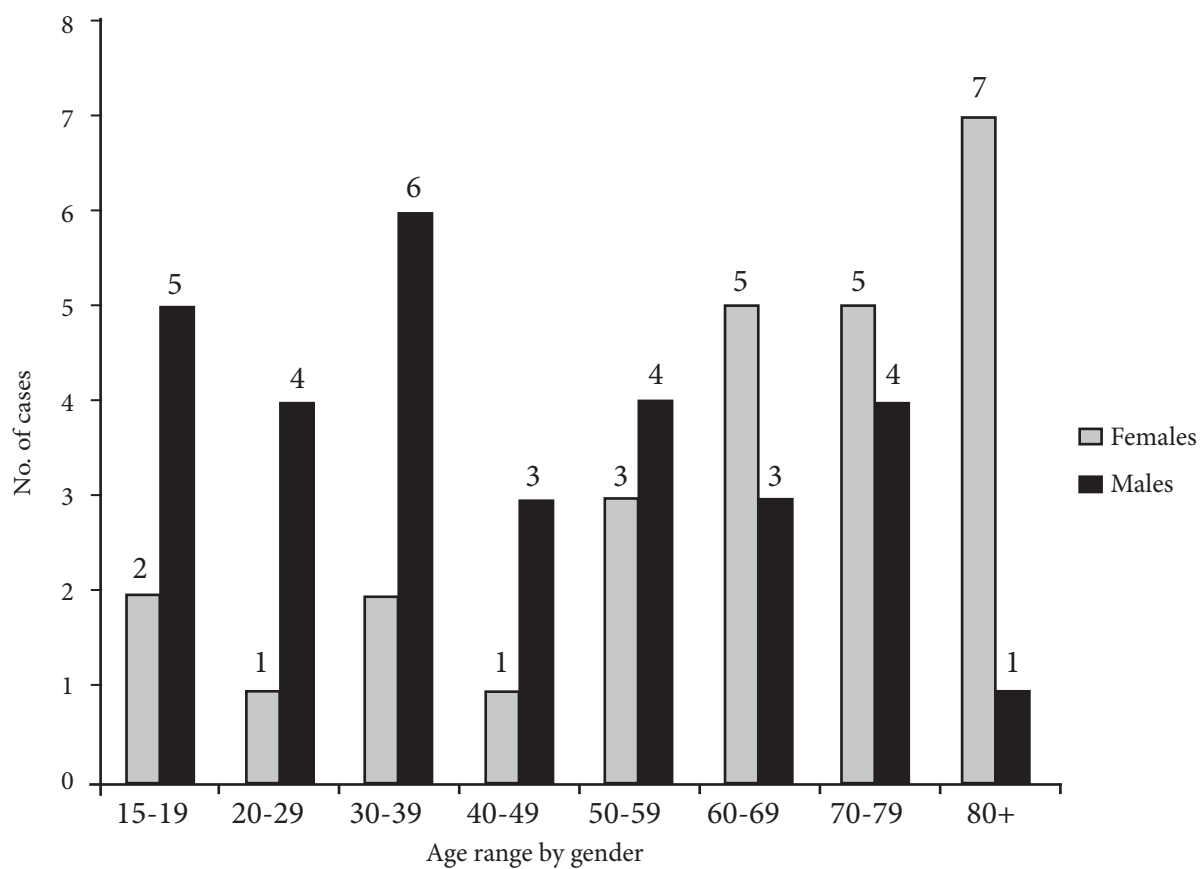


Figure 6
Age distribution by gender of fracture cases



DISCUSSION

The age and sex distribution pattern determined in this study is generally similar to that found in the literature. Chalidis *et al* (12) in his review of 62 patients found a higher prevalence of men in their 5th decade and elderly women. In this review the mean age for men was 40 years with a median of 41 whilst it was 62 and 80 years respectively for women. This is two decades later than that of men. Chalidis *et al* (12) also found the penetration of the ulna anterior cortex was perforated by at least 1 Kirshner wire in 71% of TBW patients (62.9% by two wire and 8.1% by one wire). This figure is much higher than that found in our review 38.7% (12 of 31 cases).

This would suggest that TBW is performed in the standard recommended technique in less than 1/3 of the cases undertaken. Protrusion of “K” wire at the elbow causing pain and discomfort to the patient is a common complication of TBW. These become more noticeable with time as the initial swelling due to the injury to the elbow reduces. Macko *et al* (3) in their review of 20 patients suggests that the “K” wire prominence is not necessarily due to backing out of the “K” wire.

In a study of 88 fractures of the olecranon a relationship between the results and placement of TBW or thickness of the “K” wire could not be demonstrated. Complications have been attributed to faulty technique by many authors (3,17) Macko *et al*(3) is of the opinion that wire prominence is a result of incomplete seating of the bent proximal tips of “K” wires into the olecranon.

He also found that proximal migration of the “K” wire was not confirmed in 12(80%) of the 15 elbows with prominent “K” wires. The proximal extra osseous protrusion of the “K” wire averaged 10.2mm (range 6-18mm) in these 12 elbows but only 6.8mm (range 3-11mm) in the 5 elbows “K” wires. This difference was found to be statistically significant ($p < 0.05$).

In our review we measured prominence of the “K” wire rather than migration. For cases where the anterior cortex was penetrated the mean was 10.6mm with a median of 10mm and the range was 5.5 to 14.4mm. Those without penetration had a mean of 9.9mm and a median of 9.5mm (range 6.1 to 15.4mm).

If we take Macko’s *et al* (3) significant cut off of 6.8mm, then 11 of 12 (91.6%) of the ulna penetrated wires would have significant symptoms and 19/21 (90.9%) of the non penetrating wires would have clinically significant post operative discomfort. On a more positive note he also found that complications due to the “K” wires and the TBW ultimately had no effect on the final results.

Paediatric olecranon fractures tend to heal well with excellent outcomes (13). Relatively few require surgical intervention and for those that do, metalwork is kept to a minimum with epiphyseal growth plates respected. There is a growing trend to use absorbable

materials during fixation (14,16). For TBW backing out of the “K” wire, opinion as to whether penetrating the anterior cortex reduces “K” wire backing out is divided.

Mullett *et al* (8) studied the effect of “K” wires backing out, nine in a group of 80 patients with transverse olecranon fractures with a minimum follow up of 9 months. They found that the rate of backing out as seen on X-rays was three times greater in patients who had had “K” wire passed down the long axis of the ulna rather than engaging the anterior cortex as recommended by the AO group. There were corresponding higher rates of local complications in these patients in whom 42% had to have the implant metal removed compared to 11.4% of the transcortical group. They concluded that the clinical and biomechanical data from cadaveric elbow tests support the use of transcortical placement of “K” wire in TBW of transverse olecranon fractures.

Surgeons appear to have varying styles of doing TBW of olecranon fractures. The literature reports good overall results when TBW are used however there are relatively high rate of complications. These are mostly minor causing patient’s pain and discomfort. They result in relatively high re-operation rates as the implants often have to be removed. It is postulated that standardised operation techniques for TBW would reduce complication rates such as backing out of wires, skin infections when they protrude through the skin and thus reduce unscheduled re-operation rates. The left elbow was affected 56% of the time. The mean age for males was 40 years with a median of 41 years whilst for females the mean was 62.1 years with a median of 68 years. This is two decades later than the males.

CONCLUSIONS

Over 90% of the olecranon fracture patients treated by TBW had unduly prominent “K” wires proximally. Only 30% of the TBW were done in the AO recommended method.

Most TBW cases will have minor complications which ultimately result in union of the olecranon fracture. These however result in higher re-operation rates.

Although tension band wiring is a commonly used method of olecranon fracture fixation there appears to be a trend towards greater use of plates and screws in fixation of olecranon fractures. In 2010 there were twice as many platings compared to TBW of olecranon fractures, a reversal over the past 2 years (2009 and 2008).

Although TBW do not appear to greatly affect the final outcome, they cause pain and discomfort as well as inconvenience to the patient. They also result in higher re-operation rates. TBW technique should conform closer to the recommended technique preferably with Kirschner wires penetrating the anterior ulna cortex and

especially ensuring that the proximal ends of the “K” wires are bent 180 degrees and carefully seated flush with the cortex of the proximal olecranon segment.

RECOMMENDATIONS

Although literature does not definitively indicate the superiority of standard AO olecranon fracture fixation by TBW verses variations of the same it appears that there are fewer minor complications such as the “K” wires backing out. Surgeons should be encouraged to use the standard method especially the 180 degree bend of the proximal “K” wire.

A blinded randomized control outcome based clinical study of olecranon fracture fixation would shed more light on these fractures.

ACKNOWLEDGEMENTS

To David Griffiths (Consultant Orthopaedic and Knee Surgeon) and Damien McClelland (Consultant Orthopaedic and Shoulder Surgeon), University Hospital of North Staffordshire.

REFERENCES

1. Chalidis, B.E., Sachinis, N.C., Samoladas, E.P. *et al.* Is tension wiring technique the “gold standard” for the treatment of olecranon fractures? A long term functional outcome study. *J Orthop Surg Res.* 2008; 3:9 doi:10.1186/1749-799X-3-9 Pages 1-6.
2. Morrey, C. *The elbow and its disorders.* Philadelphia: Saunders. 2000.
3. Macko, D. and Szabo, R.M. Complications of tension-band wiring of olecranon fractures. *J Bone Joint Surg Am.* 1985; 67(9): 1396-1401.
4. Muller, M.E., Allgower, M., and Willenegger, H. *Manual of internal fixation. Techniques recommended by the AO-Group.* New York: Springer. 1970.
5. Sisk, T.D. *Fractures in Campbell's Operative Orthopaedics.* St Louis: Mosby. 1980.
6. Hutchinson, Douglas T., *et al.* Cyclic loading of olecranon fracture fixation constructs. *J Bone Joint Surg.* 2003; 85(5): 831-837.
7. Nadim, A. and Willett, K. Functional outcome following internal fixation of intraarticular fractures of the distal humerus (AO type C). *Acta Orthopaedica Belgica.* 2004; 70(2): 118-122.
8. Mullett, J. H., Shannon, J, Noel, J. *et al.* K-wire position in tension band wiring of the olecranon—a comparison of two techniques. *Injury.* 2000; 31(6): 427-431.
9. Rommens, P.M., Kuchle, R., Scheider, R,U. *et al.* Olecranon fractures in adults: factors influencing outcome. *Injury.* 2004; 35(11): 1149-1157.
10. Ikeda, M., Fukushima, Y., Kobayashi, Y. *et al.* Comminuted fractures of the olecranon management by bone graft from the iliac crest and multiple tension-band wiring. *J Bone Joint Surg. (Brit).* 2001; 83(6): 805-808.
11. Bailey, C.S., MacDermid, J., Patterson, S. D., and King, G. J. *et al.* Outcome of plate fixation of olecranon fractures. *J Orthop Trauma.* 2001; 15(8): 542-548.
12. Byron, E., Nick, C.S., and Efthimios, P.S. *et al.* Is tension band wiring technique the “Gold standard” for the treatment of olecranon fractures? A long term functional outcome study. *J Orthop Surg Res.* 2008; 3:9
13. Karlsson, M.K., Hasserijs, R., Karlsson, C., *et al.* Fractures of the olecranon during growth: a 15–25-year follow-up. *J Pediat Orthop.* 2002; 11(3): 251-255.
14. Parent, S., Wedemeyer, M., Mahar, A.T. *et al.* Displaced olecranon fractures in children: a biomechanical analysis of fixation methods. *J Pediat Orthop.* 2008; 28(2): 147-151.
15. Gortzak, Y.E., Atar, D., Weisel, Y. *et al.* Pediatric olecranon fractures: open reduction and internal fixation with removable Kirschner wires and absorbable sutures. *J Pediat Orthop.* 2006; 26(1): 39-42.
16. Candal-Couto, J. J., Williams, J.R. and Sanderson, P.L. Impaired forearm rotation after tension-band-wiring fixation of olecranon fractures: evaluation of the transcortical K-wire technique. *J Orthop Trauma.* 2005; 19(7): 480-482.
17. Horne, J. G., and T. L. Tanzer. Olecranon fractures: a review of 100 cases. *J Trauma.* 1981; 21(6): 469-472.
18. Carofino, B.C., Santangelo, S. A., Kabadi M., Mazzocca A.D. *et al.* Olecranon fractures repaired with fiber wire or metal wire tension banding: a biomechanical comparison. *J Arthroscop Related Surg.* 2007; 23(9): 964-970.