

## THE COURSE OF THE RADIAL NERVE IN RELATION TO THE HUMERUS: A CADAVERIC STUDY IN A KENYAN ADULT POPULATION

V. Lusweti, MBChB, MMed (Ortho Surg), R. Oluoch, MBChB, MMed (Ortho Surg Registrar), B. R. Ayumba, MMed (Gen Surg), MMed (Ortho), Department of Orthopaedics and Rehabilitation, Moi University, A.Njoroge, MBChB, MMed (Ortho Surg), AO Trauma Fellow and M.G.Y. Elbadawi, MBChB, PhD (Clin Anatomy), Department of Human Anatomy, Moi University, P. O. Box 4606 – 30100, Eldoret, Kenya

**Correspondence to:** Dr. Victor Lusweti, Department of Orthopaedic Surgery and Rehabilitation, College of Health Sciences, School of Medicine, Moi University, P.O. Box 4606–30100, Eldoret, Kenya. Email: luswetibaraza@gmail.com

### ABSTRACT

**Background:** The radial nerve arises from the posterior cord of the brachial plexus. It descends distally to the spiral groove of the humerus. The upper and lower margins of this groove form important landmarks relative to the acromion process, medial and lateral epicondyles of the humerus.

**Objective:** To describe the course of the radial nerve in relation to the humerus in a Kenyan adult population.

**Methods:** Dissections were done on fifty-nine left sided formalin fixed adult upper extremities obtained from the Human Anatomy Laboratory of Moi University. Data was recorded and analysed using SPSS version 21.

**Results:** The average humeral length was  $314.4 \pm 21.4$ mm. The radial nerve was located  $140.8 \pm 17.2$  mm from the tip of the acromion. It exited the spiral groove  $185.1 \pm 21.7$ mm from the tip of the acromion and  $132.1 \pm 19.4$  mm from the lateral epicondyle. The midpoint of the nerve at the spiral groove to the medial epicondyle was about half the humeral length.

**Conclusions:** The radial nerve was located at the middle third of the humerus shaft. The midpoint of the nerve while in the groove relative to the medial epicondyle was about half the humeral shaft length.

**Key words:** Spiral groove of the humerus, Humerus shaft fractures, Triceps muscle

### INTRODUCTION

The radial nerve is one of the largest nerves in the arm. It forms one of the terminal branches of the posterior cord of brachial plexus. It innervates muscles of the arm as well as the forearm. The nerve has several relations with the humerus that have surgical importance. It crosses the posterior aspect of the humerus near its midpoint (1, 2).

The nerve is located at the spiral groove in the posterior compartment of the arm where it is prone to injury both in humerus diaphyseal fractures and during surgical procedures of the humerus. As the nerve leaves the posterior compartment, it pierces the lateral intermuscular septum to enter the anterior compartment in the distal third of the arm. The nerve is fixed to the septum at this level thus it may be damaged during manipulation of fractures of the mid to distal third of the shaft (3).

Radial nerve palsy associated with humeral shaft fractures is the most common nerve lesion complicating fractures of long bones occurring as a result of the fracture itself or iatrogenic injury (4). Surgeons may cause injury to the radial nerve during fixation of humeral shaft fractures. The rate of

iatrogenic nerve injury is highest in the mid to distal part of the humerus shaft relative to other parts of the humerus shaft (4). Most of these radial nerve palsies usually resolve spontaneously but about 3% will progress to permanent nerve damage. The symptoms of the nerve injury may include paresthesia on the back of the upper extremity, difficulty in supination and in extension of the elbow and wrist drop due to denervation of respective muscles (5).

We studied the relationship of the radial nerve to the acromion process in a Kenyan cadaveric population with the aim of providing guidance on the likely location of the nerve during surgical procedures of the proximal humerus.

### MATERIALS AND METHODS

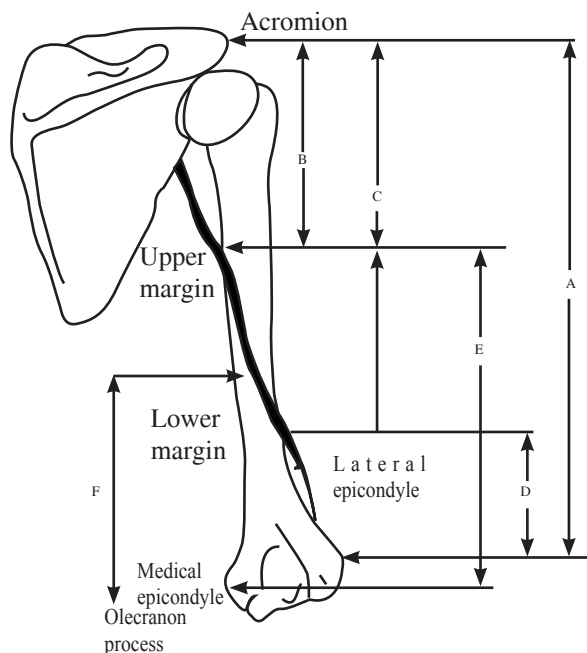
This descriptive study was carried out in the Department of Human Anatomy Laboratory, Moi University School of Medicine. Permission and clearance to conduct the study was sought and granted from Institutional Research and Ethics Committee (IREC) of Moi University. Fifty-nine left human cadaveric upper extremities prepared through scapulothoracic disarticulation and mid clavicular amputation were included in this study.

Dissection of the posterior aspect of the arm was done using the posterior approach as described by Hoppenfeld and Buckley (6). Techniques described by Guse and Ostrum *et al.* (7) were used for measuring the radial nerve distances in relation to the humerus.

All the cadavers were prepared through removal of the entire skin on the extremity. This minimized the confounding effect of varied thickness of the subcutaneous fat. The distance from the tip of acromion process to the most prominent part of the lateral epicondyle was determined by a line (A). This represented the humeral length (Figure 1).

**Figure 1**

*Illustration showing the various measurements for mapping out the radial nerve [Adapted from Guse & Ostrum *et al.*(7)]*



Blunt dissection was done to separate the long head from the lateral head of the triceps. Triceps aponeurosis was split to give better exposure for radial nerve identification. The radial nerve was identified in the spiral groove just superior to the origin of the medial head of triceps. The distances from the tip of the acromion to the upper and lower margins of the spiral groove were determined by lines (B) and (C) respectively.

The distance from the lower margin of spiral groove to the lateral epicondyle and from the upper margin of the groove to the medial epicondyle was represented by lines (D) and (E) respectively. Line (F) represented the measurement of the radial nerve at the midpoint of the spiral groove to the medial humeral epicondyle. The measurements were recorded in

millimeters. The course of the nerve was outlined and the branches in the arm recorded. Photographs of the measurements and nerve with its branches were taken.

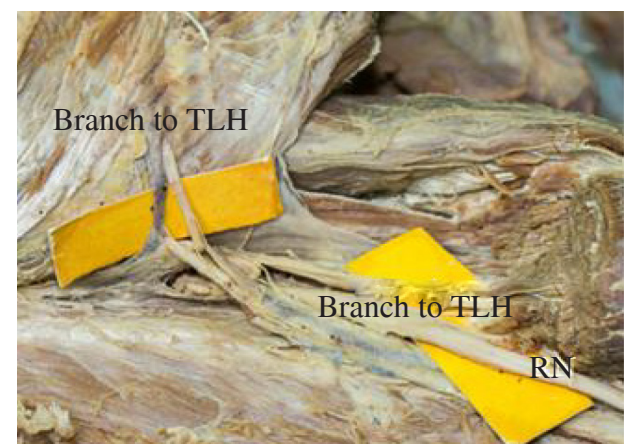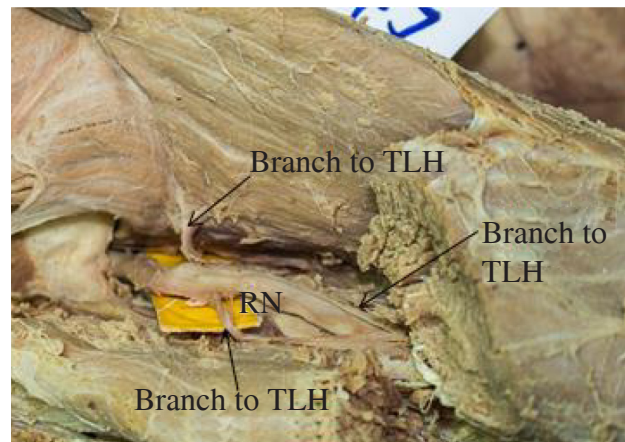
**RESULTS**

The average humeral length was  $314.4 \pm 21.4$  mm with a minimum and maximum lengths of 267.0 and 357.0 mm respectively. The radial nerve originated from the posterior cord of brachial plexus in 59 (100%) upper extremities. In all the cases the nerve was located distal to the acromion process.

The radial nerve descended anterior to the subscapularis, latissimus and teres major muscles accompanied by the profunda brachii vessels. Together they passed through the lower triangular space (below the lower border of teres major, between the long head of triceps and the humerus). Prior to entering the spiral groove, the radial nerve gave branches to the long head of triceps (Figure 2). Branches to the medial and lateral heads originated in the axilla or in the arm.

**Figure 2**

*Photographs of various branches of the radial nerve in the axilla. (RN - Radial Nerve; TLH - Long Head of Triceps; TLtH - Lateral Head of Triceps; TMH - Medial Head of Triceps)*



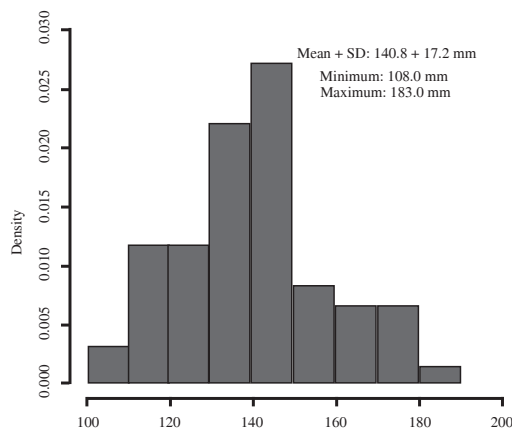
The radial nerve descended obliquely across the posterior surface of the humerus. In 7/59 cases a large branch to medial head wound around the posterior surface of the humerus along with the radial nerve.

While in the spiral groove, it gave branches to the anconeus in 57/59 cases, medial head in 25/59 cases and lateral heads in 12/59 cases. The mean  $\pm$  SD measurements from the tip of acromion process to the upper margin of spiral groove was  $140.8 \pm 17.2$ mm with a minimum and a maximum of 108.0mm and 183.0mm respectively. Majority of the measurements seem to be between 110.0mm and 150.0mm. This measurement in form of percentage of humeral length was about 45% (36-54%) (Figure 3 and 4).

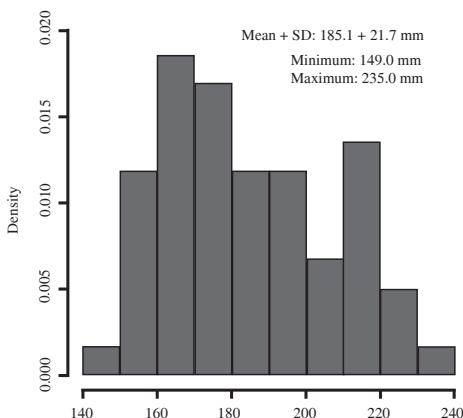
The mean  $\pm$  SD of tip of acromion process to the lower margin of spiral groove was  $185.1 \pm 21.7$ mm with a minimum and a maximum of 149.0 and 235.0mm respectively. This measurement in form of percentage of humeral length was about 59% (50 - 69%).

**Figures 3 and 4**

*Measurements from the tip of acromion process to the upper and lower margins of spiral groove*



Tip of acromion process to the upper margin of spiral groove measurements (mm)



Tip of acromion process to lower margin of spiral groove measurements (mm)

While within the spiral groove, the radial nerve measured a minimum and the maximum length of 139.0 mm and 215.0mm respectively from the upper margin of the spiral groove to the medial epicondyle. The mean  $\pm$  SD was  $178.3 \pm 16.3$ mm. This measurement in form of percentage of humeral length was about 57% (47-66%).

The radial nerve exited the spiral groove to pierce the lateral intermuscular septum to enter the anterior compartment of the arm. The distance from this lower margin of the spiral groove to the lateral epicondyle averaged  $132.1 \pm 19.4$ mm with a minimum and a maximum of 96.0mm and 171.0mm respectively. This measurement in form of percentage of humeral length was about 42% (41-52%).

The radial nerve at the midpoint of the spiral groove to the medial epicondyle measured a minimum and a maximum of 115.0mm and 195.0mm respectively relative to the medial epicondyle of humerus. The mean  $\pm$  SD was  $151.6 \pm 18.6$ mm.

The radial nerve entered the muscular groove to give branches to the brachialis, brachioradialis and extensor carpi radialis longus before terminating anterior to the lateral humeral epicondyle in 49/59 cases. In 3/59 cases the nerve gave its terminal branches proximal to the lateral epicondyle while in 7/59 cases, it terminated distal to the lateral humeral epicondyle. The nerve gave posterior interosseous nerve as it's terminal branch and continued as the superficial branch of the radial nerve.

**DISCUSSION**

The distance from the tip of the acromion process to the lateral epicondyle represented the humerus length. This length was highly variable with a wide standard deviation. This was similar to  $308 \pm 18$ mm found in Caucasians (7). The same measurement in Asian subjects had a standard deviation of 28mm indicating a more diverse population (8).

The radial nerve descended to lie posterior to the humerus. The nerve gave branches to the triceps muscles both in the axilla and in the arm. Similar branching pattern of the radial nerve to the triceps at these levels have been reported (9).

The distance from the upper margin of the musculospiral groove to the acromion process

proximally and medial epicondyle distally showed a tight distribution as evidenced by a low standard deviation. These measurements were found to be highly variable in Asian subjects (8). On the other hand a tighter distribution indicating a more consistent upper margin point in Caucasians was found (7).

Similar findings ( $176 \pm 17\text{mm}$ ) and ( $126 \pm 11\text{mm}$ ) at the levels where the nerve exited the spiral groove in relation to the acromion process and the lateral epicondyle respectively were reported. In contrary a study done in Asian subjects found  $195 \pm 36\text{mm}$  and  $104 \pm 25\text{mm}$  respectively which showed highly variable exit points of the nerve at the spiral groove (7,8). This is probably due to highly variable humeral lengths that the study by Chou *et al* (8) found.

A study done on 27 adult cadavers reported that the radial nerve entered the spiral groove  $171 \pm 16\text{mm}$  from the tip of acromion process and exited  $109 \pm 15\text{mm}$  from the lateral epicondyle (10). This is probably due to shorter arms (average of  $287\text{mm}$ ) used in this study compared to an average of  $314\text{mm}$  used in this present study.

Some studies have described anterolateral approaches for upper 1/3 humeral shaft fractures and posterior approaches for middle and distal 1/3 fractures (11,12). Other authors described anterolateral approaches for most shaft fractures and posterior approaches mainly for middle and distal 1/3 shaft fractures (6). The main danger zone during these approaches is when the nerve spirals along the posterior aspect of the humerus (7, 8). In this present study, the radial nerve was found to be located around the middle 1/3 of humerus length. This was in keeping to what other authors found (7, 8, 10).

The main trunk of the nerve was located in the spiral groove alongside a large branch to the medial head of triceps in some cases. This branch may be mistaken to be the main trunk especially during posterior approach for middle or distal third fractures.

Anterolateral approaches may be most ideal for fractures of the midshaft region of the humerus since during posterior approaches for this type of the fracture the nerve is in direct contact with the bone (11). In these cases the surgeon may have to identify, protect and slide the plate beneath the nerve. This however, could cause nerve irritation to the nerve. Furthermore

fibrosis around the soft tissues following surgery may make it difficult to identify the nerve during plate removal.

The distance from the midpoint of the nerve at the spiral groove to the medial humeral epicondyle was about half that of the humerus. This is in agreement to the study done in Caucasians (7). However different authors found that the upper margin of the nerve at the spiral groove was located midway between the acromion process and the medial epicondyle (8). This indicates that it may be safe to expose the posterior humerus with a midline incision which is close to about half of the humerus length provided that the incision is approached from below and periosteal elevators are placed medially until the midpoint is reached. An alternative to this is a longer incision (from  $8\text{cm}$  from the tip of acromion processes) that enables visualization and protection of the radial nerve during surgical procedures (6).

Some authors found consistency in the branching of the main trunk of radial nerve into its superficial branch and posterior interosseous nerves at the level of the lateral epicondyle of the humerus (13). This study however showed a slight variation where the nerve could also terminate proximal or distal to the lateral epicondyle of the humerus.

When placing external fixator pins on the lateral aspect of the humerus, an area of about  $11\text{ to }15\text{cm}$  above the tip of the lateral epicondyle which is about a third of the arm's length should be approached carefully since the radial nerve leaves the spiral groove at this location. Some authors have proposed the need to make an incision big enough to visualize bone to minimize damage to the radial nerve at this level (7). Similarly when approaching the humerus through lateral incision, the safe margin of  $11\text{-}15\text{cm}$  above the lateral epicondyle should be taken into consideration.

Different studies have reported iatrogenic radial nerve injury during Open Reduction and Plating Osteosynthesis (ORPO) Minimally Invasive Plating Osteosynthesis (MIPO) and rigid interlocking nailing of shaft of humerus. The reasons attributed to these palsies were mainly due to compression of the nerve at the lateral intermuscular septum and direct conflict with fixation plate or screws (14). These authors emphasized the importance of understanding the

anatomical location of the nerve so as to minimize iatrogenic trauma.

A minimum of six cortices each side of the fracture is recommended during fixation of humeral shaft fractures. A 6 hole 4.5 mm broad AO system dynamic compression plate is about 10.4 cm in length. Longer plates such as 7 or 8 hole plates may be indicated. The lengths are 11.9cm and 13.5cm respectively. Each of these plates may be longer than 1/3 of the humerus length indicating that the plate may be at or around the zone of the radial nerve. Careful dissection, visualization and protection of the radial nerve will allow safe placement of these dynamic compression plates (8).

Interfragmentary radial nerve compression has been reported in cases of fracture reduction without visualization of the nerve. This can occur in plating and IM nailing for midshaft fractures (15). The need to identify and protect the nerve in fixation of humeral shaft fractures cannot therefore be over emphasized.

Intramedullary nailing provides a biomechanical advantage of being a load sharing device. When done closed it may also preserve the biology around the fracture site (8). Iatrogenic nerve injury has however been reported especially during placement of the locks without considering the anatomy of the radial nerve. Dissection of the tissues around so as to visualize the bone is recommended so as to minimize the nerve injuries. A small sleeve may also be used as a tissue protector to guard against inflicting injury to the nerve. Studies have emphasized the need to identify not only the nerve but also its major branches and protect them during surgery (15). Understanding the anatomy and being aware of the anatomic variants is of paramount importance during operative fixation of such fractures.

## CONCLUSIONS

The radial nerve was located at the middle third of the humerus shaft. The midpoint of the nerve while in the spiral groove in relation to the medial epicondyle was found to be about half the humeral shaft length and the distal termination of the nerve was variable.

## RECOMMENDATIONS

This study recommends preoperative planning and mapping out of the radial nerve before it is encountered. When performing surgeries around the middle 1/3 of posterior humerus, the study recommends exposure of the radial nerve in order to protect it.

## CONFLICT OF INTEREST

The authors declare that there is no conflict of interests regarding the publication of this manuscript.

## REFERENCES

1. Hollinshead, W.H. (1982). *Anatomy for surgeons* (4th ed). Philadelphia: Lippincott Williams & Wilkins pg 145-219.
2. Williams, P.L. (1989). *Gray's anatomy* (37th ed). Edinburgh: Churchill livingstone pg 406.
3. Pollock, F.H., Drake, D., Bovill, E., *et al.* Treatment of radial neuropathy associated with fractures of the humerus. *J Bone Joint Surg Amer.* 1981; **63**(2): 239-243.
4. DeFranco, M.J., and Lawton, J.N. Radial nerve injuries associated with humeral fractures. *J Hand Surg.* 2006; **31**(4): 655-663.
5. Lim, K., Yap, C. and Ong, S. Plate osteosynthesis of the humerus shaft fracture and its association with radial nerve injury--a retrospective study in Melaka General Hospital. *Med J Malaysia.* 2001; **56**: 8-12.
6. Hoppenfeld, S. and Buckley, R. (2012). *Surgical exposures in orthopaedics: The anatomic approach* (3rd ed) Philadelphia: Lippincott Williams & Wilkins pg 74-110.
7. Guse, T.R. and Ostrum, R.F. The surgical anatomy of the radial nerve around the humerus. *Clin Orthop Related Res.* 1995; **320**(1): 149-153.
8. Chou, P.H., Shyu, J.F., Ma, H.L., *et al.* Courses of the radial nerve differ between Chinese and Caucasians. *Clin Orthop Related Res.* 2008; **466**(1): 135-138.

9. Cho, H., Lee, H.Y., Gil, Y.C., *et al.* Topographical anatomy of the radial nerve and its muscular branches related to surface landmarks. *Clin Anatomy*, 2015; **26**(7): 862-869.
10. Carlan, D., Pratt, J., Patterson, J.M., *et al.* The radial nerve in the brachium: an anatomic study in human cadavers. *J Hand Surg Amer.* 2007; **32**(8): 1177-1182.
11. Chao, T.C., Chou, W.Y., Chung, J.C., *et al.* Humeral shaft fractures treated by dynamic compression plates, Ender nails and interlocking nails. *Intern Orthop.* 2005; **29**(2): 88-91.
12. Chapman, J.R., Henley, M.B., Agel, J., *et al.* Randomized prospective study of humeral shaft fracture fixation: intramedullary nails versus plates. *J Orthop Trauma.* 2000; **14**(3): 162-166.
13. Tubbs, R.S., Salter, E.G., Wellons, J.C., *et al.* Superficial surgical landmarks for identifying the posterior interosseous nerve. *J Neurosurg.* 2006; **104**(5): 796-799.
14. Cognet, J., Fabre, T. and Durandea, A. Persistent radial palsy after humeral diaphyseal fracture: cause, treatment, and results. 30 operated cases. *Revue de Chirurgie Orthopedique et Reparatrice de l'appareil Moteur.* 2002; **88**(7): 655-662.
15. Yam, A., Tan, T.C. and Lim, B.H. Intraoperative interfragmentary radial nerve compression in a medially plated humeral shaft fracture: a case report. *J Orthop Trauma.* 2005; **19**(7): 491-493.